

# Dramatic effects of eculizumab in a child with diffuse proliferative lupus nephritis resistant to conventional therapy

Rosanna Coppo · Licia Peruzzi · Alessandro Amore · Silvana Martino ·  
Luca Vergano · Inna Lastauka · Arrigo Schieppati · Marina Noris ·  
Pier Angelo Tovo · Giuseppe Remuzzi

Received: 17 April 2014 / Revised: 28 July 2014 / Accepted: 31 July 2014  
© IPNA 2014

## Abstract

**Background** Treatment of systemic lupus erythematosus (SLE) with severe diffuse proliferative nephritis is often challenging, particularly in small children in whom a genetic conditioning is likely to play a role. The effectiveness of standard therapy based on glucocorticoid and immunosuppressive drugs is often unsatisfactory.

**Case** A 4 year-old girl, whose parents were first-grade cousins of Moroccan ancestry, developed SLE that progressed to severe renal involvement despite standard therapy. She had persistently undetectable serum C4 levels and very low C3 levels (<30 mg/dl), and extremely high anti-DNA titers

(>1:640) that remained unmodified during 2 years of follow-up. No mutations of genes encoding for complement inhibitors were detected. Despite aggressive therapy based on prednisone, plasma exchanges, and cyclosporine, the child worsened and eventually developed features of atypical hemolytic uremic syndrome (aHUS). Treatment with eculizumab provided prompt remission of vasculitis, proteinuria, and hematuria, with normalization of renal function. Two attempts to withdraw eculizumab were followed by severe relapses and rescued by reinstating treatment. The child has been treated with eculizumab for > 17 months without relevant side effects.

**Conclusion** C5 inhibition by eculizumab completely reversed clinical symptoms and laboratory renal signs of severe lupus nephritis. Blocking complement-system activation with the use of targeted drugs may be a new and exciting strategy to treat SLE patients unresponsive to conventional therapy.

**Electronic supplementary material** The online version of this article (doi:10.1007/s00467-014-2944-y) contains supplementary material, which is available to authorized users.

R. Coppo · L. Peruzzi · A. Amore · L. Vergano  
Nephrology, Dialysis and Transplantation, University Hospital Città della Salute e della Scienza di Torino, Turin, Italy

S. Martino · P. A. Tovo  
Department of Pediatrics, University of Turin, Turin, Italy

I. Lastauka  
Belarusian Medical Academy of Postgraduate Education,  
Minsk, Belarus

M. Noris · G. Remuzzi  
IRCCS - Istituto di Ricerche Farmacologiche Mario Negri Bergamo,  
Italy and Unit of Nephrology, Dialysis and Transplantation,  
A.O. Papa Giovanni XXIII, Bergamo, Italy

A. Schieppati  
Rare Diseases Unit, A.O. Papa Giovanni XXIII, Bergamo, Italy

R. Coppo (✉)  
Nephrology, Dialysis and Transplantation, Health Agency Città della Salute e della Scienza di Torino, University Hospital Regina Margherita, Turin, Italy  
e-mail: rosanna.coppo@unito.it

**Keywords** Systemic lupus erythematosus · Lupus nephritis · Treatment · Eculizumab · C5 inhibition · Atypical hemolytic uremic syndrome · Treatment-resistant SLE

## Introduction

Systemic lupus erythematosus (SLE) is a multisystem autoimmune disease characterized by a dysregulation of the immune system leading to activation of inflammatory response in target organs [1]. Multiple immune abnormalities contribute to the pathogenesis of SLE, including impaired clearance of apoptotic cells and immune complexes (ICs) and reduced thresholds of activation of B and T lymphocytes, leading to loss of self-tolerance and production of autoantibodies, which are mainly directed against ribo- and deoxyribonucleoprotein particles [2, 3]. Therapy of patients with the most severe form of SLE renal disease, diffuse proliferative glomerulonephritis,

is challenging. Conventional treatment—aimed at limiting T-cell derangement, with consequent B-cell activation and autoantibody production—is based on glucocorticoids and immunosuppressive drugs [4, 5]. Mycophenolate mofetil (MMF), a powerful inhibitor of purine synthesis, as well as new drugs specifically targeting B cells, such as rituximab and B-cell-activating factor (BLyS, belimumab), have raised interest in and hope of greater benefits and less toxicity when treating patients with SLE.

Tissue damage from SLE is mediated by deposition of pathogenetic autoantibodies and ICs, followed by activation of inflammatory pathways directed by circulating complement proteins [1, 2]. Complement factors have a bivalent complex role in SLE. Components of the classic complement pathway (C1q, C2, C4) have a protective role in facilitating the clearance of SLE-associated ICs and apoptotic bodies, as documented by the association of either C1q and C4 genetic or acquired deficiencies and SLE [2, 6]. On the other hand, activation of terminal complement components (C5–C9) promotes inflammation and tissue injury through the generation of the anaphylatoxin C5a, which stimulates neutrophil recruitment, and through formation of the lytic membrane attack complex (C5b–9) [7]. Data in favor of a role of the terminal complement pathway in the pathogenesis of lupus nephritis come from the observation that in lupus-prone New Zealand Black/New Zealand White (NZB/W) mice treated with an anti-C5 monoclonal antibody significantly improved proteinuria and renal dysfunction and prolonged animal survival [8]. In this report, we describe a 4-year-old child with lupus nephritis who failed to respond to conventional treatments and showed an exceptional benefit from the administration of anti-C5 monoclonal antibody, eculizumab.

## Case report

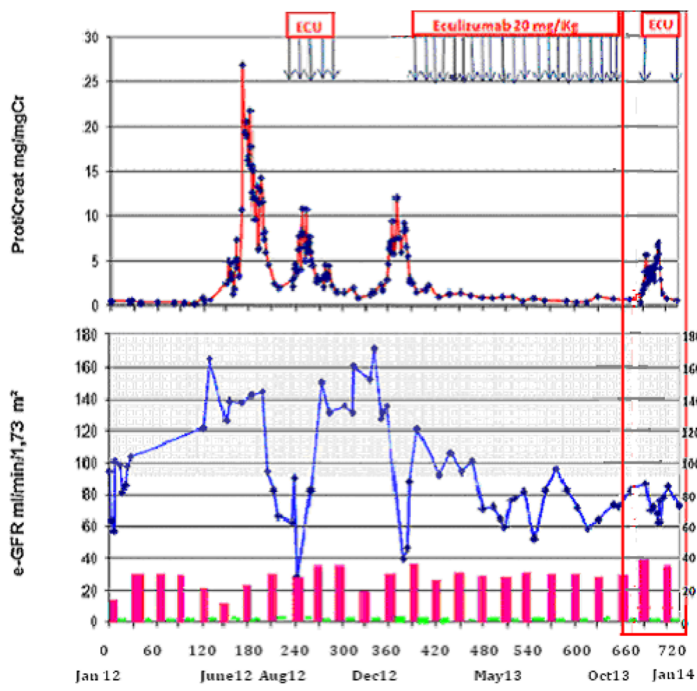
A 4-year-old girl presented with fever, weakness, and walking difficulty. Her past medical history was unremarkable. Originally from Morocco, her parents are first cousins. There was no family history of systemic diseases, and one 6-year-old brother was in good health. At presentation, on January 2012, her platelet count was 81,000/mm<sup>3</sup> and white blood cell (WBC) count 3,810/mm<sup>3</sup> (43 % neutrophils, 43 % lymphocytes). Hemoglobin (Hb) was 9.3 g/dl, with a negative Coombs test, bone marrow biopsy was normal, and blood pressure (BP) was within the normal range for sex and height. Shortly after admission, she developed palmar and plantar erythema progressing to necrotic lesions. Complement factor 3 (C3) level was 20 mg/dl, while C4 was undetectable (<4 mg/dl), indicating massive activation of the classic complement pathway. C3 and C4 were within normal ranges in both parents, with borderline values of C4 (12 mg/dl) in the father. Autoimmunity markers were positive, with anti-DNA

antibodies detected by enzyme-linked immunosorbent assay (ELISA) test > 400 UI/ml (normal values <10 UI/ml) and antinuclear factor (ANF) detected by immunofluorescence (IF) test on EP2 cell line >1:640 (normal values 1:40). Lupus anticoagulant (LAC) test, anticardiolipin antibodies (ACA), and antibodies against beta 2 glycoprotein (anti-b2GPI) were all negative. Urine analysis did not detect proteinuria or hematuria, and estimated glomerular filtration rate (eGFR) was >120 ml/min/1.73 m<sup>2</sup> (Fig. 1a, b).

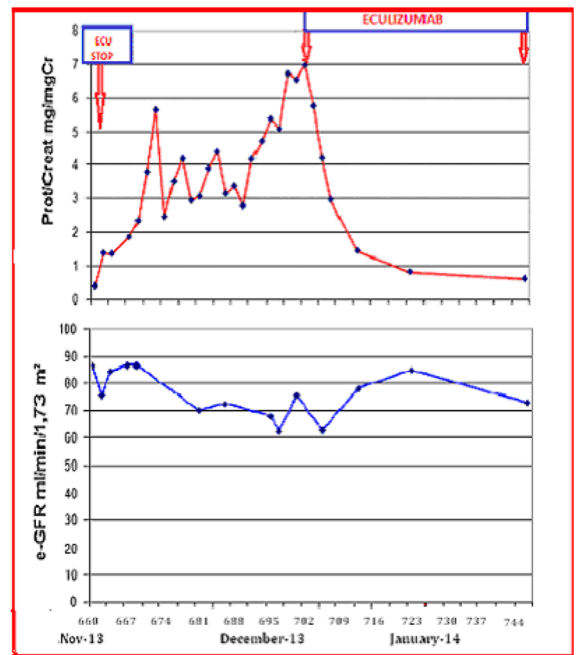
SLE without renal involvement was diagnosed [9], and treatment with glucocorticoids was started (three i.v. methylprednisolone pulses (MP) 10 mg/kg each, followed by prednisone 1 mg/kg per day). This treatment resulted in a prompt clinical improvement with disappearance of fever, weakness, myalgia and cutaneous lesions; however, laboratory findings remained unchanged. Six months later, while on prednisone treatment, the patient developed proteinuria [urinary protein/urinary creatinine (UP/UCr) 27 mg/mg] and heavy microscopic hematuria (Fig. 1a). Systemic Lupus Erythematosus Disease Activity Index of the American College of Rheumatology (SLEDAI) score [9] was 42 (Supplementary Table 1). A renal biopsy was performed in June 2012, and class IV-G diffuse proliferative lupus nephritis was diagnosed, with wire loops due to subendothelial deposits, endocapillary hypercellularity with monocytes and polymorphs, engulfment of capillary lumina, and focal fibrinoid necrosis. IF showed rich subendothelial and mesangial deposits of immunoglobulins and complement fractions [immunoglobulin (Ig)G +++, IgM +++, IgGA++, C1q ++, C3 +++, C4 +].

The girl was treated with three i.v. pulses of methylprednisolone (10 mg/kg), plasmapheresis (nine sessions), and cyclophosphamide orally (2.7 mg/kg per day), which was stopped 15 days later because of worsening of leukocytopenia (1,500/mm<sup>3</sup>). The total amount of cyclophosphamide given to the patient was 486 mg (40.5/kg body weight). Cyclosporine (5 mg/kg) was started. After 1 month of therapy, proteinuria decreased to UP/UCr 2 mg/mg and eGFR was 100 ml/min/1.73 m<sup>2</sup>; was still anemic. A peripheral-blood smear showed no schistocytes, Coombs test was negative, haptoglobin level was normal, and LDH was 1,000 U/L (Fig. 1a, b).

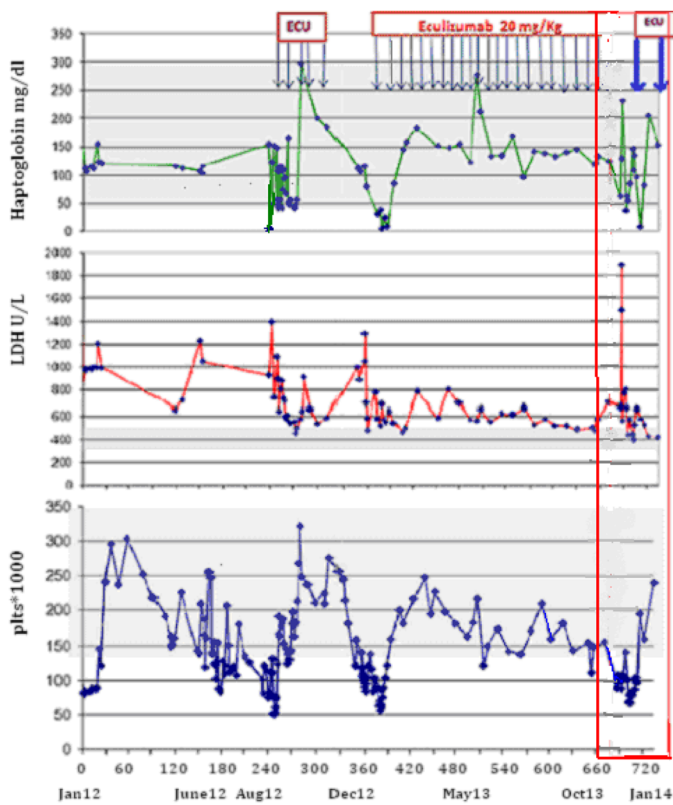
One month later, while still on prednisone (0.8 mg/kg per day) and cyclosporine (5 mg/kg per day), the patient's general condition worsened, with weakness and walking difficulties. C3 had been persistently low since the diagnosis (20–30 mg/dl), C4 was always below the level of detection (<4 mg/dl), anti-DNA and ANF were 400 UI/ml and 1:640, respectively (these values had not changed during the 8 months of treatment). MMF (20 mg/kg per day) was given for 2 weeks but withdrawn because of gastric intolerance and leukocytopenia (WBC 1,800/mm<sup>3</sup>). Over the next 2 weeks, proteinuria increased UP/UCr 8 mg/mg and eGFR decreased to 60 ml/min/1.73 m<sup>2</sup>. SLEDAI score was 42 (Supplementary Table 1). Rituximab was then given (1 g/1.73 m<sup>2</sup>) with a 10 mg/kg



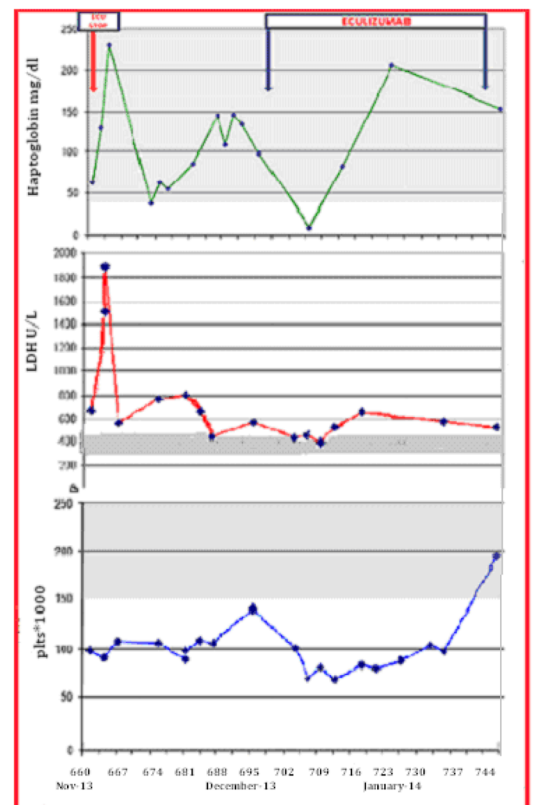
a



a.1



b



b.1

**Fig. 1** a, b Laboratory data of the child with systemic lupus erythematosus (SLE). *Prot/Creat* ratio urinary proteins and urinary creatinine (g/g); *eGFR* estimated glomerular filtration rate; *LDH* lactate dehydrogenase;

*plt's* platelets; *Ecu* eculizumab. **a1, b1** Data from November 2013 to January 2014

MP pulse. There was a short-lasting improvement in her general condition, but heavy proteinuria (6 UP/UCr) persisted. She then became hypertensive (BP 160/110 mmHg; haptoglobin was 120 mg/dl, LDH 1,000 U/ml, and Coombs test negative. A second infusion of rituximab was interrupted because of marked skin rash and hypotension. The worsening trend seemed to be uncontrolled, and at the end of August, her eGFR decreased to 28 ml/min/1.73 m<sup>2</sup>, with severe leukocytopenia (3,150 /mm<sup>3</sup>), anemia (Hb 8.5 g/dl), and abrupt decrease in haptoglobin to 20 mg/dl (Fig. 1a, b). Her general condition worsened, with fever, weakness, arthralgia, and hypertensive crisis. She was scarcely reactive and had seizures. Electroencephalography (EEG) and brain computed tomography (CT) were negative. Painful and edematous palmar and plantar purpuric lesions appeared and rapidly progressed. In few hours oliguria developed, pulmonary interstitial infiltrates were detected on chest X-rays, and oxygen saturation decreased to 70 %. A diagnosis of atypical hemolytic uremic syndrome (aHUS) was made based on thrombocytopenia (platelet count 55,000/mm<sup>3</sup>) and undetectable haptoglobin (<10 mg/dl). LAC, ACA, and anti-b2GPI antibodies were negative. Serum disintegrin and metalloprotease with thrombospondin motifs (ADAMTS)13 activity was normal; anti-ADAMTS13 inhibitory antibodies were absent. Screening for the most common genes involved in aHUS are factor H (*CFH*), factor I (*CFI*), membrane cofactor protein (*MCP*), *C3*, thrombomodulin (*THBD*), and factor B (*CFB*) was negative. The terminal complement was highly activated, as documented by very elevated plasma levels of sC5b-9 (2,130 U/ml, normal 120–300 U/ml).

On 16 September, eculizumab, an anti-C5 humanized monoclonal antibody that binds to C5 and blocks activation of the terminal complement pathway, was administered (300 mg, 20 mg/kg). The child had a prompt and impressive improvement in clinical status, with rapid disappearance of pulmonary symptoms and peripheral signs of vasculitis. Platelet count and haptoglobin returned to normal values and renal function rapidly improved (Fig. 1a, b). Clinical remission was accompanied by full normalization of plasma sC5b-9 levels (175 U/ml and 151 U/ml); total complement activity (CH50) was not performed. Eculizumab was given on alternate weeks for 2 months then stopped on 19 October 2012, since signs of active aHUS were no longer evident. Therapy with cyclosporine 5 mg/kg and prednisone 1 mg/kg was continued. Over the following weeks, there was a relapse of the disease characterized by weakness, plantar vasculitis, and laboratory signs of microangiopathy, such as thrombocytopenia and haptoglobin consumption, associated with an increase in proteinuria (up to 10 mg/mg UP/UCr) and a decrease in eGFR (40 ml/min/1.73 m<sup>2</sup>). Eculizumab was resumed at 20 mg/kg on 27 December 2012 while cyclosporine and prednisone were continued at the same doses.

A second renal biopsy was performed in January 2013. Renal lesions of lupus nephritis class IV-G were detected, with no significant changes compared with the first biopsy. Fibrinoid necrosis was still detectable, without signs of thrombotic microangiopathy. IF was absolutely unchanged from the first biopsy. On electron microscopy, no dense deposits were found. Treatment with eculizumab was continued on a bi-monthly basis, with good clinical conditions and stable remission of proteinuria; eGFR ranged between 60 and 120 ml/min/1.73 m<sup>2</sup> (Fig. 1a, b). On 27 November 2013, the patient developed retrocardiac pneumonia with moderate pleural effusion due to *Streptococcus pneumoniae*. Meropenem was introduced and eculizumab stopped. She rapidly improved, but 3 weeks later (37 days after the last administration of eculizumab), she had a second relapse, with a platelet count of 68,000/mm<sup>3</sup>, proteinuria 6.7 mg/mg UP/UCr, severe microscopic hematuria, and a decrease in eGFR to 62 ml/min/1.73 m<sup>2</sup>. Eculizumab was reintroduced and improvement once more was rapid, with normalization of renal laboratory data in 2 weeks (Fig. 1a1, b1). Therefore, i.v. eculizumab at 20 mg/kg on alternate weeks was continued over the following 7 months, along with tacrolimus (trough levels 4–5 ng/ml) and prednisone 0.8 mg/day. The child is enjoying stable remission, with undetectable proteinuria and hematuria, and with eGFR >120 ml/min/1.73 m<sup>2</sup>. Her general condition is very good.

## Discussion

We report a case of a child with SLE and persistently undetectable levels of C4 who failed to show benefits from prolonged glucocorticoid treatment in association with various immunosuppressive agents. Undetectable C4 levels might be suggestive of a congenital defect, supported in this case also by the fact that the parents are first cousins and the father has borderline values of C4 levels, though we could not perform this analysis. Genetic deficiency of early components of the classic pathway, mainly C1q or C4, is a rare condition affecting < 1 % of SLE cases [3, 6]. Lack of early components of the classic pathway limits physiological clearance of apoptotic bodies, increasing the amount of circulating autoantigens that favors autoantibody production and breakdown of immune tolerance [2]. However, our patient also had persistently low serum C3 levels, whereas individuals with congenital C4 deficiency usually have normal C3 levels [6]. Rather, the concomitance of low C3 and C4, accompanied by elevated levels of sC5b-9, indicated that in our patient, there was a continuous high degree of classic complement pathway activation leading to consumption of early complement components. Low C3 levels are common in SLE as a result of classic pathway activation by autoantibodies and immune-complex formation, which very likely occurred in the patient here presented, who had extraordinarily high levels of anti-

double-stranded DNA antibodies that were unaffected by any kind of treatment.

Of interest, the girl eventually developed hematological symptoms of aHUS, a form of thrombotic microangiopathy associated with hyperactivation of the alternative complement pathway secondary to genetic defects of regulatory proteins or to gain-of-function mutations in genes encoding the two components of the C3 convertase complex, C3, and factor B [10]. The alternative complement pathway, through the formation of the C3 convertase complex, amplifies C3 activation and consumption triggered by the classic pathway and has been implicated in the pathogenesis of lupus nephritis [2, 6]. Indeed administration of selective inhibitors of the alternative pathway led to a significant amelioration of renal disease, reduction of dsDNA autoantibody levels, and increased survival in MRL lymphoproliferation strain (MLR/lpr) and NZB/W lupus-prone mice [11]. Thus, we hypothesized that the patient had a genetic defect leading to dysregulation of the alternative complement pathway and predisposing both to lupus and aHUS. Genetic screening for aHUS-associated complement genes was negative. C4 and C3 levels, anti-DNA antibodies, and ANF, were well outside normal ranges and never correlated with the patient's clinical condition or renal function. On the contrary, clinical response to treatment when achieved was evident in general well being, as well as in normal values of eGFR and proteinuria, and normal urinalysis.

In this patient, applying guidelines for treating lupus nephritis either could not be followed or was ineffective. Cyclophosphamide and MMF, which are considered the optimal treatment modalities for active lupus nephritis [4, 5], were tried and withdrawn due to leukopenia. Rituximab was also used, the first time without apparent benefit, and the second infusion was stopped because of a severe intolerance reaction. Even though supported by a limited number of trials, calcineurin inhibitors (CNI) are considered noninferior drugs in treating lupus nephritis [5]. However, our patient failed to show a persistent benefit from CNI with prednisone. Eventually, she developed life-threatening microangiopathic hemolytic anemia, with neural sensorial deterioration and signs of pulmonary interstitial involvement. The child was severely hypertensive and under treatment with CNI, two potential triggers of aHUS. LAC, due to antibodies against phospholipids, are associated with cerebral or renal vein thrombosis or with renal microangiopathic lesions [12], and an immune type of thrombocytopenia has been observed in a small percentage of cases due to reactions between antibodies and platelet-membrane-associated phospholipids. However, the child never had prolonged activated partial thromboplastin time (APTT), no ACA or anti-b2GPI antibodies, and no microangiopathic lesions detected in either of the two renal biopsies performed. In SLE patients, microangiopathic hemolytic anemia and renal thrombotic microangiopathy are reportedly associated with autoantibodies against ADAMTS13, the

plasma metalloprotease that cleaves von Willebrand multimers soon after their secretion from endothelial cells and platelets. No antibodies against ADAMTS13 were detected in our child.

The patient's critical condition induced us to try a rescue therapy with eculizumab aimed at limiting complement activation, which was held responsible for the rapidly worsening thrombotic microangiopathy. Eculizumab is a humanized monoclonal antibody with high-affinity binding to C5, hence blocking the generation of C5–9 complex [13]. This drug has been approved for paroxysmal nocturnal hemoglobinuria and aHUS, mostly due to genetic defects of complement regulatory genes [14, 15]. Eculizumab had a rapid effect on aHUS-related clinical and laboratory signs and we observed also complete remission of lupus nephritis, with reversal to normal values of proteinuria and eGFR. After the first administration of eculizumab to our patient, clinical and laboratory improvements were extraordinary, but the child had received other medications over the previous weeks. However, attempts to stop eculizumab were followed by relapses of clinical symptoms and signs of kidney damage, and reintroduction of the drug was rapidly followed by impressive improvement in systemic and renal clinical signs. This was observed twice even though we observed no change in renal histology or immunological markers of SLE.

We conclude that in this child with SLE unresponsive to standard treatment, eculizumab was very effective in controlling clinical features of aHUS as well as signs of renal damage over a follow-up of 17 months<sup>1</sup>. This is an exceptional case in which a genetic background may have played a pivotal role in conditioning clinical and laboratory features, perhaps also modifying therapeutic effects of the drug. However, inhibition of complement activation by specific drugs may be a new therapeutic option for treating unresponsive cases of SLE, which needs further confirmation.

## References

1. Maciej L, Hans-Joachim A (2013) The Pathogenesis of Lupus Nephritis. *J Am Soc Nephrol* 24:1357–1366
2. Elkon KB, Santer DM (2012) Complement, interferon and lupus. *Curr Opin Immunol* 24:665–670
3. Belot A, Cimaz R (2012) Monogenic forms of systemic lupus erythematosus: new insights into SLE pathogenesis. *Pediatr Rheumatol Online J* 10:21
4. KDIGO (2012) KDIGO Clinical Practice Guideline for Glomerulonephritis. *Kidney Int* 2(Suppl 2):139–224
5. Bertsias GK, Tektonidou M, Amoura Z, Aringer M, Bajema I, Berden JH, Boletis J, Cervera R, Dörner T, Doria A, Ferrario F, Floege J, Houssiau FA, Ioannidis JP, Isenberg DA, Kallenberg CG,

<sup>1</sup> Note. After manuscript submission the subsequent 7 months follow-up was uneventful.

- Lightstone L, Marks SD, Martini A, Moroni G, Neumann I, Praga M, Schneider M, Starra A, Tesar V, Vasconcelos C, van Vollenhoven RF, Zakharova H, Haubitz M, Gordon C, Jayne D, Boumpas DT, European League Against Rheumatism and European Renal Association-European Dialysis and Transplant Association (2012) Joint European League Against Rheumatism and European Renal Association-European Dialysis and Transplant Association (EULAR/ERA-EDTA) recommendations for the management of adult and paediatric lupus nephritis. *Ann Rheum Dis* 71:1771–1782
6. Braun-Moscovici Y, Butbul-Aviel Y, Guralnik L, Toledano K, Markovits D, Rozin A, Nahir MA, Balbir-Gurman A (2013) Rituximab: rescue therapy in life-threatening complications or refractory autoimmune diseases: a single center experience. *Rheumatol Int* 33:1495–1504
7. Barilla-Labarca ML, Toder K, Furie R (2013) Targeting the complement system in systemic lupus erythematosus and other diseases. *Clin Immunol* 148:313–321
8. Wang Y, Hu Q, Madri JA, Rollins SA, Chodera A, Matis LA (1996) Amelioration of lupus-like autoimmune disease in NZB/WF1 mice after treatment with a blocking monoclonal antibody specific for complement component C5. *Proc Natl Acad Sci U S A* 93:8563–8568
9. Tan EM, Cohen AS, Fries JF, Masi AT, McShane DJ, Rothfield NF, Schaller JG, Talal N, Winchester RJ (1982) The 1982 revised criteria for the classification of systemic lupus erythematosus. *Arthritis Rheum* 25:1271–1277
10. Noris M, Remuzzi G (2009) Atypical hemolytic-uremic syndrome. *N Engl J Med* 361:1676–1687
11. Sekine H, Kinser TT, Qiao F, Martinez E, Paulling E, Ruiz P, Gilkeson GS, Tomlinson S (2011) The benefit of targeted and selective inhibition of the alternative complement pathway for modulating autoimmunity and renal disease in MRL/lpr mice. *Arthritis Rheum* 63:1076–1085
12. Yu F, Tan Y, Zhao MH (2010) Lupus nephritis combined with renal injury due to thrombotic thrombocytopenic purpura-hemolytic uremic syndrome. *Nephrol Dial Transplant* 25:145–152
13. Tschumi S, Gugger M, Bucher BS, Riedl M, Simonetti GD (2011) Eculizumab in atypical hemolytic uremic syndrome: long-term clinical course and histological findings. *Pediatr Nephrol* 26:2085–2088
14. Brodsky RA (2009) How I treat paroxysmal nocturnal hemoglobinuria. *Blood* 113:6522–6527
15. Ariceta G, Arrizabalaga B, Aguirre M, Morteuel E, Lopez-Trascasa M (2012) Eculizumab in the treatment of atypical hemolytic uremic syndrome in infants. *Am J Kidney Dis* 59:707–710