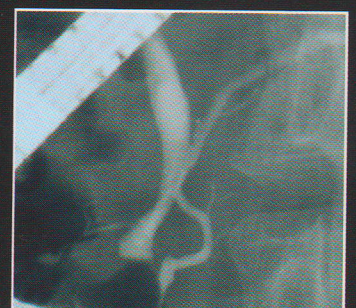
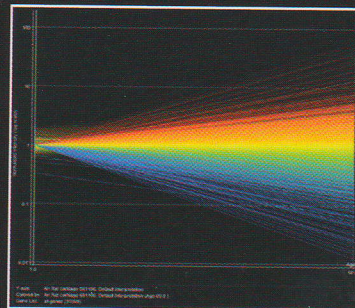
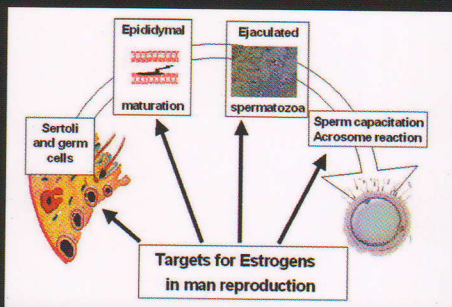
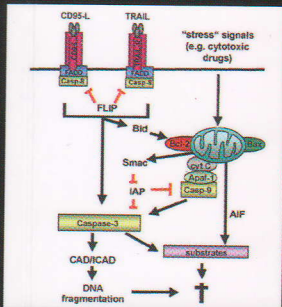




© Medical University
of Białystok

ISSN 1896 - 1126

Advances *in* Medical Sciences



Volume 53(2)
2008

www.advms.pl

Treatment of insulin dependent diabetes mellitus with intravascular transplantation of pancreatic islet cells without immunosuppressive therapy

Prochorov AV^{1*}, Tretjak SI¹, Goranov VA², Glinnik AA¹, Goltsev MV³

¹ 2nd Department of Surgery, Belarusian State Medical University, Minsk, Belarus
² Central Scientific and Research Laboratory, Belarusian State Medical University, Minsk, Belarus
³ Department of Medical and Biological Physics, Belarusian State Medical University, Minsk, Belarus

* CORRESPONDING AUTHOR:

2nd Department of Surgery,
Belarusian State Medical University,
Dzerzhynsky ave 83,
220116 Minsk, Belarus,
telephone: +375172340443; fax: +375172726197
e-mail: prochorov@tut.by (Alexander Prochorov)

Received 23.05.2008
Accepted 07.10.2008
Advances in Medical Sciences
Vol. 53(2) • 2008 • pp 240-244
DOI: 10.2478/v10039-008-0045-5
© Medical University of Białystok, Poland

ABSTRACT

Purpose: To evaluate intravascular xenotransplantation of macroencapsulated pancreatic islet cells in the process of the treatment of diabetes mellitus type 1 without immunosuppressive therapy.

Material and methods: Xenogenic intravascular transplantation was performed in 19 patients with diabetes mellitus (type 1) having high insulin demand and frequent hypo- and hyperglycemic comas without immunosuppressive therapy. The culture was obtained from 3rd trimester rabbit fetuses. Cell culture suspension was encapsulated into microporous macrocapsule made of nylon and grafted into the deep femoral artery or the forearm cubital vein after performing arteriovenous anastomosis.

Results: For 2 years after transplantation, positive results were observed in 14 recipients (73.7%). The total decrease of insulin demand was 60-65%, and hypo- and hyperglycemic comas disappeared completely, while C-peptide and immunoreactive insulin levels significantly increased, reversely correlating with the fructosamin level, as a protein glycation marker.

Conclusions: Xenotransplantation of pancreatic islet cells is a beneficial alternative to allotransplantation, which allows to overcome allogenic cell deficit. Macroencapsulation of islet cells with their subsequent grafting into the vascular lumen creates double immune isolation and allows overcoming acute and chronic graft rejection without immunosuppressive therapy. It considerably decreases insulin demand, compensates hypo- and hyperglycemic conditions, makes the course of diabetes stable, and improves the quality of patients' life.

Key words: insulin dependent diabetes, xenotransplantation, macroencapsulation, islet cells

ABBREVIATIONS

DM type 1 - diabetes mellitus type 1
IRI - immunoreactive insulin
APF - arteria profunda femoris
FA - serum fructosamin
AVA - arteriovenous anastomosis

INTRODUCTION

Currently, pancreatic islet cell transplantation is considered to be the most appropriate and promising method in treating diabetes mellitus type 1 (DM type 1). But despite different

methodological approaches to transplantation, grafting results are not quite satisfactory, mainly because of immune islet destruction and graft rejection. Using the Edmonton protocol of allogenic islet transplantation makes it possible to obtain insulin independence within a year in 44% of recipients, partial functioning of the grafted islets in 28%; complete death of the graft is observed in 28% of recipients when using immunosuppressive therapy and islet regrafting [1]. Experimental research showed the possibility to prevent rejection by immune isolation of islet cells using micro- or macroencapsulation, but fibrosis development around capsules resulted in poor cell nourishment, function and death [2-5].

The use of immune favorable areas of islet location seems to be quite attractive in cell transplantation [6]. This makes it

possible to do without immunosuppressive therapy, and use not only allogenic but xenogenic sources of insulin producing tissue. Previous experimental studies, investigating various tissue survival in blood circulation, showed that tissues with diffuse nourishment may survive for a long time without rejection [7,8]. This made it possible to realize that blood circulation, as well as frontal eye division, brain, and testicles are immune favorable areas, where neither cellular nor humoral recipient immunity acts [9]. The experiments we carried out on macroencapsulated rabbit islet cell transplantation into the aorta lumen of dogs with alloxan-induced diabetes mellitus showed long term antidiabetic effects of xenotransplantation in mammals, which resulted in complete insulin independence for 3 years without immunosuppressive therapy. A bioartificial pancreas with a structure similar to pancreatic Langerhans islet appeared to be formed in the vascular lumen. Morphological studies showed no inflammation and T-lymphocyte infiltration in the capsule [10,11]. Accounting for all this, the objective of the study was to evaluate effectiveness of intravascular xenogenic transplantation of macroencapsulated islet cells while treating DM type 1 patients without immunosuppressive therapy.

MATERIALS AND METHODS

The experimental and clinical application of xenogenic transplantation of pancreatic islets in the vascular channel is regulated by a resolution of the Belarussian State Medical University Ethical Committee and order of the Ministry of Public Health Services of the Republic of Belarus #36 from 19.02.2001 "About clinical application of a method of transplantation of islets into patients with diabetes mellitus". For transplantation, we used fetal rabbit (III trimester pregnancy) pancreatic islet cells. Korsgren *et al.* [12] and Blumkin *et al.* [13] methods were used to obtain and cultivate islet cells followed by microbiological, virusological and tumorplastic graft testing. For one transplantation, there were from 9 to 12 rabbit fetuses used. Using rabbit islets is based on the resemblance of the rabbit insulin molecule and human insulin which differ in only 2 amino acids [14]. Islet cell functional activity was defined by light microscopy using an inverted microscope, selective coloring of insulin producing cells with ditizone, FITS marked insulin antibodies, defining immunoreactive insulin (IRI) (Rio-INS-PG-1251, IBOCh, Belarus). Before transplantation, the average insulin concentration in the culture, after cell stimulation with 5 mM glucose for 24 hours, was not less than 1000 nmol/L.

To microencapsulate xenogenic islet cells, a nylon microporous macrocapsule (pore diameter 1-2 μ) was used [15]. The macrocapsule was cylinder-shaped 30-40 mm in length and 3-4 mm in diameter. The macrocapsule provided bilateral insulin, glucose and trophogen diffusion, simultaneously preventing islet cell contact with the recipient's T-cells

Figure 1. Diagram of implantation of macrocapsule into the arteria profunda femoris.

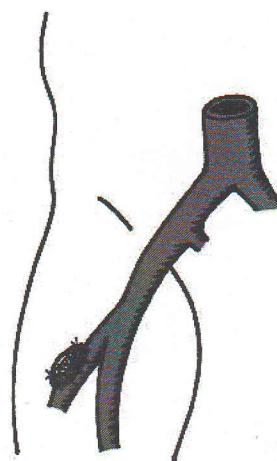
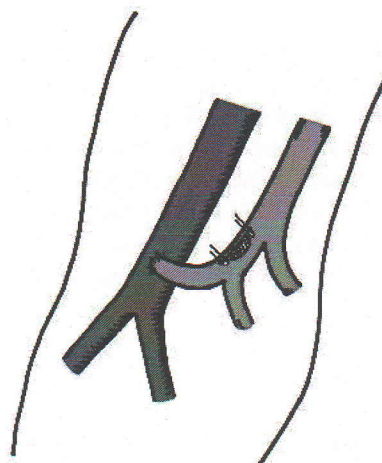


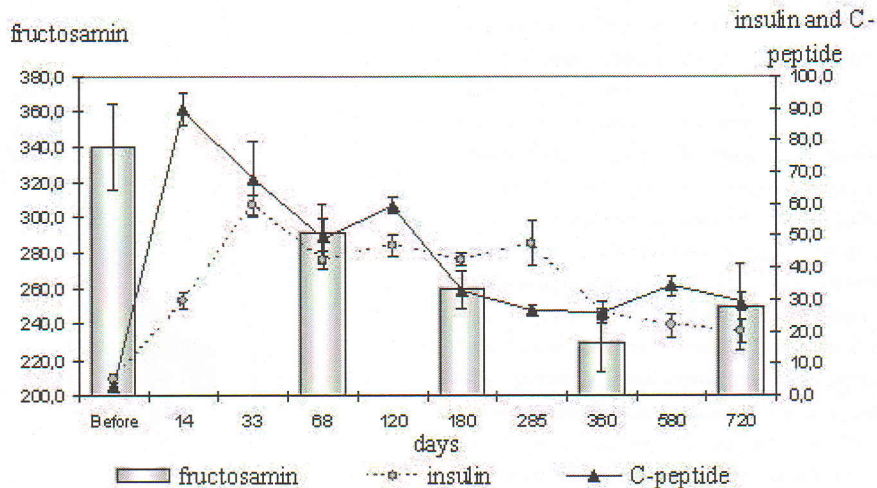
Figure 2. Diagram of implantation of macrocapsule into the venous fragment of arteriovenous anastomosis on the forearm.



and thrombocytes. The average islet cell number for each macroencapsulation and transplantation was > 6000 IEQs/kg. Intravascular islet cell xenotransplantation was recommended for patients having DM type 1, labile diabetes course with frequent hypo- and hyperglycemic conditions, exogenic insulin progressive resistance, high insulin demand (>40 U/day), prolonged disease (>5 years), progressive chronic diabetes complications (retinopathy, nephropathy, angiopathy), pancreatogenic diabetes mellitus with high insulin demand.

We performed 19 xenogenic islet cell transplantations in hospital to diabetes mellitus (type 1) patients (7 women and 12 men), their age ranging from 23 to 53. Their insulin demand ranged from 42 to 100 U/day. In 3 patients, diabetes mellitus resulted from previous total pancreonecrosis. Islet cell macrocapsule was transplanted into arteria profunda femoris (APF) using autovenous angioplastics (*Fig. 1*) or into the forearm cubital vein with arteriovenous anastomosis (AVA) formation (*Fig. 2*).

Figure 3. Level of immunoreactive insulin (mcU/L), fructosamin (mcmol/L) and C-peptide (nmol/L) in recipients (n=8) after transplantation.



Every patient gave informed consent. For 5 days after surgery, all patients were administered standard antithrombotic therapy (reopoliglucin 400 ml intravenously, pentoxiphillin 400 ml intravenously, fraxiparin 2500 IU subcutaneously twice a day). Before and after surgery, xenotransplantation effectiveness control included observations, defining 24-hour glycemia profile and insulin demand, serum C-peptide (C-peptid Irma, Immunotech, Checkia), immunoreactive insulin (IRI) (Rio-INS-PG-1251, IBOCh, Belarus) and serum fructosamin (FA) (Fructosamin kit, Roche Diagnostics, Poland) as a better liability index of proteins glycation.

RESULTS

During the first 24 hours after surgery, all patients developed insulin independence, and blood glucose levels became normal. During the next days, considerable rippling of glycemia with increasing insulin demand up to 42.6 ± 0.45 U/day was registered. 1-1.5 months after transplantation, the diabetes course became stable, hypo- and hyperglycemic conditions were completely absent, insulin demand decreased to 28.6 ± 0.55 U/day, glycemia became normal with supportive insulin therapy. A total decrease of insulin demand was 60-65%, being stable for 2 years.

The C-peptide serum level before islet transplantation was 2.9 ± 1.4 nM, which showed pancreatic β -cell complete malfunctioning. By the 14th day after surgery, it increased up to 89.0 ± 5.2 nM ($P < 0.05$), then it gradually decreased; and by the 6th month after transplantation, it was 33.0 ± 2.1 nM and later 29.3 ± 2.7 nM ($P < 0.01$ compared to the pre-surgery period). The C-peptide level increase directly correlated to the insulin demand decrease and a significant IRI level increase, the correlation index being 0.578. By the 14th day after surgery, the IRI increase was 29.5 ± 2.39 mcU/L (before surgery 4.87 ± 1.87 mcU/L, $P < 0.05$); then, its gradual decrease

up to 20.03 ± 3.74 mcU/L ($P < 0.05$) was observed (Fig. 3). This level was maintained for 2 years after transplantation. Some time later, a considerable decrease of serum FA level, being a protein glycation marker, was registered; it reversely correlated with C-peptide and IRI levels. By the 6th month after transplantation, serum FA level decreased down to 260.0 ± 11.0 mcM (before surgery 340.0 ± 24.0 mcM, $P < 0.05$); and by the end of the 2nd year, it was 250.0 ± 24 mcM ($P < 0.05$ compared to the pre-surgery value).

Determining lymphocytes CD3, CD4, CD25, CD95 markers after transplantation during a period of 3 days to 6 months did not reveal reliable changes of these indices, which confirmed that T-cell immunity to grafting was absent.

Two weeks, 1, 6, 12 and 18 months after surgery, all patients underwent ultrasonographic and dopplergraphic vascular examinations (HDI 5000, Philips) of the transplantation site to exclude thrombosis and to evaluate blood flow. Neither vascular lumen narrowing nor thrombosis was registered. The doppler examination showed that peak linear blood flow velocity in the general femoral artery was 1.37 ± 0.29 m/sec; in the deep femoral artery in the area of capsule implantation, it was 1.7 ± 1.1 m/sec. When implantation into the venous division of AVB blood flow was performed, linear velocity was consistent with blood flow velocity in the portal vein.

We didn't find any complications connected with the transplantation during the whole period of investigation. There were two complications of a purely surgical origin noted – lymphoreia in the area of a wound in the hip and a formation of a false aneurism arteria profunda femoris, which required capsule removal.

DISCUSSION

While evaluating xenotransplantation results, we used the result scale of the Edmonton protocol. Within 2 years, positive results of intravascular xenogenic islet cell transplantation were registered in 14 (73.7%) out of 19 patients. The positive result of xenotransplantation is insulin decrease by 50 or more percent. The total decrease of insulin demand was 60-65%. After transplantation no patient developed a hypo- or hyperglycemic coma, which significantly improved the quality of their lives. Satisfactory results were registered in 2 patients. The total decrease of insulin demand was no more than 10%. Three patients returned to previous insulin doses within a year.

The most favorable effect of intravascular transplantation was observed in 3 DM 1 type patients, who previously had suffered pancreonecrosis. Glycemia rippling in the early post-surgery period was insignificant and easily corrected by simple insulin injections. Two weeks after transplantation, the insulin dependence of these patients decreased by 80-85% and was 17.0 ± 2.48 U/day with a stable normal glycemia. A favorable transplantation effect in these patients is likely to result from the non-immune diabetes nature. Unfortunately, the absence of a full euglycemic transplantation effect against the background of a rather high serum C-peptide level and IRI remains unclear. Examination of the 2 patients whose insulin demand increased and was equal to the pre-surgery level a year after transplantation showed that for 2 years they had rather high C-peptide and IRI levels, which testified to maintenance of grafted islet cells function.

One of the probable causes of incomplete transplantation antidiabetic effect may be a death of a certain islet cell pool in the early post-transplantation period because of no vascularization and cell nourishment. A number of experiments showed that no graft revascularization during the first several weeks after transplantation resulted in apoptosis and islet death [16]. Our experiments also showed that during the first weeks after transplantation, up to 40% of islet cells died, as there was no adequate vascularization. Neoangiogenesis, which developed in macrocapsule 2 weeks after transplantation, allowed other islet cells to remain vital, their functioning in case of good vascularization is maintained for 3 years. It's possible that full insulin independence was not achieved due to a certain insulin resistance to rabbit insulin.

A comparative analysis of the transplantation methods used showed that they are all rather effective. But the most preferable method seems to be islet cell transplantation into the forearm cubital vein with AVA formation. This method is less traumatic and more physiological, making it possible for islet cells to contact both arterial and venous blood and get into systemic venous blood flow. These patients showed a faster and larger decrease of insulin demand and euglycemia was maintained for a long time while exogenic insulin therapy didn't exceed 19.0 ± 2.48 U/day.

In the post-surgery period, complications were revealed in 2 patients. One patient who was operated on against the background of renal failure, showed lymphorrhea of the upper femoral third for 30 days. In the second case, the surgical wound was infected, autovenous angioplastics failed and false APF aneurysm developed. Due to this, the capsule had to be removed and APF needed dressing. An insulin demand, which decreased from 52 to 24 U/day after transplantation, increased to previous levels after graft removal. This fact also clinically confirmed intravascular graft functioning.

While using intraportal transplantation, cells are diffusely distributed around hepatic parenchyma by blood flow and precipitate in perisinusoidal spaces [17,18]. Islet cells may easily contact T-cells, which results in their gradual rejection 6-12 months after transplantation, despite immunosuppressive therapy. In pancreatic Langerhans islets there are cells of a different chemotype (α , β , λ - cells), which presupposes their direct intercellular interaction. This cellular interaction is broken in case of intraportal grafting, and may have impact on their function and survival. Islet macroencapsulation makes it possible to preserve this intercellular interaction. Neoangiogenesis development in the capsule, graft revascularization and trophics confirm that in the vascular lumen a bioartificial pancreas, with all its characteristics such as structure, blood supply and function, was created.

CONCLUSIONS

Xenotransplantation of pancreatic islet cells is a favorable alternative to allotransplantation, which makes it possible to solve the problem of allogenic cell deficit and avoid many ethical problems. Implantation of macroencapsulated islet cells into vascular lumen, which is an immune favorable area, creates double immune isolation, which allows to prevent acute and chronic graft rejection without immunosuppressive therapy. Bioartificial pancreas formation in blood flow makes it possible to considerably decrease the recipient's insulin dependence and insulin demand, make the diabetes course stable, compensate its acute complications and improve the quality of the patients' life. Islet cell encapsulation and capsule grafting into blood flow makes it possible to perform other endocrine tissue grafting, for example thyrocytes and parathyrocytes in case of thyroid and parathyroid pathology.

ACKNOWLEDGEMENTS

The work was supported within the frameworks of two innovation designs: "Mining for a method of surgical treatment of diabetes mellitus by a transplantation of islets in vascular channel (design 6/00 – I from 07.04.2000)", "To elaborate a similar invasive method of a xenotransplantation of pancreatic islets in treatment of diabetes mellitus (2/02 – I

from 24.04.2002)" and a support of the Fund of Basic Research from the Republic of Belarus (design B 03-153).

REFERENCES

1. Shapiro AM, Ricordi C, Hering BJ, Auchincloss H, Lindblad R, Robertson RP, Secchi A, Brendel MD, Berney T, Brennan DC, Cagliero E, Alejandro R, Ryan EA, DiMercurio B, Morel P, Polonsky KS, Reems JA, Bretzel RG, Bertuzzi F, Froud T, Kandaswamy R, Sutherland DE, Eisenbarth G, Segal M, Preiksaitis J, Korbitt GS, Barton FB, Viviano L, Seyfert-Margolis V, Bluestone J, Lakey JR. International trial of the Edmonton protocol for islet transplantation. *N Engl J Med*. 2006 Sep 28;355(13):1318-30.
2. Kulseng B, Thu B, Espevik T, Skjåk-Braek G. Alginate polylysine microcapsules as immune barrier: permeability of cytokines and immunoglobulins over the capsule membrane. *Cell Transplant*. 1997 Jul-Aug;6(4):387-94.
3. Prevost P, Flori S, Collier C, Muscat E, Rolland E. Application of AN69 hydrogel to islet encapsulation. Evaluation in streptozotocin-induced diabetic rat model. *Ann N Y Acad Sci*. 1997 Dec 31;831:344-9.
4. de Vos P, Hamel AF, Tatarkiewicz K. Considerations for successful transplantation of encapsulated pancreatic islets. *Diabetologia*. 2002 Feb;45(2):159-73.
5. Brunetti P, Basta G, Faloerni A, Calcinaro F, Pietropaolo M, Calafiore R. Immunoprotection of pancreatic islet grafts within artificial microcapsules. *Int J Artif Organs*. 1991 Dec;14(12):789-91.
6. Barker CF, Billingham RE. Immunologically privileged sites. *Adv Immunol*. 1977;25:1-54.
7. Baue AE, Donawick WJ, Blakemore WS. The immunologic response to heterotopic alloveral aortic valve transplants in presensitized and nonsensitized recipients. *J Thorac Cardiovasc Surg*. 1968 Dec;56(6):775-89.
8. Carpentier A, Lemaigre G, Robert L, Carpentier S, Dubost C. Biological factors affecting long-term results of valvular heterografts. *J Thorac Cardiovasc Surg*. 1969 Oct;58(4):467-83.
9. Shott AV, Tretjak SI, Leontyuk AS Unusual reaction to heterologous tissues. *MSMI*. 1992;Minsk.283 pp (in Rus).
10. Prochorov AV, Tretjak SI, Roudenok VV, Goranov VA. Long-term normalization of diabetes mellitus after xenotransplantation of fetal pancreatic islet cells into the blood stream without immunosuppressive therapy. *Transplant Proc*. 2004 Nov;36(9):2855-6.
11. Prochorov AV, Roudenok VV, Goranov VA. Histological study of macroencapsulation of pancreatic islet cells after transplantation into the bloodstream. *Transplant Proc*. 2005 Dec;37(10):4446-8.
12. Korsgren O, Jansson L, Eizirik D, Andersson A. Functional and morphological differentiation of fetal porcine islet-like cell clusters after transplantation into nude mice. *Diabetologia*. 1991 Jun;34(6):379-86.
13. Blumkin VN, Babikov ZA, Kauricheva NI, Skaletsky NN, Petrova IA. Methods to obtain pancreatic islet cell culture from dead human and some mammal fetuses. *Methodological recommendations 1985; Moscow (in Rus)*.
14. *Physiology of the endocrine system*. L.: Nauka. 1979; 680 pages
15. Tretjak SI, Prokhorov AV, Goranov VA, Mokhort TV. The use of polyamide for macro capsules for β -cells transplantation. *Diabetologia*. 2002;45(Suppl 2):425.
16. Carlsson PO, Palm F, Mattsson G. Low revascularization of experimentally transplanted human pancreatic islets. *J Clin Endocrinol Metab*. 2002 Dec;87(12):5418-23.
17. Hirshberg B, Mog S, Patterson N, Leconte J, Harlan DM. Histopathological study of intrahepatic islets transplanted in the nonhuman primate model using edmonton protocol immunosuppression. *J Clin Endocrinol Metab*. 2002 Dec;87(12):5424-9.
18. Mattsson G, Jansson L, Carlsson PO. Decreased vascular density in mouse pancreatic islets after transplantation. *Diabetes*. 2002 May;51(5):1362-6.