


MINISTRY OF HEALTH OF THE REPUBLIC OF BELARUS

EDUCATIONAL INSTITUTION
BELARUSIAN STATE MEDICAL UNIVERSITY

APPROVED by

Associate professor Ya.I.Timchuk
Head of the Dpt., Ph.D.



**METHODOLOGY TEXTS for Practical Training of Students
in the academic discipline
«NON-REMOVABLE PROSTHETICS»**


(3-d year, 6-th semester)

For the specialty: **7-07-0911-03 "Dentistry"**

Total time of classes: 176 hours

Discussed at the Methodical
Meeting of the Department of
Orthopedic Dentistry and Orthodontics
Protocol № 6, 24.11.2025

BSMU, Minsk

APPROVED by
 Head of the Department of Orthopedic
 Dentistry and Orthodontics
 Ya.I. Timchuk
 Protocol of the Methodical
 Meeting of the Department № _6_
 24.11.2025

**Thematic Plan of Practical Training in the academic discipline
 «Non-removable prosthetics» for 6th semester, 3rd year students**

1. Prosthetics of partial absence of teeth. Clinical picture, classification of dentition defects.
Hygienic antisepsis of the skin of the hands of medical personnel.
2. Prosthetic treatment of patients with partial absence of teeth with fixed dentures. Methods examination of patients. Indications and contraindications to the choice of construction fixed dentures.
Completion of a dental outpatient card. Completion of a work order for an orthopedic appointment.
3. Odontoparodontogram. Justification of the choice of design and abutments in bridge dentures. stamina and reserve forces of the periodontium.
Completion of a dental outpatient card. Completion of a work order for an orthopedic appointment.
4. Clinical and laboratory stages of manufacturing stamped-soldered bridges.
Selection of medicine and anesthesia method.
5. Preparation of teeth, taking impressions in the manufacture of bridge dentures (stamped-soldered, cast-metal, combined).
Taking alginate impressions.
6. The technique of taking impressions for the manufacture of the intermediate part of the bridge dentures. The choice of impression materials depending on the construction materials of the dentures.
Taking dual-layer silicone impressions.
7. Determination and methods of fixation of central occlusion in the manufacture of bridges.
Determining and fixing habitual occlusion when making bridgework prostheses.
8. Inspection of structures, final manufacture, application and fixation of bridge dentures.
Checking the construction of metal bridgework prostheses.
9. Clinical and laboratory stages of manufacturing of cast-metal, metal acrylic, metal ceramic dentures.
Checking the construction of metal bridgework prostheses.
10. Adhesive bridge dentures. Modern construction materials for manufacturing and luting. Methods of manufacture and methods of luting.
Fixation of bridgework prostheses made from various construction materials.
11. Modern construction materials and methods of manufacturing metal-free bridge dentures.
Determining tooth color.
12. CAD / CAM technologies in fixed dental prosthetics.
Determining the index of the damaged occlusal surface of the tooth (IDOST) and choosing the type of orthopedic construction based on the index.
13. Clinical stages and modern materials for fixing metal-free fixed dentures.
Fixation of bridgework prostheses made from various construction materials.

14. Errors and complications in the prosthetic treatment of patients with partial defects of the dentition with bridge dentures.

Checking the construction of metal bridgework prostheses.

15. Types of dental implantation. Indications and contraindications for use. Characteristics of construction materials.

Taking alginate impressions.

16. Types of dental implants and abutments.

Taking dual-layer silicone impressions.

Thematic Plan of Lectures

6th semester, 3rd year students in the academic discipline

«Non-removable prosthetics»

1. Partial defects of dentition. Constructions of fixed dentures.
2. Bridge (stamped-soldered, combined) dentures. Prosthetic treatment planning.
3. The technique of taking impressions for the manufacture of bridge dentures. Fixation of central occlusion in the manufacture of bridges.
4. Cast-metal, metal acrylic, metal ceramic dentures.
5. Adhesive bridge dentures.
6. Metal-free bridge dentures.
7. Errors and complications in the prosthetic treatment of patients with partial defects of the dentition with bridges.
8. Dental implantation.

Lectures - 8 (12 hours)

Practical lessons - 80 hours

Number of weeks - 16

Total training hours - 176 hours

Final assessment - examination

LITERATURE**Basic:**

1. Removable Partial Dentures. A Practitioners' Manual / Editor Olcay Şakar. – 2nd Edition. – Springer, 2024. – 423 p.
2. Waliszewski, Michael P. Brudvik's Advanced Removable Partial Dentures. Book of Prosthodontics. – 2nd Edition. – UK : Quintessence Publishing, 2022. – 203 p.

Additional:

3. Complete dentures. Algorithm of producing. / S. A. Naumovich [et al.]. – 3rd ed.– Minsk : BSMU, 2018. – 32 p.
 4. Fixed dentures. Algorithm of producing. / S. A. Naumovich [et al.]. – 3rd ed. – Minsk : BSMU, 2018. – 30 p.
 5. Removable partial dentures. Algorithm of producing. / S. A. Naumovich [et al.]. – 3rd ed. – Minsk : BSMU, 2018. – 16 p.
- Electronic courseware for the educational discipline «Non-removable»
6. <https://etest.bsmu.by/course/view.php?id=1401>

BELARUS STATE MEDICAL UNIVERSITY, DENTAL FACULTY
EXAMINATIONAL SHEET
PRACTICAL SKILLS NON-REMOVABLE PROSTHETICS DENTISTRY,

YEAR **3** SEMESTER **6** GROUP _____ Student


Teacher	Members of examinational group		Date		
Practical skills	Point	realization ("Yes", "No")		Examina- tion group	Point
		Student	Teacher		
Use the following methods of examination:					
1.1 Interview of patient	2				
1.2 Estimation of facial signs	2				
1.3 Examination of mouth cavity, instrumental examination	3				
1.4 Determination of index TOSFI (Tooth Occlusal Surface Failure Index)	2				
1.5. Determining of masticatory effectiveness by Agapov	2				
2. To determine indications for:					
2.1 Sanation of mouth cavity	3				
2.2 Special surgical measures	3				
3. Analysis of research and diagnosis of dental arch defects	3				
4. Completion of odontoperiodontogram	3				
5. Calculation of reserve forces depending on the degree of bone tissue atrophy	3				
4. Determination of indications for the selection of abutment teeth when making bridge prostheses	3				
5. Choice of anesthesia method	3				
6. Execution of individual stages of treatment:					
6.1 Tooth preparation for the manufacture of bridgework prostheses					
6.1.1 Stamped-soldered	5				
6.1.2 Metal-acrylic	5				
6.1.3 Metal-ceramic	5				
6.1.4 Non-metallic	5				
6.2 Obtaining impressions for the manufacture of bridge prostheses:					
6.2.1 Plaster	5				
6.2.2 Alginate materials	5				
6.2.3 Double	5				
6.3 Making models	5				
6.4 Fixation of central occlusion	5				
6.5 Checking the construction of bridge prostheses	5				
6.6 Fixation of bridge prostheses	5				
6.7 Choice of implantation method	5				
6.8 Choice of dental implants and abutments	5				
7. Medical documentation	3				

POINTS

MARK

Comment: _____

Signs: _____

APPROVED by
 Head of the Department of Orthopedic
 Dentistry and Orthodontics

 Ya.I. Timchuk
 Protocol of the Methodical
 Meeting of the Department № _6_
 24.11.2025

**CRITERIA FOR ASSESSING STUDENTS' KNOWLEDGE ON A 10-POINT SCALE
 for the module "Orthopedic Dentistry": Non-removable prosthetics**

No.	Mark	Criteria
1	10 (ten) points, passed	<p>Systematized, deep and comprehensive knowledge of all sections of the educational program for the module "Orthopedic Dentistry": Non-removable prosthetics, as well as on the main issues beyond its scope;</p> <p>accurate use of scientific terminology (including in a foreign language), articulate and logically correct presentation of answers to questions, ability to make reasoned conclusions and generalizations;</p> <p>flawless mastery of the tools of the module "Orthopedic Dentistry": Non-removable prosthetics, ability to effectively use them in the formulation and solution of scientific and professional tasks;</p> <p>strong ability to independently and creatively solve complex problems in non-standard situations;</p> <p>complete and in-depth assimilation of the primary and additional literature on the studied module "Orthopedic Dentistry": Non-removable prosthetics;</p> <p>ability to freely navigate theories, concepts, and directions related to the studied module "Orthopedic Dentistry": Non-removable prosthetics and provide them with an analytical assessment, using scientific achievements from other dental disciplines;</p> <p>creative independent work during practical classes, active creative participation in group discussions, high level of task performance culture.</p>

2	9 (nine) points, passed	<p>Systematized, deep and comprehensive knowledge of all sections of the educational program for the module "Orthopedic Dentistry": Non-removable prosthetics;</p> <p>accurate use of scientific terminology (including in a foreign language), articulate and logically correct presentation of answers to questions,</p> <p>mastery of the tools of the module "Orthopedic Dentistry": Non-removable prosthetics, ability to effectively use them in the formulation and solution of scientific and professional tasks;</p> <p>ability to independently and creatively solve complex problems in non-standard situations;</p> <p>complete assimilation of the primary and additional literature on the studied module "Orthopedic Dentistry": Non-removable prosthetics;</p> <p>ability to freely navigate theories, concepts, and directions related to the studied module "Orthopedic Dentistry": Non-removable prosthetics and provide them with an analytical assessment,</p> <p>creative independent work during practical classes, active creative participation in discussions, high level of task performance culture.</p>
3	8 (eight) points, passed	<p>Systematized, deep and comprehensive knowledge of all sections of the educational program for the module "Orthopedic Dentistry": Non-removable prosthetics,</p> <p>accurate use of scientific terminology (including in a foreign language), articulate and logically correct presentation of answers to questions, ability to make reasoned conclusions and generalizations;</p> <p>assimilation of primary and additional literature recommended by the educational program for the module "Prosthetic Dentistry": Fixed prosthodontics;</p> <p>ability to navigate through the main theories, concepts, and directions within the module "Prosthetic Dentistry": Fixed prosthodontics and provide their analytical assessment;</p> <p>independent work during practical classes, participation in group discussions, high level of task execution culture.</p>

4	7 (seven) points, passed	<p>systematic, deep, and comprehensive knowledge in all sections of the educational program for the module "Prosthetic Dentistry": Fixed prosthodontics;</p> <p>use of scientific terminology (including foreign language), articulate and logically correct presentation of answers to questions, ability to make well-founded conclusions and generalizations;</p> <p>mastery of the toolkit of the module "Prosthetic Dentistry": Fixed prosthodontics, ability to use it in setting and solving scientific and professional tasks;</p> <p>proficient command of typical solutions within the framework of the educational program for the module "Prosthetic Dentistry": Fixed prosthodontics;</p> <p>assimilation of primary and additional literature recommended by the educational program for the module "Prosthetic Dentistry": Fixed prosthodontics;</p> <p>ability to navigate through the main theories, concepts, and directions within the module "Prosthetic Dentistry": Fixed prosthodontics and provide their analytical assessment;</p> <p>independent work during practical classes, participation in group discussions, high level of task execution culture.</p>
5	6 (six) points, passed	<p>comprehensive knowledge in all sections of the educational program for the module "Prosthetic Dentistry": Fixed prosthodontics;</p> <p>use of scientific terminology, correct presentation of answers to questions, ability to make well-founded conclusions and generalizations;</p> <p>mastery of the toolkit of the module "Prosthetic Dentistry": Fixed prosthodontics, ability to use it in setting and professional tasks;</p> <p>independent command of typical solutions within the framework of the educational program for the module "Prosthetic Dentistry": Fixed prosthodontics</p> <p>assimilation of primary literature recommended by the educational program for the module "Prosthetic Dentistry": Fixed prosthodontics;</p> <p>ability to navigate through the main theories, concepts, and directions within the module "Prosthetic Dentistry": Fixed prosthodontics and provide their assessment;</p> <p>active work during practical classes, participation in group discussions, high level of task execution culture.</p>

6	5 (five) points, passed	<p>Sufficient knowledge in all sections of the educational program for the module "Prosthetic Dentistry": Fixed prosthodontics; use of terminology, presentation of answers to questions, ability to make conclusions and generalizations; mastery of the toolkit of the module "Prosthetic Dentistry": Fixed prosthodontics, ability to use it in solving professional tasks; command of typical solutions within the framework of the educational program for the module "Prosthetic Dentistry": Fixed prosthodontics; assimilation of primary literature recommended by the educational program for the module "Prosthetic Dentistry": Fixed prosthodontics; ability to navigate through the main theories, concepts, and directions within the module "Prosthetic Dentistry": Fixed prosthodontics. independent work during practical classes, participation in group discussions, high level of task execution culture.</p>
7	4 (four) points, passed	<p>Sufficient level of knowledge within the educational program for the module "Prosthetic Dentistry": Fixed prosthodontics; assimilation of primary literature recommended by the educational program for the module "Prosthetic Dentistry": Fixed prosthodontics; use of scientific terminology, logical presentation of answers to questions, ability to draw conclusions without significant errors; mastery of the toolkit of the module "Prosthetic Dentistry": Fixed prosthodontics, ability to use it in solving standard tasks; ability to solve standard tasks under the guidance of the instructor; understanding of the main theories, concepts, and directions within the module "Prosthetic Dentistry": Fixed prosthodontics and providing their assessment; work under the guidance of the instructor during practical classes, acceptable level of task execution culture.</p>
8	3 (three) points, passed	<p>Insufficient level of knowledge within the educational program for the module "Prosthetic Dentistry": Fixed prosthodontics; knowledge of some of the primary literature recommended by the educational program for the module "Prosthetic Dentistry": Fixed prosthodontics; use of scientific terminology, presentation of answers to questions with significant logical errors; weak mastery of the toolkit of the module "Prosthetic Dentistry": Fixed prosthodontics, incompetence in solving standard tasks; inability to navigate the main theories, concepts, and directions within the module "Prosthetic Dentistry": Fixed prosthodontics; passivity in practical and laboratory classes, low level of task execution culture.</p>

9	2 (two) points, passed	Fragmentary knowledge within the educational program for the module "Prosthetic Dentistry": Fixed prosthodontics; knowledge of some of the primary literature recommended by the educational program for the module "Prosthetic Dentistry": Fixed prosthodontics; inability to use scientific terminology of the module "Prosthetic Dentistry": Fixed prosthodontics, presence of significant logical errors in the answers; passivity in practical and laboratory classes, low level of task execution culture.
10	1 (one) point, passed	Lack of knowledge and competencies within the educational program for the module "Prosthetic Dentistry": Fixed prosthodontics, refusal to answer, absence from assessment without valid reason.

TOTAL TIME OF CLASS – 5 academic hours (200 minutes).

PLAN FOR PRACTICAL CLASSES
3-d year, 6-th semester

№	Stages of a practical class	Time in min.
1.	Organizational stage	10
2.	Control of the initial knowledge level	20
3.	Training stage	40
4.	Practicing a practical skill	90
5.	Monitoring the level of the obtained knowledge or mastery of a practical skill	30
6.	Final stage	10

LIST OF AVAILABLE TEACHING METHODS

Linear (traditional) method;
active (interactive) methods:
problem-Based Learning (PBL);
case-Based Learning (CBL);
simulation-based learning.

LIST OF SIMULATION EQUIPMENT USED

1. Dentist's workplace (desk, chair).
2. Dental unit with a light and spittoon.
3. Instrument table with a fixed rigid waste container of class B.
4. Dental chair (for the dentist).
5. Trolley with consumables and waste disposal containers.
6. Sink.
7. Container for collecting class A waste, 10 liters capacity.
8. Container for collecting class B waste, 10 liters capacity.
9. Set of tools in simulated sterile packaging (tray - 1 pc., dental tweezers - 2 pcs., dental mirror - 1 pc., dental probe - 1 pc., excavator - 1 pc., spatula - 1 pc., burnisher - 1 pc., angled probe - 1 pc.).
10. Set of cutting instruments for tooth preparation using a turbine handpiece.
11. Paper palette for mixing the second layer of silicone material.
12. Rubber bowl for mixing impression materials.
13. Spatula for mixing impression materials.
14. Dental spatula.
15. Impression trays for upper and lower jaws.
16. Scalpel.
17. Retraction cord.
18. Silicone impression material.
19. Alginate impression material.
20. Plaster.

METHODOLOGICAL RECOMMENDATIONS FOR THE ORGANIZATION AND PERFORMANCE OF STUDENT INDEPENDENT WORK IN THE ACADEMIC DISCIPLINE

The time allocated for independent work can be used by students for:

- preparation for lectures and practical classes;
- preparation for credit and exam in the academic discipline;
- study of topics (questions) submitted for independent study;
- solving situational problems;
- compiling a review of scientific literature on a given topic;
- note-taking of educational literature.

LESSON 1

Subject: Prosthetics of partial absence of teeth. Clinical picture, classification of dentition defects.

Total time of class – 5 academic hours (200 min).

№	Stages of a practical class	Time in min.
1.	Organizational stage	10
2.	Control of the initial knowledge level	20
3.	Training stage	40
4.	Practicing a practical skill	90
5.	Monitoring the level of the obtained knowledge or mastery of a practical skill	30
6.	Final stage	10

Purpose of the lesson: to teach students how to examine patients with partial dentition defects and make a diagnosis. To study the etiology, clinical picture and pathogenesis of partial dentition defects.

Objectives of the lesson:

1. To become familiar with methods of examination and diagnosis of patients with partial secondary adentia.
2. Master the skills of making a diagnosis and drawing up a treatment plan
3. Master the skills of analyzing additional research methods when diagnosing partial secondary adentia.
4. Master the interpretation of examination data of patients with partial absence of teeth, taking into account the classification of dentition defects.

Class location - the clinical setting.

Practical skills mastered during the class:

Hygienic antisepsis of the skin of the hands of medical personnel.

Form of control of the practical class: electronic tests; survey; solving situational tasks.

Place of practical skill implementation – at the outpatient appointment.

Practical skill assessment criteria – according to the assessment sheet (checklist) for monitoring practical skills in the academic discipline in points from 0 to 3.

Requirements for initial level of knowledge:

1. The concept of occlusion, articulation and occlusion.
2. Reasons leading to the appearance of defects in the crown of teeth.
3. Features of examination of patients with damage to hard dental tissues.
4. Features of examining patients with partial dentition defects.

Control questions from related disciplines:

1. Basic diagnostic methods in dentistry.
2. Additional diagnostic methods in dentistry.
3. Etiology and pathogenesis of caries and its complications.
4. Etiology and pathogenesis of periodontal diseases.
5. Anomalies in the development of the dental system leading to partial edentia

Control questions:

1. Etiology and pathogenesis of partial absence of teeth.
2. Methods for examining patients with partial absence of teeth.
3. Clinical symptoms of partial absence of teeth.
4. Classification of dentition defects (according to Kennedy, Gavrilov).
5. Secondary deformations of the dentition, pathogenesis, clinic.
6. Changes in the temporomandibular joint in the absence of teeth.

Partial absence of teeth (partial secondary edentia) is one of the most common diseases: according to the World Health Organization, it affects up to 75% of the population in various regions of the globe. In our country, in the general structure of medical care for patients in dental treatment institutions, this disease makes up from 40 to 75% and occurs in all age groups of patients. Partial secondary adentia is one of the reasons for the development of specific complications in the maxillofacial area, such as the Popov-Godon phenomenon, dysfunction of the temporomandibular joints and the corresponding pain syndrome. Untimely restoration of the integrity of the dentition in the case of their partial absence (partial secondary adentia) causes the development of such functional disorders as overload of the periodontium of the remaining teeth, the development of pathological abrasion, and disturbances in the biomechanics of the dentoalveolar system.

Untimely and/or poor-quality treatment of partial secondary adentia leads to the development of periodontal diseases, and in the long term - to complete loss of teeth (complete secondary adentia of both jaws).

Partial absence of teeth (partial secondary adentia) should be distinguished from primary adentia, in which a defect in the dentition has developed due to the absence or death of the rudiments of permanent teeth. A pathological condition caused by a violation of the continuity of the dentition, i.e., the absence of teeth in the dental system is called partial secondary edentia, or a defect in the dentition.

The causes of partial secondary adentia include:

1. Disorders that occur during the formation of the dental system:
 - primary partial adentia caused by the absence of tooth buds;
 - improper development of tooth buds (impacted teeth).
2. Disorders associated with the loss of teeth in an already formed dental system and resulting from:
 - complicated caries;
 - periodontitis of various etiologies;
 - periodontal disease;
 - surgical interventions for osteomyelitis, neoplasms;
 - injuries of various etiologies;
 - removal for orthodontic reasons.

Scheme: “Clinical examination”

Survey	
<p>Complaints and subjective state of the patient:</p> <ul style="list-style-type: none"> • defects of the maxillofacial area; • impaired diction, chewing food or cosmetic defects; • insufficient functioning of the gastrointestinal tract. <p>Patient's life history:</p>	<p>History of this disease. The earliest manifestations of the disease, the nature and characteristics of its course, the nature of the process: the duration of tooth loss, the progression of the process, the cause of tooth loss (according to the patient), the patient's sensations in connection with the loss of a tooth or its disease (insufficient chewing, itching in the gums,</p>

<ul style="list-style-type: none"> • life and everyday life of the patient; • past illnesses; • working conditions, profession; • bad habits (smoking, alcohol); • main and concomitant diseases at the time of the interview. <p>Family history:</p> <ul style="list-style-type: none"> • place of birth and life of the patient; • hereditary diseases (with anomalies of the dental system). 	<p>unpleasant sensations, the appearance of inflammatory processes, traumatic irritation). The nature, type and extent of treatment performed and its results. Frequency of seeking dental care. Oral care.</p>
---	---

Scheme of OOD on the Subject: “Features of clinical examination”

Action steps	Tools for work	Criteria for self-control
External examination of the patient	Workplace of an orthopedic dentist, tray with tools	The configuration and proportionality of the facial parts, the severity of the nasolabial and chin folds, the front and profile of the face.
Degree of mouth opening.		First we determine the degree of mouth opening. Difficulty opening the mouth can occur due to narrowing of the oral opening, muscle and joint contractures
Study of the movements of the articular heads.		We place the middle and index fingers on the TMJ area and invite the patient to open and close his mouth. We find out the absence and presence of crunching and clicking in the joints.
Oral examination		Examination of the oral cavity begins with the mucous membrane of the cheeks, alveolar process, soft and hard palate, floor of the mouth, tongue, tonsils and posterior pharyngeal wall. We pay attention to humidity, color (pink, pale pink, bluish), density, bleeding of the mucous membrane, its sensitivity to irritation, and pay special attention to the presence of pathological gum pockets and tartar deposits.
Examination of individual teeth		We examine the dentition of the upper jaw from the rightmost chewing tooth to the leftmost chewing tooth, then the lower

		<p>dentition from the leftmost chewing tooth to the rightmost chewing tooth. From the information received, we create a dental formula - a diagram. We determine the type of bite, location, shape, color, size, condition of the crowns and mobility of the teeth. Using x-rays, we determine the condition of the periapical tissues. Teeth can have different colors: from milky white to dark brown.</p>
<p>Determining the condition of the periodontium.</p>		<p>We perform percussion of the tooth with the handle of the probe, and with our left hand and a mirror we move away the soft tissues of the cheek. A healthy periodontium is painless upon percussion, but painful when inflamed. Tooth mobility is a removable process if the periodontium and tooth socket are preserved. To determine the condition of the periodontium, vertical percussion, marginal-tubercular or horizontal percussion is used.</p>
<p>Determination of tooth stability.</p>		<p>According to Entin, there are 4 degrees of mobility: 1 – in one direction (vestibular-oral direction or medio-distal); 2 – in two directions (vestibular-oral and medio-distal); 3 – vertical mobility is added to horizontal mobility; 4 - rotates in all directions. Clinical examination of the root of the supporting teeth and surrounding tissues should be supplemented by the study of x-rays. Under the influence of internal and external factors, the dentition does not always develop harmoniously. Anomalies of their development are very often observed. Teeth can also change their position in the dentition under the influence of overload</p>

		<p>when the integrity of the 61 dentition is violated or due to dystrophy of the supporting apparatus. Teeth are displaced towards a defect in the dentition, missing opposing teeth, or in the vestibular direction.</p>
<p>Determination of the degree of resorption of the walls of the bone socket of the tooth</p>		<p>Resorption of the walls of the bone socket is an irreversible process. We make a conclusion about the magnitude of alveolar resorption only on the basis of clinical and radiological data. Clinically - using a mirror, periodontal probe (straight or at an angle) with divisions on the working surface. We blunt the tip of the probe to protect the bottom of the pocket from damage. We compare the distance from the neck of the tooth to the bottom of the gum pocket with the height of the crown of the tooth, which is half the length of the root, and evaluate the degree of resorption of the bone walls of the tooth socket. Due to the uneven bone resorption of the tooth socket, it is determined by the area with the highest immersion depth of the graduated probe. The resistance of the periodontium to stress decreases with increasing atrophy of the bone walls of the tooth socket. The obtained data can be entered into a diagram, thereby obtaining a graphical representation of the state of the periodontium of the dentition. This diagram is called an odontoperiodontogram</p>

CLINICAL PICTURE OF PARTIAL SECONDARY ADENTIA

The clinical picture is characterized by the absence of one or more teeth in the presence of one or more natural teeth or their roots. Manifestations of partial secondary adentia depend on the topography of the defects and the number of missing teeth and are varied. The peculiarity of this pathology is the absence of pain syndrome in patients. In the absence of one or two, and sometimes several teeth, patients often do not feel discomfort and do not consult a doctor. The partial absence of even one tooth in any functionally oriented group of teeth can lead to the development of the Popov-

Godon phenomenon, direct or reflected traumatic nodes, resulting in inflammation in the gingival margin, destruction of bone tissue and the development of pathological pockets, primarily in the area of the teeth, limiting the defect. In the absence of one or more frontal teeth in the upper jaw, the clinical picture is characterized by the symptom of “recession” of the upper lip. With a significant absence of lateral teeth, a “recession” of the soft tissues of the cheeks and lips is noted. In the absence of even one frontal tooth in the upper and/or lower jaw, diction may be impaired. Partial absence of teeth in both jaws without preservation of antagonizing pairs in each functionally oriented group of teeth leads to a decrease in the height of the lower part of the face, often to the development of angular cheilitis (“jams”), pathology of the temporomandibular joint, changes in facial configuration, pronounced nasolabial and chin folds, drooping corners of the mouth. The partial absence of chewing teeth causes dysfunction of chewing; patients complain of poor chewing of food. After the loss or removal of teeth, atrophy of the periodontal ligaments occurs in the corresponding areas of the jaws; with the loss of more than two teeth, atrophy of the alveolar processes themselves gradually develops, progressing over time. Partial secondary adentia is an irreversible process. Restoring the integrity of the dentition is possible only by orthopedic treatment methods using fixed and/or removable denture structures.

CLASSIFICATION OF PARTIAL SECONDARY ADENTIA

In clinical practice, partial absence of teeth (partial secondary adentia) of the upper jaw and lower jaw is not distinguished. The principles of classification are the same for them.

The Kennedy classification of partial secondary adentia (dentition defects) has become most widespread and practically used. There are four classes in this classification:

- Bilateral distally unlimited defect (end).
- Unilateral distally unlimited defect (end).
- Unilateral distally limited defect (included).
- Absence of front teeth (defect in the frontal region, included defect).

Each class has a number of subclasses. In the clinical application of the Kennedy classification, the doctor rarely encounters “pure” classes; variants of subclasses and/or a combination of defects of various classes and subclasses are much more often observed.

Another well-known classification of dentition defects is the classification of E. I. Gavrilov. It identifies four groups of defects:

- Single-sided and double-sided end.
- Included (lateral - single-sided, double-sided and front).
- Combined.
- Jaws with single teeth preserved.

SITUATIONAL TASKS

1. Patient S., 24 years old, complains of an aesthetic defect and difficulty biting food. Upon examination, it was found that the patient was practically healthy. Teeth 11,21,22 were removed as a result of injury 30 days ago. The remaining teeth are intact and stable. 65 Orthognathic bite, pale pink mucosa. The R-gram channel of tooth 12 is filled with filling material to the root apex. There are no pathological changes in the periapical tissues. Give a classification according to Kennedy and Gavrilov.

2. Patient X., 38 years old, came to the clinic with complaints of multiple dental defects. I have not had prosthetics before. Teeth 17,15,14,11,25,26 were lost due to complicated caries. The remaining teeth are intact and stable. The bite is orthognathic. Give a classification of defects according to Kennedy and Gavrilov.

3. Patient R., 65 years old, complained of difficulty chewing food due to the breakdown of a partial removable plate denture of the upper jaw. Previously, he had undergone prosthetics several

times, the last prosthetics was 7 years ago. Tooth 23 is preserved on the upper jaw, teeth 33 and 34 on the lower jaw, and the rest are missing. Give a classification according to Kennedy and Gavrillov.

4. Patient R., 37 years old, presented with a cosmetic defect and the inability to bite food. The loss of front teeth is associated with trauma. Objectively: teeth 11 and 12 are absent, the remaining teeth are stable, intact. Make a diagnosis? What additional examination methods are indicated? Have a treatment plan?

5. Patient A., 43 years old, complains of the absence of chewing teeth in the lower jaw, difficulty chewing food. Tooth 36 was removed 3 years ago as a result of complicated caries, tooth 35 had an extensive filling on the distal surface, degree I mobility, tooth 37 was restored with a filling (IROPS = 0.3), the remaining teeth are stable and intact. Make a diagnosis? What additional research methods can be used to diagnose the choice of the correct treatment method? Treatment plan?

6. Patient B., 37 years old. Complaints about the absence of chewing teeth 16, 17 in the upper jaw, difficulty chewing food. Objectively: tooth 15 is stable, there is a filling on the proximal surface, percussion is painful. Tooth 18 is intact, percussion is painless, the coronal part of the tooth is well defined, the tooth is stable. Diagnosis. Treatment plan.

LITERATURE

Basic:

1. Removable Partial Dentures. A Practitioners' Manual / Editor Olcay Şakar. – 2nd Edition. – Springer, 2024. – 423 p.

2. Waliszewski, Michael P. Brudvik's Advanced Removable Partial Dentures. Book of Prosthodontics. – 2nd Edition. – UK : Quintessence Publishing, 2022. – 203 p.

Additional:

3. Complete dentures. Algorithm of producing. / S. A. Naumovich [et al.]. – 3rd ed. – Minsk : BSMU, 2018. – 32 p.

4. Fixed dentures. Algorithm of producing. / S. A. Naumovich [et al.]. – 3rd ed. – Minsk : BSMU, 2018. – 30 p.

5. Removable partial dentures. Algorithm of producing. / S. A. Naumovich [et al.]. – 3rd ed. – Minsk : BSMU, 2018. – 16 p.

Electronic courseware for the educational discipline «Non-removable»

6. <https://etest.bsmu.by/course/view.php?id=1401>

LESSON 2

Subject: Prosthetic treatment of patients with partial absence of teeth with fixed dentures. Methods examination of patients. Indications and contraindications to the choice of construction fixed dentures.

Total time of class – 5 academic hours (200 min).

№	Stages of a practical class	Time in min.
1.	Organizational stage	10
2.	Control of the initial knowledge level	20
3.	Training stage	40
4.	Practicing a practical skill	90
5.	Monitoring the level of the obtained knowledge or mastery of a practical skill	30
6.	Final stage	10

Purpose of the lesson: to teach students how to select and justify the design of dentures.

Objectives of the lesson:

1. Familiarize yourself with the methods of examining patients.
2. Learn to determine indications for choosing fixed orthopedic structures.
3. Learn to identify contraindications to the choice of orthopedic fixed structures.
4. Master the differential diagnosis of dental diseases.

Class location - the clinical setting.

Practical skills mastered during the class:

Completion of a dental outpatient card. Completion of a work order for an orthopedic appointment.

Form of control of the practical class: electronic tests; survey; solving situational tasks.

Place of practical skill implementation – at the outpatient appointment.

Practical skill assessment criteria – according to the assessment sheet (checklist) for monitoring practical skills in the academic discipline in points from 0 to 3.

Requirements for initial level of knowledge:

1. Causes leading to the appearance of dental defects.
2. Methods of examining a patient in an orthopedic dentistry clinic.
3. Deformation of the dentition, causes.
4. Preparation of the oral cavity for prosthetics for dentition defects.
5. Indications and contraindications for prosthetic bridges.

Control questions from related disciplines:

1. Additional diagnostic methods in dentistry.
2. Anomalies in the development of the dental system, leading to partial adentia.
3. The concept of occlusion, articulation and occlusion.
4. Causes leading to the appearance of defects in the crown of teeth.
5. Features of examination of patients with damage to hard dental tissues.
6. Features of examining patients with partial dentition defects.

Control questions:

1. Basic methods of examining patients

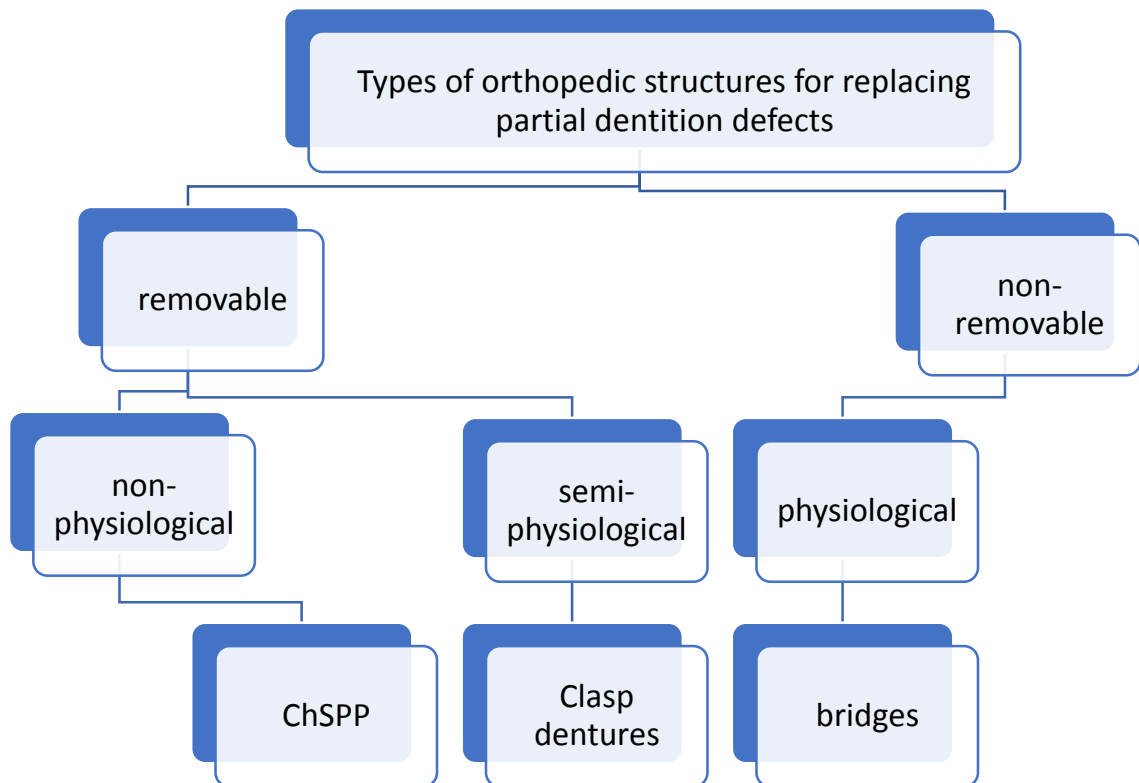
2. Additional methods of examining patients
3. Types of dentures used to treat partial edentia.
4. Indications for depulping teeth in the manufacture of bridges
5. Indications and contraindications for fixed prosthetics depending on the topography and nature of the defect
6. Preparing the oral cavity for the manufacture of bridges

Partial secondary adentia is diagnosed by clinical examination, history taking and clinical examination. Diagnostics is aimed at eliminating factors that prevent the immediate start of prosthetics. These factors include the presence of: – unsanitized teeth; – unremoved roots under the mucous membrane; – exostoses; – tumor-like diseases; – inflammatory processes; – diseases and lesions of the oral mucosa. When diagnosing, it is necessary to take into account the results of clinical and radiological examinations of existing teeth, especially those planned for support, including their periodontal status, as well as the general and functional state of the dental system.

Basic principles of orthopedic treatment of partial secondary adentia:

- When planning orthopedic treatment, the priority should be to preserve the remaining teeth.
- Each tooth planned to support a prosthesis must be assessed from the perspective of the condition of hard tissues, pulp, periapical tissues, and periodontium. Depending on the results of this assessment, the support is determined as reliable, questionable or unsatisfactory. First of all, reliable teeth should be used for supports. The preservation of a tooth largely depends on its strategic importance as a support for the prosthesis, as well as on the ratio of labor intensity and cost of treatment measures necessary to preserve it and achieve results.
- You cannot begin prosthetics without preparatory measures, if any are necessary.
- Not every dental defect requires prosthetics. Prosthetics up to the complete set of dentition is not mandatory. The individual characteristics of the patient's dental system play a decisive role.
- Orthopedic structures should provide opportunities for optimal oral hygiene.
- In the manufacture of fixed bridges, structures of short length are preferred. Long structures that connect several functionally oriented groups of teeth into a single block should be avoided. Expanding the scope of prosthetics is justified only in conditions where this solution is the only opportunity to ensure optimal individual functioning of the dentofacial system.
- Poor oral hygiene of the patient is a relative contraindication to fixed prosthetics.
- The worse the patient follows medical recommendations and cooperates with the doctor, the simpler the orthopedic design should be.

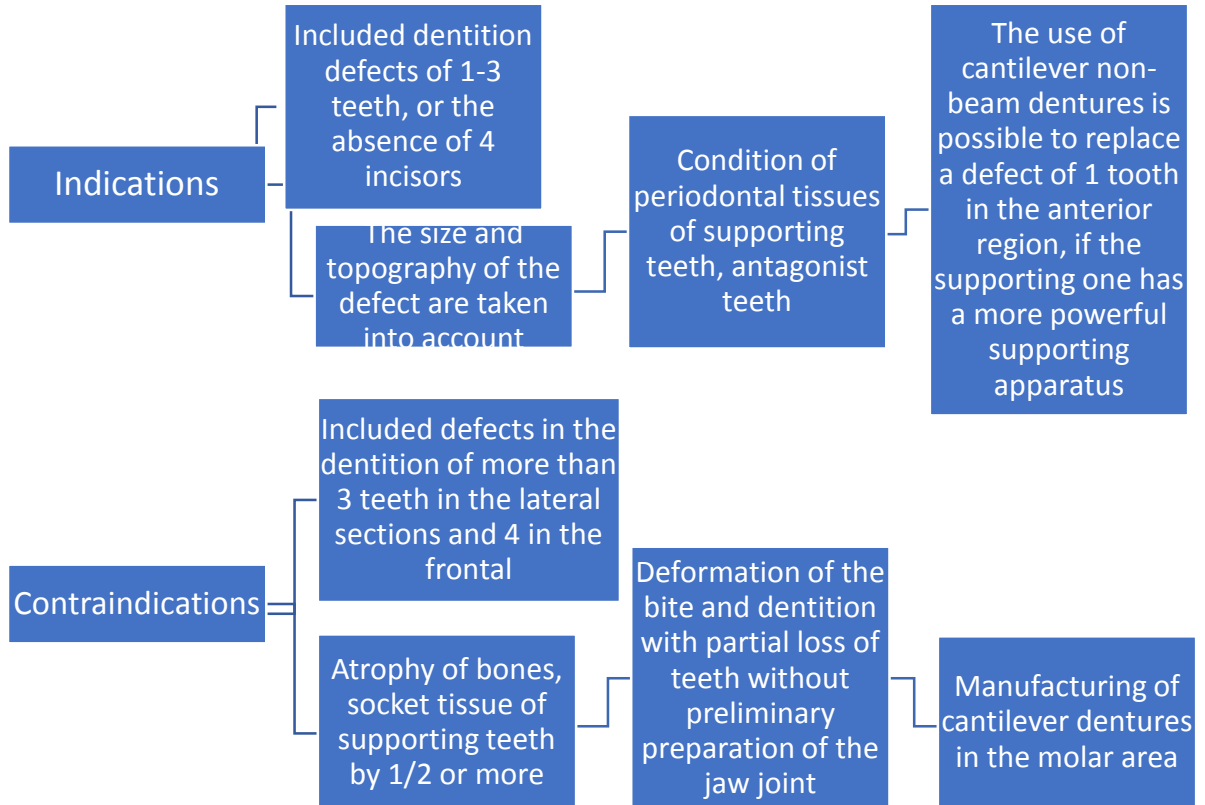
Scheme: “Types of orthopedic structures”



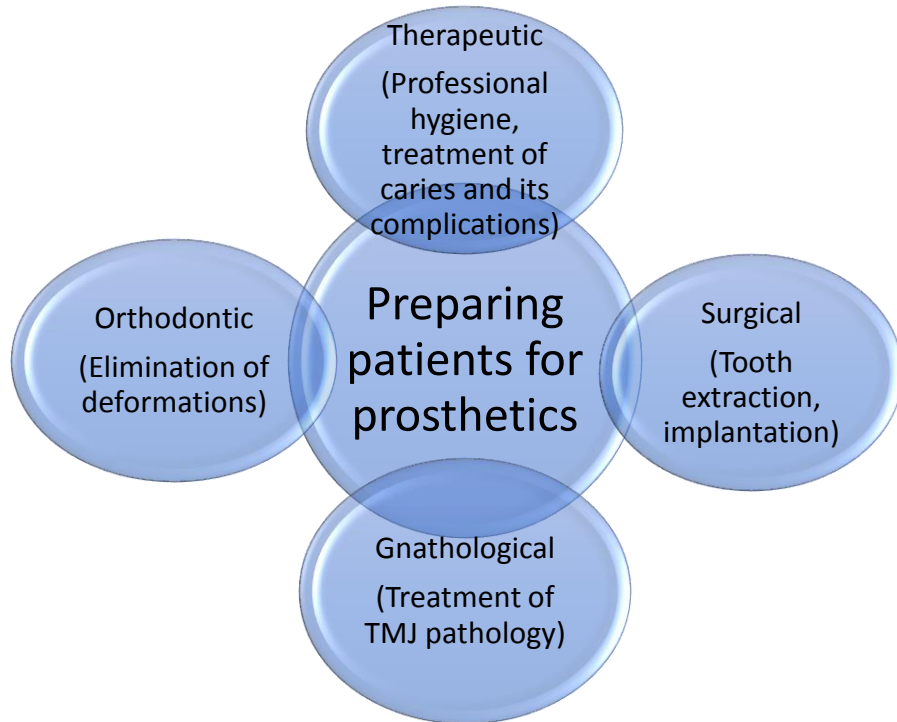
Indications for tooth depulvation:

- MOD filling , etc.)
- Impossibility of preparing a tooth without opening the pulp chamber (abnormal position of teeth in the dentition, Popov-Godon phenomenon, change in tooth inclination, etc.)
- The presence of a pulpless abutment tooth in a bridge prosthesis
- Generalized pathological abrasion in a decompensated form with a decrease in height of more than 3-4 mm.

Scheme: “Indications and contraindications for the use of bridges”



Scheme “Preparation of patients for prosthetics”



SITUATIONAL TASKS

1. Patient B., 36 years old, came to the clinic with complaints of a cosmetic defect due to the loss of tooth 11, which was removed 1 month ago due to an exacerbation of complicated caries and the ineffectiveness of conservative therapy. Objectively: tooth 12 - the coronal part is discolored,

the tooth is stable, percussion is painless, there are no changes in the periodontium on the R-gram, the root canal is sealed to the apex. Tooth 21 is intact, percussion is painless, the tooth is stable. The mucous membrane of the alveolar process in the area of the removed 11 is physiologically colored, the alveolar process is round in shape, its apex is located at the level of the necks of teeth 21,12. What is your diagnosis? Have a treatment plan?

2. Patient K., 23 years old, presented with a cosmetic defect, the inability to bite food. The loss of front teeth is associated with occupational injury (hockey player). Objectively: teeth 12,11,21,22 are absent, the remaining teeth are stable, intact. Diagnosis? What additional examination methods are indicated? Treatment plan.

3. Patient A., 27 years old, complains of the absence of chewing teeth in the lower jaw, difficulty chewing food. Teeth 35 and 36 were removed 3 years ago as a result of complicated caries, tooth 34 had an extensive filling on the distal surface, degree I mobility, tooth 37 was restored with a filling (IROPS = 0.3), percussion is slightly painful, the remaining teeth are stable and intact. What additional research methods can be used to diagnose the choice of the correct treatment method? Preliminary treatment plan.

4. Patient A., 57 years old, came to the clinic with complaints of missing teeth 15, 16, 44, 45, 46 and associated chewing disorders. Make a diagnosis? Have a treatment plan?

5. Patient D., 20 years old, complains of a cosmetic defect as a result of injury. Objectively: teeth 11 and 21 are missing, teeth 12 and 22 are discolored, stable, percussion is painless. Suggest a treatment plan. Assessment of the quality of tooth preparation for the selected type of fixed prosthesis

6. Patient S., 45 years old, came to the clinic with complaints of the absence of chewing teeth in the upper and lower jaws, difficulty chewing food. On the upper jaw there are no teeth 16, 26, 27, on the lower jaw - 35, 36, 45, 46. Teeth 17, 15, 25, 27, 34, 37, 44, 47 are intact, percussion is painless. The patient was asked to make bridges based on teeth 17, 15, 25, 27, 34, 37, 44, 47. Describe the sequence of work of the orthopedic doctor with this patient. Assessing the quality of work.

LITERATURE

Basic:

1. Removable Partial Dentures. A Practitioners' Manual / Editor Olcay Şakar. – 2nd Edition. – Springer, 2024. – 423 p.

2. Waliszewski, Michael P. Brudvik's Advanced Removable Partial Dentures. Book of Prosthodontics. – 2nd Edition. – UK : Quintessence Publishing, 2022. – 203 p.

Additional:

3. Complete dentures. Algorithm of producing. / S. A. Naumovich [et al.]. – 3rd ed. – Minsk : BSMU, 2018. – 32 p.

4. Fixed dentures. Algorithm of producing. / S. A. Naumovich [et al.]. – 3rd ed. – Minsk : BSMU, 2018. – 30 p.

5. Removable partial dentures. Algorithm of producing. / S. A. Naumovich [et al.]. – 3rd ed. – Minsk : BSMU, 2018. – 16 p.

Electronic courseware for the educational discipline «Non-removable»

6. <https://etest.bsmu.by/course/view.php?id=1401>

LESSON 3

Subject: Odontoparodontogram. Justification of the choice of design and abutments in bridge dentures. stamina and reserve forces of the periodontium.

Total time of class – 5 academic hours (200 min).

№	Stages of a practical class	Time in min.
1.	Organizational stage	10
2.	Control of the initial knowledge level	20
3.	Training stage	40
4.	Practicing a practical skill	90
5.	Monitoring the level of the obtained knowledge or mastery of a practical skill	30
6.	Final stage	10

Purpose of the lesson: to teach students the analysis of odontoperiodontogram and techniques for choosing the design and supporting teeth in bridges.

Objectives of the lesson:

1. To become familiar with the concepts of endurance and reserve forces of the periodontium.
2. Learn to fill out an odontoparodontogram.
3. Learn to analyze odontoperiodontogram data.
4. Master the skills of selecting abutment teeth for bridge structures.
5. Learn to interpret the results of odontoparodontogram and x-ray examination.

Class location - the clinical setting.

Practical skills mastered during the class:

Completion of a dental outpatient card. Completion of a work order for an orthopedic appointment.

Form of control of the practical class: electronic tests; survey; solving situational tasks.

Place of practical skill implementation – at the outpatient appointment.

Practical skill assessment criteria – according to the assessment sheet (checklist) for monitoring practical skills in the academic discipline in points from 0 to 3.

Requirements for initial level of knowledge:

1. Causes leading to the appearance of dental defects.
2. Preparation of the oral cavity for prosthetics for dentition defects.
3. Indications and contraindications for prosthetic bridges.
4. Additional diagnostic methods in dentistry.

Control questions from related disciplines:

1. Periodontium, definition, structure.
2. Periodontal diseases.
3. Anatomical structure of teeth.
4. X-ray diagnostic methods in dentistry.
5. Methods of preparing the oral cavity for prosthetics.

Control questions:

1. Odontoparodontogram, definition.

2. Filling out an odonto-periodontogram and plotting a graph.
3. Endurance and reserve forces of the periodontium.
4. Clinical and biological basis of prosthetic bridges.
5. Factors determining the choice of bridge design.
6. Selection of abutment teeth and their evaluation.

Odontoparodontogram is a graphic representation of the condition of the periodontium and dentition, i.e. recording the results of a study of the coronal part of the tooth and the functional state of the periodontium in the form of a table containing measurement data of the depth of the gingival sulcus or periodontal pockets, compared with radiographic data. The method was proposed by V. Yu. Kurlyandsky. (synonym – amphodontogram, from the previously used terms periodontium, amphodont). The chart table is filled out based on clinical and radiological examination data. The odontoperiodontogram is completed in the presence of the patient. The recording is carried out sequentially from the right wisdom tooth of the lower jaw to the left wisdom tooth of the lower jaw and from the left wisdom tooth of the upper jaw to the right wisdom tooth of the upper jaw.

For each tooth, the corresponding cell in the column is marked.

N - no pathological changes;

O - tooth missing;

1/4 - atrophy up to 1/4 (I degree);

1/2 - atrophy up to 1/2 (II degree);

3/4 - atrophy up to 3/4 (III degree);

more than 3/4 - IV degree atrophy;

R - tooth or root is present, but must be removed.

The condition of the hard tissues of the tooth (R, C, P, etc.) is noted in the line closest to the dental formula. After filling out the corresponding columns for the teeth of the upper and lower jaws, the actual damage to the supporting apparatus of each tooth is displayed in numbers in subsequent columns and its residual endurance is recorded. The data obtained focus the doctor's attention on the unevenness of the lesion in each jaw and make it possible to outline an orthopedic treatment plan, which should be based on the desire to equalize the force relationships between the dentition or their individual sections. Odontoparodontogram makes it possible to judge the condition of periodontal tissues and the dynamics of the process.

		N=11.5					N=7.5					N=11.5					
Более 3/4	0	0	0	0	0	0	0	0	0	0	0	0	0	0	0	N=	
3/4	0.5	0.75	0.75	0.45	0.45	0.4	0.25	0.3	0.3	0.25	0.4	0.45	0.45	0.75	0.75	0.5	30.5
1/2	1.0	1.5	1.5	0.9	0.9	0.75	0.5	0.6	0.6	0.5	0.75	0.9	0.9	1.5	1.5	1.0	
1/4	1.5	2.25	2.25	1.3	1.3	1.1	0.75	0.9	0.9	0.75	1.1	1.3	1.3	2.25	2.25	1.5	
N	2.0	3.0	3.0	1.75	1.75	1.5	1.0	1.25	1.25	1.0	1.5	1.75	1.75	3.0	3.0	2.0	
Подвижность																	
Одонтограмма																	
	8	7	6	5	4	3	2	1	1	2	3	4	5	6	7	8	
Одонтограмма																	N=
Подвижность																	30.0
N	2.0	3.0	3.0	1.75	1.75	1.5	1.0	1.0	1.0	1.0	1.5	1.75	1.75	3.0	3.0	2.0	
1/4	1.5	2.25	2.25	1.3	1.3	1.1	0.75	0.75	0.75	0.75	1.1	1.3	1.3	2.25	2.25	1.5	
1/2	1.0	1.5	1.5	0.9	0.9	0.75	0.5	0.5	0.5	0.5	0.75	0.9	0.9	1.5	1.5	1.0	
3/4	0.5	0.75	0.75	0.45	0.45	0.4	0.25	0.25	0.25	0.25	0.4	0.45	0.45	0.75	0.75	0.5	
Более 3/4	0	0	0	0	0	0	0	0	0	0	0	0	0	0	0	0	
	N=11.5					N=7.0					N=11.5						

Changes in the endurance of the tooth supporting apparatus with varying degrees of socket atrophy.

The endurance of the tooth supporting apparatus to load is determined by a gnathodynamometer and is expressed in kg (Weber). With socket atrophy, periodontal endurance

decreases, and the more, the greater the atrophy. Usually, simultaneously with atrophic processes in the tooth socket, significant changes occur in the periodontal receptor apparatus. In this regard, as well as due to the emerging pathological mobility of the tooth caused by atrophy, it is not possible to establish the actual endurance of the periodontium to chewing pressure. Therefore, periodontal endurance to stress during atrophy is calculated using conditional digital coefficients. These coefficients are based on the proportional ratios of periodontal endurance of various teeth to load, which was determined by gnathodynamometry for unaffected periodontal tissue (Weber). The endurance of the “weakest” tooth – the lower incisor – was taken as 1 unit. In practice, it is generally accepted that the periodontium of a tooth is able to withstand a load twice as large as the load during food processing. The coefficient of periodontal endurance to load is correspondingly reduced with different degrees of socket atrophy in different teeth. For example, we can take the first molar, whose endurance coefficient is normally equal to 3 units. If we assume that under physiological conditions, when crushing food, half of the endurance (1.5 units) is used, then, consequently, the supporting apparatus of the tooth retains reserves of 1.5 units, which are partially or completely mobilized at moments of irritation exceeding the average level. As atrophic processes develop, the endurance of the tooth's supporting apparatus decreases and its reserves decrease. If we proceed from the assumption that with different degrees of periodontal atrophy, its endurance decreases in an arithmetic progression (V.Yu. Kurlyandsky), then with degree I atrophy the total endurance is 2.25 units, and the reserves are 0.75 units. With II degree of atrophy, the amount of effort required for crushing food (1.5 units) is equal to the minimum endurance (1.5 units). In this case, there are no reserve forces left, therefore, the supporting apparatus of the tooth is no longer able to respond with an adequate reaction if the irritation during crushing of food turns out to be higher than average values. With grade III atrophy, there is severe functional periodontal insufficiency. Clinical observations show that while maintaining reserve forces in the periodontium, pathological processes in it, characterized by dystrophy, are asymptomatic. After the disappearance of reserve forces, pathological processes are especially acute. In case of IV degree atrophy, the periodontium is not resistant to stress (the tooth must be removed). Fixed prosthetics leads not only to a quantitative change in the dentition, but also to a qualitative restructuring of it. In this regard, deciding on the use of bridges is quite complex, since it is important to create a physiologically balanced system in which both the supporting teeth of the prosthesis and the antagonist teeth would be in conditions of the necessary adaptation. Orthopedic treatment for partial dentition defects is based on the possibility of loading the periodontium of a tooth or group of teeth with dentures within the limits of its (their) maximum endurance due to the existing physiological reserves, as well as contributing to the force balancing of functionally oriented groups of teeth. In addition, it is important to establish a functional power relationship between the dentition with its supporting apparatus and the masticatory muscles with its nerve receptors - the receiver and conductor of internal and external irritations.

The decision on the possibility of using bridges depends on:

- the size of the included defect in the dentition,
- its topography,
- periodontal conditions of supporting teeth,
- state of antagonist teeth.

Based on these data, it can be established, for example, that two supporting teeth can support the body of a prosthesis of three or four teeth if the antagonists are weakened (if their number is small or there is periodontal damage). On the contrary, two supporting teeth with weakened periodontium cannot support a prosthetic body consisting of two teeth. Thus, depending on this information, questions are resolved about the required number of supporting teeth for a bridge and about intervention on antagonist teeth, if there is a small number of these teeth or there is damage to their supporting apparatus. As mentioned above, two supporting teeth, bearing the body of a two-teeth prosthesis, with the participation of all antagonist teeth in chewing, perceive pressure at the limit of their physiological capabilities. By attaching a nearby tooth to the block, better conditions are created

for all blocked teeth. In this case, reserve forces arise in the block, which can be used in the event of increased pressure on the body of the prosthesis. Additional support is also successfully used for the purpose of balancing between groups of antagonizing teeth, if there is any pathology in the periodontium of the supporting teeth of the prosthesis that reduces their resistance to pressure. An increase in the number of supporting teeth of a bridge prosthesis is possible within one functionally oriented group of teeth, or additional support can be taken from another functionally oriented group: for example, a group of biting teeth is included in the block of chewing teeth. At the same time, new functional conditions are created for the teeth that form the block: they are characterized by the fact that, for example, teeth intended for biting food will participate in chewing food or vice versa

SITUATIONAL TASKS

1. Patient K., 32 years old, complained of pain and mobility of teeth 21,26, which support the bridge. During the interview, it was established that the patient was somatically healthy; teeth 22, 23, 24, 25 were removed due to injury. The R-gram in the area of tooth 21 shows resorption of the bone tissue of the socket along 3/4 of its length and expansion of the periodontal gap along the remaining length. In the area of tooth 26 there is resorption of bone tissue by 1/2 the length of the socket and expansion of the periodontal gap. Cause of tooth mobility? Treatment plan.

2. Patient N. consulted a doctor with complaints of pain when biting in the area of the lower jaw bridge on the left. Objectively: the dentition of the upper jaw is preserved, the defect in the dentition of the lower jaw on the left is restored with a bridge-like prosthesis supported by teeth 33 and 37. The supporting crown of tooth 33 is combined according to Belkin, the crown of tooth 37 is all-metal stamped. The gum in the area of tooth 33 is swollen and bleeding, the supporting crown is mobile vertically, which indicates its decementation. After removal of the bridge, complete necrosis of the hard tissues of the crown of tooth 33 is determined. Tooth 37 does not have a hard tissue defect. On the radiograph, the root of tooth 33 is stable, bone tissue atrophy is not noted, and there are periapical changes. Specify the doctor's diagnosis and tactics

3. Patient T. complained of an aesthetic defect in the frontal teeth of the upper jaw and increased sensitivity to temperature stimuli when eating. Objectively: significant loss of hard tissues of teeth 1.1, 1.2, 1.3, 2.1, 2.2, 2.3 of the upper jaw along the vestibular surface with a change in the shape of the crowns. Previously, teeth were repeatedly filled and medicated to relieve hypersensitivity. Determine medical tactics and prosthetic treatment plan for the patient.

4. Patient S. complained of difficulty chewing associated with the absence of some teeth and an aesthetic defect due to changes in the shape of the front teeth. Objectively: included defects in the dentition in the lateral region of the upper and lower jaws, subject to restoration with bridge-like prosthetic structures; orthognathic bite. Make a diagnosis. Determine the medical tactics in the treatment of this pathology and the features of prosthetics.

5. Patient X., 38 years old, came to the clinic with complaints of multiple dental defects. have not previously had prosthetics. Teeth 15,14,11,25 were lost due to complicated caries. The remaining teeth are intact and stable. Make a diagnosis. Determine the medical tactics in the treatment of this pathology and the features of prosthetics.

6. Patient K., 32 years old, complained of pain and mobility of teeth 21,26, which support the bridge. The interview revealed that the patient was somatically healthy. I lost teeth 23 and 24 as a result of injury. Seven years ago, a bridge was made for him based on teeth 22.25, which after 4 years became loose and were removed; a bridge was made for teeth 21.26. After 2 years, he felt a slight mobility of the front tooth, which was constantly increasing. Make a diagnosis. Determine the medical tactics in the treatment of this pathology and the features of prosthetics.

LITERATURE

Basic:

1. Removable Partial Dentures. A Practitioners' Manual / Editor Olcay Şakar. – 2nd Edition. – Springer, 2024. – 423 p.

2. Waliszewski, Michael P. Brudvik's Advanced Removable Partial Dentures. Book of Prosthodontics. – 2nd Edition. – UK : Quintessence Publishing, 2022. – 203 p.

Additional:

3. Complete dentures. Algorithm of producing. / S. A. Naumovich [et al.]. – 3rd ed.– Minsk : BSMU, 2018. – 32 p.

4. Fixed dentures. Algorithm of producing. / S. A. Naumovich [et al.]. – 3rd ed. – Minsk : BSMU, 2018. – 30 p.

5. Removable partial dentures. Algorithm of producing. / S. A. Naumovich [et al.]. – 3rd ed. – Minsk : BSMU, 2018. – 16 p.

Electronic courseware for the educational discipline «Non-removable»

6. <https://etest.bsmu.by/course/view.php?id=1401>

LESSON 4

Subject: Clinical and laboratory stages of manufacturing stamped-soldered bridges.

Total time of class – 5 academic hours (200 min).

№	Stages of a practical class	Time in min.
1.	Organizational stage	10
2.	Control of the initial knowledge level	20
3.	Training stage	40
4.	Practicing a practical skill	90
5.	Monitoring the level of the obtained knowledge or mastery of a practical skill	30
6.	Final stage	10

Purpose of the lesson: To study the clinical-laboratory stages of making stamp-soldered bridge prostheses.

Objectives of the lesson:

1. Master the clinical stages of making stamp-soldered bridge prostheses.
2. Master the laboratory stages of making stamp-soldered bridge prostheses.
3. Learn to select the tools and equipment necessary for making stamp-soldered bridge prostheses.

Class location - the clinical setting.

Practical skills mastered during the class:

Selection of medicine and anesthesia method.

Form of control of the practical class: electronic tests; survey; solving situational tasks.

Place of practical skill implementation – at the outpatient appointment.

Practical skill assessment criteria – according to the assessment sheet (checklist) for monitoring practical skills in the academic discipline in points from 0 to 3.

Requirements for initial level of knowledge:

1. Clinical-laboratory stages of making metal stamp-soldered crowns.
2. Indications and contraindications for making bridge prostheses.
3. Auxiliary materials used for making stamp-soldered bridge prostheses.
4. Equipment and tools used in making bridge prostheses.

Control questions from related disciplines:

1. Alloys of metals used for making stamp-soldered bridge prostheses.
2. Methods of connecting parts of bridge prostheses.
3. Classification of impression materials.
4. Properties of impression materials.
5. Methods of taking impressions.
6. Types of impression trays.

Control questions:

1. General characteristics of stamp-soldered bridge prostheses.
2. Indications, contraindications, structural elements of stamp-soldered bridge prostheses.
3. Clinical stages of making stamp-soldered bridge prostheses.
4. Laboratory stages of making stamp-soldered bridge prostheses.
5. Fitting stamped metal crowns on the abutment teeth of a bridge prosthesis.

Scheme: "Sequence of clinical-laboratory stages of making soldered prostheses".

Clinical stages	Laboratory stages
1. Patient examination, diagnosis. Preparation of abutment teeth for bridge prosthesis, taking working and auxiliary impressions. Determination of central occlusion.	1. Pouring models into an articulator, stamping abutment crowns.
2. Fitting stamped metal crowns on abutment teeth. Taking impressions for the intermediate part of the bridge prosthesis. Registration of central occlusion.	2. Casting models, pouring them into an articulator. Modeling the intermediate part of the bridge prosthesis from wax, casting the intermediate part, soldering it to the abutment crowns. Bleaching. Preliminary processing of the bridge prosthesis.
3. Checking the construction of the stamped-soldered prosthesis	3.1. Final processing, grinding, and polishing of the bridge prosthesis in the case of a solid cast metal intermediate part. 3.2. Final processing, grinding, and polishing of the bridge prosthesis, wax modeling of veneering, replacement of wax with plastic in the case of a combined intermediate part.
4. Application and fixation of the stamped-soldered bridge prosthesis.	

CLINICAL AND LABORATORY STAGES OF MAKING STAMPED-SOLDERED BRIDGE PROSTHESES

The first clinical stage: Collection of complaints and medical history. Dental examination. Radiographic examination. Study of diagnostic models (parallelometry, occlusogram). Diagnosis. Treatment plan. Choice of construction. Preparation of abutment teeth. The amount of prepared tissues depends on the type of artificial crowns. The thickness of the removed tissues for stamped crowns on the chewing surface is 0.3 mm. The clinical neck of the tooth serves as a reference point from the vestibulo-oral and contact sides. The sequence and rules of tooth preparation are the same as when preparing single crowns. The peculiarity of tooth preparation is giving parallelism to all cusps of the abutment teeth according to the path of prosthesis insertion. Attention is paid to creating or preserving the prosthetic plane in the prepared teeth with central jaw relationship or when the teeth are in constructive occlusion. Making impressions. Impressions are taken from both jaws. The working impression should clearly show all anatomical formations of the teeth, especially the clinical neck, the impression of the chewing surface and cutting edges, and the alveolar process in the area of the defect. The auxiliary impression should contain impressions of the cutting edges and chewing surfaces of the dental arch. It is also necessary to take an occlusal relationship record or make lateral fixations.

The first laboratory stage: Models are cast from the obtained impressions and assembled in the position of constructive occlusion. If it is not possible to assemble, it is recommended to use occlusal wax patterns. The models are plastered in an articulator. After the plaster has hardened, the occlusion fixators or occlusal wax rolls are removed, the articulator is opened, and the anatomical shape of the abutment teeth is modeled. Features of wax modeling include incomplete restoration of the anatomical shape with wax (taking into account the thickness of the crown), use of wax without an isolation layer (modeling only crowns, depth of immersion, i.e. length of the crown is determined by the dental technician). Then stamps are made, first gypsum, then metal, and crowns are stamped. The models are destroyed in this process.

Second clinical stage: The preparation of crowns is carried out according to the same principles as the preparation of single crowns. The peculiarity of crown preparation is that all crowns must be strictly parallel to each other, according to the path of prosthesis insertion. Impressions are taken from both jaws after the preparation. The working impression should clearly show all anatomical formations of the prepared crowns, especially the clinical neck and the alveolar process in the area of the defect. The crowns should be present in the impression. The auxiliary impression should contain impressions of the cutting edges and chewing surfaces of the dental arch (it may be preserved after the first clinical stage). It is also necessary to take a new occlusal relationship record with crowns or make lateral fixations. The prepared crowns, strictly parallel to each other.

Second laboratory stage: Models are cast from the obtained impressions and assembled in the position of constructive occlusion. If it is not possible to assemble, it is recommended to use occlusal wax patterns. The production of the intermediate part of the bridge prosthesis should meet biological, mechanical, and aesthetic requirements.

Biological requirements: accessibility for cleaning artificial teeth; access for cleaning abutment teeth; avoiding pressure of the intermediate part on the alveolar process.

Mechanical requirements: absence of deformations under heavy chewing loads, absence of sharp edges and abrupt transitions on the lingual surface.

Aesthetic requirements: the intermediate part of the bridge prosthesis in shape should correspond to the restored teeth, and it should appear to "grow" from the edentulous alveolar process. The intermediate part is modeled with a wax roll, which is made higher and wider than the adjacent teeth. The models are closed in an articulator, and the form of the chewing surface is given according to the antagonist impression. Modeling of the anatomical shape of missing teeth starts with marking the wax roll, then excess wax is removed. To reduce functional load, many resources recommend obtaining narrower chewing surfaces, but this does not reduce chewing pressure, and efficiency is significantly reduced. Therefore, we would advise restoring the anatomical shape of missing teeth completely, except for the neck, where the following options are possible:

- Flush intermediate part: a distance of at least 2 mm between the artificial tooth and the alveolar process. Used in lateral areas of the dental arch. It has good hygienic properties but poor aesthetics.

- Saddle-shaped intermediate part: in this type, the artificial tooth fits closely to the alveolar process. Used in lateral areas of the dental arch in metal-ceramic constructions. It has good aesthetic properties but poor hygiene.

- Tangential intermediate part: in this type, the artificial tooth tangentially fits to the alveolar process. Used in anterior and lateral areas of the dental arch. It has good aesthetic properties and decent hygienic properties.

- Fitting intermediate part: in this type, the artificial tooth fits closely to the alveolar process and is used in the anterior area of the dental arch. The size and topography of the edentulous alveolar process are carefully evaluated when planning treatment with bridge prostheses.

Siebert classified changes in the edentulous alveolar process in the area of the defect into three classes:

- Loss of buccolingual width with preserved alveolar process height;
- Loss of alveolar process height with preserved width;
- Combination of tissue loss in both directions of the alveolar process.

In clinical practice, the third class according to Siebert is most common. After modeling the intermediate part of the bridge prosthesis from wax, the wax is replaced with metal using a generally accepted technique. The intermediate part is soldered to the supporting crowns directly on the model or without it. In the first case, the intermediate part is installed and glued with sticky wax to the contact surfaces of the supporting crowns, using solder (a low-temperature melting metal alloy). The supporting elements are isolated from the flame of the burner. This method is used in the manufacture of gold prostheses. When soldering a stainless steel prosthesis, the intermediate part, installed and

glued in the same way, is carefully removed from the model and separately gypsumed. The feature of soldering stainless steel crowns is the formation of oxides, so a bur is used to remove oxides and protect the surfaces of the soldered elements of the prostheses.

Third clinical stage: Checking the bridge prosthesis construction is an important clinical stage. At this stage, all minor inaccuracies that prevent both the application of the prosthesis and occlusal contact are determined and eliminated. First of all, the prosthesis is evaluated by the doctor outside the oral cavity; the quality of soldering, casting of the intermediate part, finishing, and polishing are checked; the anatomical shape of the intermediate part is evaluated. The prosthesis should fit freely on the supporting teeth with properly fitted crowns and no other errors. After applying the bridge prosthesis, attention is paid primarily to the supporting crowns. They should minimally sink into the gingival sulcus (about 0.2 mm), restore interdental and occlusal contacts, and have an appropriate anatomical shape. When evaluating the intermediate part of the prosthesis, attention is also paid to its anatomical shape and contact with antagonist teeth. The rinsing space is assessed using a probe or dental floss; there should be no sharp transitions and divisions between artificial teeth on the lingual surface of the prosthesis. When checking occlusal contacts, the prosthesis is examined for central, anterior, and lateral relationships. Premature contacts are eliminated on the balancing side, and the working side should have uniform multiple contacts. Fitted bridge prosthesis

Third laboratory stage: The final processing of the prosthesis consists of grinding and polishing, applying decorative titanium nitride coating. Also at this stage, the prosthesis is veneered with plastic or composite material, previously selected to match the color of natural teeth

Fourth clinical stage: If the bridge prosthesis meets all the requirements mentioned above, it is easily applied, has an optimal depth of insertion into the gingival sulcus, multiple contacts with antagonists, etc., then it needs to be temporarily fixed on the supporting teeth for a period of adaptation of 7-10 days. Before cementation, the patient's sensations when using the prosthesis are clarified, mobility is checked, and the level of hygiene is assessed. The rules for cementation correspond to those recommended for single artificial crowns. We recommend using the following algorithm: the bridge prosthesis is cleaned, disinfected, and dried. The material for fixation is measured in the proportion recommended by the manufacturer (usually a combination of powder/liquid - 1/2), typically 3 drops of cement are needed for one crown. Then the supporting teeth are cleaned, disinfected, and dried. The cement mixture is prepared, the crowns are filled 2/3 and fixed on the teeth. When fixing several prostheses, we recommend using cementation of opposing structures, starting with the prosthesis on the lower jaw. After the cement hardens, excess cement is removed using a probe, special attention is paid to removing residues from interdental spaces, for which it is even recommended to schedule the patient for the next day. Recommendations for a two-hour refusal of solid food are related to the complete crystallization of most cements within 2 hours.

SITUATIONAL TASKS

1. Patient A, 52 years old, came to the clinic complaining of missing teeth 25, 26, 34, 35, 36 and associated chewing problems. Make a diagnosis. What type of intermediate part of the bridge prosthesis will be used in the area of missing teeth in the case of stamp-soldered prostheses?

2. Patient K, 47 years old, came to the clinic complaining of pain under the intermediate part of the bridge prosthesis. From the history: 2 months ago, the patient had a stamp-soldered bridge prosthesis made for the upper jaw supported by teeth 23, 24, 28. Upon examination of the oral cavity, it was found that the solid intermediate part of the bridge prosthesis is closely fitting to the alveolar ridge in the area of missing teeth 26, 27, the gums are swollen, hypertrophied, and painful upon palpation. Specify the possible cause of the patient's complaints, what additional research methods need to be carried out? Your tactics for managing complications.

3. Patient L, 63 years old, after examination and agreement, a treatment plan was developed, which involves making stamp-soldered bridge prostheses for the upper jaw supported by teeth 17, 14 and for the lower jaw supported by teeth 33, 35, 38. All remaining teeth are intact. Make a diagnosis. Describe the sequence of clinical and laboratory stages.

4. Indicate which impression materials can be used at each of the clinical and laboratory stages of making stamp-soldered bridge prostheses?

5. Patient S, 52 years old, came to the clinic complaining of missing teeth 15, 16, 45, 46 and associated chewing problems. Make a diagnosis? Develop a treatment plan?

6. Patient B, 69 years old, came to the clinic complaining of missing teeth 14, 15, 44, 45, 47 and associated chewing problems. Make a diagnosis. What type of intermediate part of the bridge prosthesis will be used in the area of missing teeth in the case of stamp-soldered prostheses?

LITERATURE

Basic:

1. Removable Partial Dentures. A Practitioners' Manual / Editor Olcay Şakar. – 2nd Edition. – Springer, 2024. – 423 p.

2. Waliszewski, Michael P. Brudvik's Advanced Removable Partial Dentures. Book of Prosthodontics. – 2nd Edition. – UK : Quintessence Publishing, 2022. – 203 p.

Additional:

3. Complete dentures. Algorithm of producing. / S. A. Naumovich [et al.]. – 3rd ed.– Minsk : BSMU, 2018. – 32 p.

4. Fixed dentures. Algorithm of producing. / S. A. Naumovich [et al.]. – 3rd ed. – Minsk : BSMU, 2018. – 30 p.

5. Removable partial dentures. Algorithm of producing. / S. A. Naumovich [et al.]. – 3rd ed. – Minsk : BSMU, 2018. – 16 p.

Electronic courseware for the educational discipline «Non-removable»

6. <https://etest.bsmu.by/course/view.php?id=1401>

LESSON 5

Subject: Preparation of teeth, taking impressions in the manufacture of bridge dentures (stamped-soldered, cast-metal, combined).

Total time of class – 5 academic hours (200 min).

№	Stages of a practical class	Time in min.
1.	Organizational stage	10
2.	Control of the initial knowledge level	20
3.	Training stage	40
4.	Practicing a practical skill	90
5.	Monitoring the level of the obtained knowledge or mastery of a practical skill	30
6.	Final stage	10

Purpose of the lesson: to teach students the features of preparing hard tooth tissues when replacing defects in dental rows with various constructions of bridge prostheses and methods of taking impressions.

Objectives of the lesson:

1. Learn to prepare teeth for various types of orthopedic constructions.
2. Consolidate knowledge about impression materials.
3. Consolidate knowledge about impression trays and methods of their selection.
4. Consolidate practical skills in taking impressions.
5. Consolidate skills in preparing teeth for the manufacture of bridge prostheses on phantoms.

Class location - the clinical setting.

Practical skills mastered during the class:

Taking alginate impressions.

Form of control of the practical class: electronic tests; survey; solving situational tasks.

Place of practical skill implementation – at the outpatient appointment.

Practical skill assessment criteria – according to the assessment sheet (checklist) for monitoring practical skills in the academic discipline in points from 0 to 3.

Requirements for the initial level of knowledge:

1. Selection of impression trays.
2. Safety zones according to Gavrilov.
3. Understanding of occlusion, articulation, and bite.
4. Sequence of clinical-laboratory stages of manufacturing bridge prostheses.

Control questions from related disciplines:

1. Abrasive instruments, classification, indications for use.
2. Impression materials, classification, indications for use.
3. Types of impressions, methods of obtaining different types of impressions and criteria for evaluating their quality.
4. Types of dental handpieces for preparing hard tooth tissues.
5. Preparation of the oral cavity for prosthetics.

Control questions:

1. Preparation of hard tissues of abutment teeth in the manufacture of stamped-soldered bridge prostheses.
2. Preparation of hard tissues of abutment teeth in the manufacture of solid cast bridge prostheses.
3. Preparation of hard tissues of abutment teeth in the manufacture of combined (metal-ceramic and metal-acrylic) bridge prostheses.
4. Justification of the choice of impression material for the manufacture of bridge prostheses.
5. Method of taking impressions.
6. Criteria for evaluating the quality of impressions when manufacturing different types of bridge prosthesis.

Scheme "Methodology of preparing abutment teeth for various types of bridge prostheses"

Type of bridge prosthesis	Criteria for preparing abutment teeth	General criterion for all bridge prostheses	Working impression
Stamped-soldered	The prepared tooth for a metal stamped crown should have a cylindrical shape. The diameter of the abutment should not be wider than the diameter of the tooth neck. The wire loop should pass freely from the crown apex to the tooth neck. The abutment surface should be smooth. The crown of the tooth should be separated in occlusion by 0.25-0.35 mm.	Parallelism or slight convergence of abutment teeth	Alginate materials C-silicone
Solid cast	The occlusal surface is prepared by 0.6-1.2 mm, all other surfaces are prepared to create a groove or a groove width of up to 0.5 mm in the gingival area. The abutment should have a truncated cone shape. The abutment surface should not have sharp edges or corners.		1. Two-layer: - one-step; - two-step. 2. Single-layer By material: 1. Silicone (A and C type) 2. Polyether 3. Polysulfide
Metal-ceramic, metal-acrylic, non-metallic	Metal-ceramic, metal-acrylic, non-metallic. The occlusal surface is prepared by 1.5-2.0 mm, all other surfaces are prepared to create a groove width of up to 1.2 mm in the gingival area. The abutment should have a truncated cone shape. The abutment surface should not have sharp edges or corners.		1. Two-layer: - one-step; - two-step. 2. Single-layer By material: 1. Silicone (A and C type) 2. Polyether 3. Polysulfide.

The method of obtaining an impression may vary depending on the number of spoon insertions with impression material into the patient's mouth, the amount of impression materials used (number of layers of materials of different viscosities within one group), and the representation of the jaws (single-jaw and double-jaw impressions). Depending on the stages, single-stage and two-stage impressions are distinguished. In a single-stage impression, the spoon with the impression material is applied to the prosthetic tissues only once. The essence of two-stage impressions is that the impression is obtained sequentially: first with the base impression material, then after its hardening, the impression is removed from the mouth, corrective material is added to refine the details of the prosthetic bed, and the spoon is reapplied. If one type of impression material is used in obtaining the impression, such impressions are commonly referred to as single-layer impressions. Methods of obtaining impressions using two types of viscosity of impression materials are also known and widely used in dentistry. Such impressions are called two-layer impressions.

Impression assessment

After removing the impression from the mouth, it is evaluated according to the following criteria:

- clear representation of all teeth, gingival grooves, alveolar processes, and surrounding soft tissues up to the transitional fold;
- absence of pores in the impression;
- good adaptation of the impression material to the spoon;
- absence of thin or compressed areas on the inner surface of the impression;
- absence of saliva and traces of blood on the impression.

SITUATIONAL TASKS

1. A 25-year-old female patient presented with complaints of aesthetic issues with the front teeth of the upper jaw. Upon examination, teeth 12, 11, 21, 22 have extensive fillings with marginal adaptation issues and changes in color. Percussion of tooth 12 is painful, and a sinus tract is identified in the area of its root apex. X-ray examination shows that teeth 11 and 21 are non-vital, with the canals being tightly filled all the way to the apex, with no periapical changes. The root canal of tooth 12 is filled one-third of the way, with a focus of bone tissue destruction with unclear contours at the apex of the root. Tooth 22 has not undergone endodontic treatment, and there are no periapical changes. Provide a diagnosis and treatment plan.

2. A 40-year-old patient was recommended to restore the dental arch defect after the extraction of teeth 35 and 36 with a metal-ceramic bridge supported by teeth 34 and 37. Specify the amount of hard tissue preparation needed for the supporting teeth. What type of impressions and impression materials are needed for the upper and lower dental arches?

3. A 36-year-old female patient underwent preparation of teeth 44 and 47 by a dentist for the fabrication of a metal-acrylic bridge prosthesis to replace the missing teeth 45 and 46. Upon a follow-up examination, overhanging edges are visually identified on the vestibular surface of teeth 44 and 47, with tooth 44 being prepared with a circular groove and tooth 47 without a groove. The axes of the teeth significantly diverge, and there is separation with antagonist teeth in centric occlusion. Evaluate the quality of tooth preparation, identify any deficiencies that need to be corrected, and specify the type of impression and material needed after correcting the errors.

4. A 36-year-old female patient presented to the clinic with complaints of missing teeth 12 and 14. Upon examination, teeth 15 and 13 are intact, and percussion is painless. A composite filling is present on the distal surface of tooth 11. Provide a diagnosis, specify additional diagnostic methods needed, develop a treatment plan, and determine the amount of hard tissue preparation for supporting teeth based on the type of bridge prosthesis.

5. A 37-year-old patient was recommended to restore the dental arch defect after the extraction of tooth 35 with a non-metallic bridge prosthesis supported by teeth 34 and 36. Specify the amount of hard tissue preparation needed for the supporting teeth and indicate the type of impressions and impression materials needed for the upper and lower dental arches.

6. For patient L., 63 years old, after examination and agreement, a treatment plan was developed involving the fabrication of stamped-soldered bridge prostheses for the upper jaw supported by teeth 17, 14, and for the lower jaw supported by teeth 33, 35, 38. All remaining teeth are intact. Provide a diagnosis and outline the sequence of clinical-laboratory stages.

LITERATURE

Basic:

1. Removable Partial Dentures. A Practitioners' Manual / Editor Olcay Şakar. – 2nd Edition. – Springer, 2024. – 423 p.
2. Waliszewski, Michael P. Brudvik's Advanced Removable Partial Dentures. Book of Prosthodontics. – 2nd Edition. – UK : Quintessence Publishing, 2022. – 203 p.

Additional:

3. Complete dentures. Algorithm of producing. / S. A. Naumovich [et al.]. – 3rd ed.– Minsk : BSMU, 2018. – 32 p.
 4. Fixed dentures. Algorithm of producing. / S. A. Naumovich [et al.]. – 3rd ed. – Minsk : BSMU, 2018. – 30 p.
 5. Removable partial dentures. Algorithm of producing. / S. A. Naumovich [et al.]. – 3rd ed. – Minsk : BSMU, 2018. – 16 p.
- Electronic courseware for the educational discipline «Non-removable»
6. <https://etest.bsmu.by/course/view.php?id=1401>

CLASS 6

Subject: The technique of taking impressions for the manufacture of the intermediate part of the bridge dentures. The choice of impression materials depending on the construction materials of the dentures.

Total time of class – 5 academic hours (200 min).

№	Stages of a practical class	Time in min.
1.	Organizational stage	10
2.	Control of the initial knowledge level	20
3.	Training stage	40
4.	Practicing a practical skill	90
5.	Monitoring the level of the obtained knowledge or mastery of a practical skill	30
6.	Final stage	10

Purpose of the lesson: To study and master the methodology for obtaining impressions for the production of the intermediate part of bridge-like prostheses as a clinical stage of prosthetics with soldered-stamped bridge-like prostheses. To teach students the proper selection of impression materials for conducting the current stage of patient treatment.

Objectives of the lesson:

1. Consolidate knowledge of fitting and applying stamped crowns in the production of stamped-soldered bridge-like prostheses.
2. Systematize knowledge about the peculiarities of preparing the patient for impression taking and selecting impression materials for the production of the intermediate part.
3. Consolidate knowledge of the technique of taking impressions for the production of the intermediate part of bridge-like prostheses.
4. Acquire practical skills in taking impressions for the production of the intermediate part of bridge-like prostheses.
5. Teach students to analyze the quality of the obtained impression for the production of the intermediate part of bridge-like prostheses.
6. Consolidate skills in obtaining impressions from alginate and silicone materials.

Class location - the clinical setting.

Practical skills mastered during the class:

Taking dual-layer silicone impressions.

Form of control of the practical class: electronic tests; survey; solving situational tasks.

Place of practical skill implementation – at the outpatient appointment.

Practical skill assessment criteria – according to the assessment sheet (checklist) for monitoring practical skills in the academic discipline in points from 0 to 3.

Requirements for the initial level of knowledge:

1. Clinical-laboratory stages of manufacturing a metal stamped crown.
2. Indications and contraindications for the production of bridge-like prostheses.
3. Alloys of metals used in the production of stamped-soldered bridge-like prostheses.
4. Auxiliary materials used in the production of stamped-soldered bridge-like prostheses.
5. Equipment and tools used in the production of bridge-like prostheses.
6. Methods of connecting parts of bridge-like prostheses.

Control questions from related disciplines:

1. Anatomical structure of teeth.
2. Types of alloys used in orthopedic dentistry.
3. Histological structure of the oral mucosa.
4. Functional and morphological changes occurring in the dental system with partial tooth loss.
5. Preparation of the oral cavity for prosthesis.

Control questions:

1. General characteristics of stamped-soldered bridge-like prostheses. Indications, contraindications, structural elements.
2. Clinical-laboratory stages of manufacturing stamped-soldered bridge-like prostheses.
3. Fitting stamped metal crowns on abutment teeth of a bridge-like prosthesis.
4. Impression materials used for taking impressions for the production of the intermediate part of bridge-like prostheses.
5. Technique for taking impressions for the production of the intermediate part of soldered-stamped bridge-like prosthesis.
6. Modeling the intermediate part of a bridge-like prosthesis, replacing wax with metal, soldering abutment crowns and the intermediate part.

Scheme: "Sequence of clinical and laboratory stages of manufacturing soldered bridges"

Clinical stages	Laboratory stages
1. Examination of the patient, diagnosis. Preparation of abutment teeth for the bridge prosthesis, taking working and auxiliary impressions. Determination of central occlusion.	1. Plastering of models in an articulator, Stamping of abutment crowns.
2. Fitting stamped metal crowns on abutment teeth. Taking impressions for the manufacture of the intermediate part of the bridge prosthesis. Registration of central occlusion.	2. Casting of models, plastering them in an articulator. Modeling the intermediate part of the bridge prosthesis from wax, casting the intermediate part, soldering to abutment crowns. Bleaching. Preliminary processing of the bridge prosthesis.
3. Checking the construction of the stamped-soldered prosthesis.	3.1. Final processing, grinding and polishing of the bridge prosthesis in case of a solid-cast metal intermediate part. 3.2. Final processing, grinding and polishing of the bridge prosthesis, modeling of wax facing, replacement of wax with plastic in case of a combined intermediate part.
4. Application and fixation of the stamped-soldered bridge prosthesis.	

The impressions after fitting are taken from both jaws. The working impression should clearly show all anatomical formations of the fitted crowns, especially the clinical neck and alveolar process in the area of the defect. The crowns should be present in the impression. The auxiliary impression should contain imprints of the cutting edges and chewing surfaces of the dental arch (it can be preserved after the first clinical stage). It is also necessary to take a new occlusal registration of the relationship between the dental arches with crowns or make lateral fixations. The fitted crowns, strictly parallel to each other.

Models are cast from the obtained impressions and positioned in the constructive bite. If it is impossible to position, it is recommended to use occlusal wax patterns. The manufacture of the intermediate part of the bridge prosthesis should meet biological, mechanical, and aesthetic requirements.

Biological: the possibility of access for cleaning artificial teeth; access for cleaning supporting teeth; avoiding pressure of the intermediate part on the alveolar process.

Mechanical: absence of deformations under strong chewing loads, absence of sharp edges and sharp transitions on the lingual surface.

Aesthetic: the intermediate part of the bridge prosthesis in shape should correspond to the restored teeth, the intermediate part should "grow out" from the edentulous alveolar process. The intermediate part is modeled with a wax roll, which is made higher and wider than the adjacent teeth. The models are closed in an articulator, and the form of the chewing surface is given according to the antagonist's imprint. The modeling of the anatomical form of missing teeth starts with marking the wax roll, then excess wax is removed. To reduce functional load in many manuals, it is recommended to obtain narrower chewing surfaces, but chewing pressure is not reduced, and efficiency is greatly reduced, so we would advise restoring the anatomical shape of missing teeth completely, except for the neck, where the following options are possible:

- Rinsing intermediate part. In this form, the distance between the artificial tooth and the alveolar process is not less than 2 mm. It is used in the lateral sections of the dental arch. It has good hygienic properties but poor aesthetics.

- Saddle-shaped intermediate part. In this form of the intermediate part, the artificial tooth fits tightly to the alveolar process. It is used in the lateral sections of the dental arch in metal-ceramic structures. It has good aesthetic properties but poor hygiene.

- Tangential intermediate part. In this form of the intermediate part, the artificial tooth tangentially fits to the alveolar process. It is used in the anterior and lateral sections of the dental arch. It has good aesthetic properties and decent hygienic properties.

- Adjacent intermediate part. In this form of the intermediate part, the artificial tooth fits tightly to the alveolar process and is used in the anterior section of the dental arch. The size and topography of the edentulous alveolar process are carefully assessed when planning treatment with bridge prostheses.

Siebert classified changes in the edentulous alveolar process in the area of defect into three classes:

- Buccolingual loss of width with preserved height of alveolar process;
- Loss of height of alveolar process with preserved width;
- Combination of tissue loss of alveolar process in both directions.

In clinical practice, the most common is the 3rd class according to Siebert. After modeling the intermediate part of the bridge prosthesis from wax, it is replaced with metal using the generally accepted technique. The intermediate part is soldered to the supporting crowns directly on the model or without it. In the first case, the intermediate part is installed and glued with sticky wax to the contact surfaces of the supporting crowns, using solder (a bonding related metal alloy with a low melting temperature). The supporting elements are isolated from the flame of the burner during this process. This method is used in the manufacture of gold prostheses. When soldering a stainless steel prosthesis, the intermediate part, installed and glued in the same way, is carefully removed from the model and separately gypsumed. The peculiarity of soldering metal crowns from stainless steel is the

formation of oxides, so a burr is used to remove oxides and protect the surfaces of the soldered prosthesis elements.

SITUATIONAL TASKS

1. Patient A, 52 years old, came to the clinic complaining of missing teeth 25, 26, 34, 35, 36 and associated chewing problems.

Diagnose the patient. What type of intermediate part of the bridge prosthesis will be used in the area of missing teeth in case of making stamped-soldered prostheses?

2. Patient K, 47 years old, came to the clinic complaining of pain under the intermediate part of the bridge prosthesis. From the history: 2 months ago, a stamped-soldered bridge prosthesis was made for the upper jaw with support on teeth 23, 24, 28. Upon examination of the oral cavity, it was found that the solid intermediate part of the bridge prosthesis fits tightly to the alveolar ridge in the area of missing teeth 26, 27, the gums are swollen, hypertrophied, and painful on palpation.

Indicate a possible cause of the patient's complaints, what additional research methods need to be carried out? Your tactics for eliminating complications.

3. Specify which impression materials can be used at each of the clinical-laboratory stages of making stamped-soldered bridge prostheses?

4. Patient C, 52 years old, came to the clinic complaining of missing teeth 15, 16, 45, 46 and associated chewing problems. Diagnose the patient? Develop a treatment plan?

5. Patient L, 63 years old after examination and agreement, a treatment plan was developed, which includes making stamped-soldered bridge prostheses for the upper jaw with support on teeth 17, 14 and for the lower jaw with support on teeth 33, 35, 38. All remaining teeth are intact.

Diagnose the patient. Describe the sequence of clinical-laboratory stages.

6. To take an impression for making the intermediate part of the bridge prosthesis, the doctor chose alginate impression material. Point out the mistakes made by the doctor? Methods for correction?

LITERATURE

Basic:

1. Removable Partial Dentures. A Practitioners' Manual / Editor Olcay Şakar. – 2nd Edition. – Springer, 2024. – 423 p.

2. Waliszewski, Michael P. Brudvik's Advanced Removable Partial Dentures. Book of Prosthodontics. – 2nd Edition. – UK : Quintessence Publishing, 2022. – 203 p.

Additional:

3. Complete dentures. Algorithm of producing. / S. A. Naumovich [et al.]. – 3rd ed. – Minsk : BSMU, 2018. – 32 p.

4. Fixed dentures. Algorithm of producing. / S. A. Naumovich [et al.]. – 3rd ed. – Minsk : BSMU, 2018. – 30 p.

5. Removable partial dentures. Algorithm of producing. / S. A. Naumovich [et al.]. – 3rd ed. – Minsk : BSMU, 2018. – 16 p.

Electronic courseware for the educational discipline «Non-removable»

6. <https://etest.bsmu.by/course/view.php?id=1401>

CLASS 7

Subject: Determination and methods of fixation of central occlusion in the manufacture of bridges.

Total time of class – 5 academic hours (200 min).

№	Stages of a practical class	Time in min.
1.	Organizational stage	10
2.	Control of the initial knowledge level	20
3.	Training stage	40
4.	Practicing a practical skill	90
5.	Monitoring the level of the obtained knowledge or mastery of a practical skill	30
6.	Final stage	10

Purpose of the lesson: to teach students to determine central occlusion and fix it using various methods when partial tooth loss with bridge prostheses.

Objectives of the lesson:

1. Learn to choose the method of determining and fixing central occlusion depending on the clinical picture.
2. Master practical skills in determining and fixing the position of central occlusion using various methods.
3. Learn to analyze and control the determination of central occlusion in the production of bridge prostheses on phantoms.

Class location - the clinical setting.

Practical skills mastered during the class:

Determining and fixing habitual occlusion when making bridgework prostheses.

Form of control of the practical class: electronic tests; survey; solving situational tasks.

Place of practical skill implementation – at the outpatient appointment.

Practical skill assessment criteria – according to the assessment sheet (checklist) for monitoring practical skills in the academic discipline in points from 0 to 3.

Requirements for initial level of knowledge:

1. Biomechanics of the lower jaw.
2. Understanding of occlusion, articulation, and bite.
3. Types of occlusion, signs of central occlusion.
4. Clinical symptoms of partial tooth loss.
5. Classification of dental arch defects (according to Kennedy, Gavrilov).

Control questions from related disciplines:

1. Anatomical structure of teeth.
2. Types of auxiliary materials used in orthopedic dentistry.
3. Histological structure of the oral mucosa.
4. Functional and morphological changes occurring in the dentofacial system with partial tooth loss.
5. Preparation of the oral cavity for prosthetics.

Control questions:

1. Understanding of the position of central occlusion and central relationship.
2. Signs of central occlusion in intact dental arches and orthognathic bite.
3. Variants of dental arch defects, differing in methods of determining and fixing central occlusion.
4. Methods of determining and fixing central occlusion.
5. Materials needed for fixing central occlusion in case of partial tooth loss. Impression materials for occlusion registration.
6. Errors in determining central occlusion and methods for their correction.

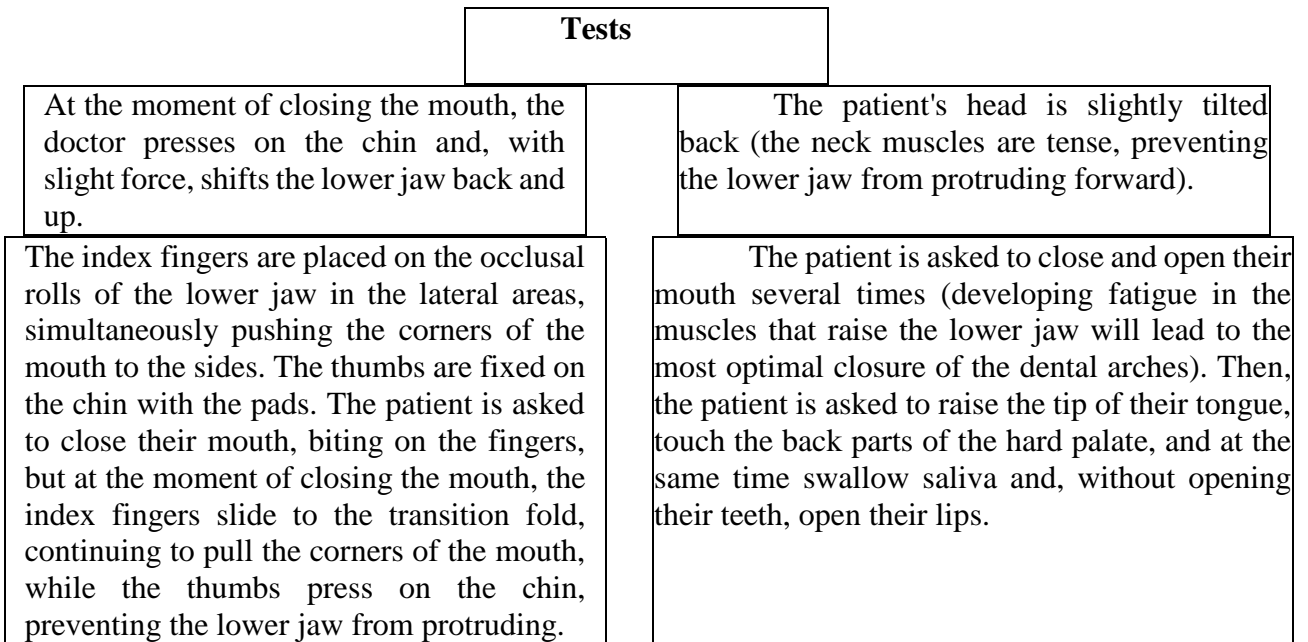
Scheme: "Fixation of central occlusion".

Variants of the location of antagonist teeth in case of partial tooth loss	Technical equipment	Procedure
Variant 1: Antagonists are located on the right and left halves of the jaw and in the front section.	Medical instruments, cup with hot and cold water, wax, impression materials for occlusion registration	<p>1. Fixation of central occlusion with a base wax plate. A roll of wax is formed from the wax plate, 4-6 cm long and 1 cm thick. It is heated in hot water and placed between the dental arches in the area of the defect. The patient is asked to close their dental arches, checking the correctness of the closure. The roll creates impressions of the antagonistic teeth. The roll is removed from the oral cavity, cooled in water, and handed over to the technician, who sets it on one of the models and attaches the other, achieving an accurate relationship of the dental arches.</p> <p>2. Fixation of central occlusion with impression materials for occlusion registration Impression material for occlusion registration is mixed according to the instructions and applied to the occlusal surfaces of the teeth, as well as in the area of the dental arch defect. The patient is asked to close their dental arches in the central occlusion position and not open their mouth until the material is fully polymerized, controlling the correctness of closure. Then the occlusal registrars are removed from the oral cavity and handed over to the dental technician for making jaw models.</p>

<p>Variant 2: There is one or two areas of antagonist teeth (fixed interalveolar height).</p>	<p>Medical instruments, alcohol lamp, base with occlusal rolls, impression materials for occlusion registration.</p>	<p>1. Fixation of central occlusion with wax bases with occlusal rolls. The bases with occlusal rolls are adjusted in the oral cavity in such a way that when they are closed, there is a separation of the remaining antagonist pairs of teeth by 1-2 mm. Then the occlusal rolls are heated with a scalpel to a depth of 4-5 mm, and the base with heated rolls is placed in the oral cavity on the jaw, and the patient is asked to close their teeth, checking the correctness of closure. Impressions of antagonist teeth are obtained on the occlusal rolls with fixation of interalveolar height on existing antagonist pairs. The base is removed from the oral cavity, cooled in water, and handed over to the technician, who sets it on the models.</p> <p>2. Fixation of central occlusion with impression materials for occlusion registration Fixation of central occlusion is carried out using the same scheme as in Variant 1. The only difference is that it is necessary to apply a larger amount of impression material in the area of dental arch defects to completely fill the interalveolar space when the dental arches are closed.</p>
<p>Variant 3: No antagonist tooth pairs (unfixed interalveolar height)</p>	<p>Medical instruments, alcohol lamp, base with occlusal rolls.</p>	<p>Determine the height of the lower third of the face in a state of physiological rest. Mark this value on a wax plate, insert a wax base with occlusal rolls into the oral cavity, and ask the patient to close their mouth. Measure the height of the lower third of the face and, if it turns out to be greater than the height of physiological rest, cut the wax from the rolls. If the height is less by 2-4 mm, then add wax to the rolls. This is done to ensure that the height of the lower third of the face is 2-4 mm less than the height of physiological rest, and there is a tight occlusal contact between the rolls. Then, thin strips of wax 1-2 mm thick are only added to the rolls in areas where they come into contact with natural teeth and heated with a spatula to the same thickness. In areas where the rolls come into contact with each other, cross-cuts are made on one of the rolls with a spatula, and a thin wax plate is added to the opposite roll and softened to the full thickness. The wax bases are inserted into the oral cavity and the patient is asked to close their teeth, checking the central relationship of the jaws. Impressions of occlusal surfaces of the teeth are obtained in areas where the rolls come into contact with teeth, and wax</p>

		fills the cross-cuts in areas where the rolls come into contact, creating locks. Excess wax is pressed out from under the rolls. The wax bases with occlusal rolls are removed from the oral cavity, cooled with water, rechecked for the correctness of determining the central relationship, and handed over to the technician.
--	--	---

Scheme: "Tests for fixing central occlusion"



SITUATIONAL TASKS

1. Patient E., 34 years old, came to the clinic complaining of difficulty chewing food due to the absence of lateral teeth in the upper and lower jaws. From the history, it was found that teeth 16, 25, 26, 36, 35, 45, 46 were removed due to complications of caries over the past 7 years. Previously not prosthetized. The bite is orthognathic. Teeth 15, 24, 34, 44, 47 are intact, percussion is painless, mobility is within the physiological norm. Teeth 27, 37, 17 have class II Black amalgam fillings, stable, percussion of the teeth is painless.

Diagnose the patient. Propose possible orthopedic treatment options and methods of fixing the jaws in the position of central occlusion.

2. A 47-year-old female patient presented with complaints of difficulty chewing food, aesthetic deficiency, and pain in the temporomandibular joint area. From the history: teeth were removed due to complicated caries 12 years ago, pain in the joint area has been more intense over the past six months. Objective: in teeth 11, 21, 37, fillings are in satisfactory condition, crater-like depressions are present on the lower jaw teeth up to the enamel-dentin border level, the height of the lower face is reduced by 6 mm compared to the state of physiological rest. Make a diagnosis considering Kennedy's classification. Develop a treatment plan.

3. Patient A., 52 years old, came to the clinic complaining of the absence of teeth in the upper and lower jaws. Teeth 14, 21, 27, 33, 34, 48 are preserved in the oral cavity.

Diagnose according to Kennedy's classification. Is it advisable to make a bridge-like prosthesis for the upper jaw? What additional research methods need to be conducted to develop a treatment plan? How should central occlusion be fixed in this clinical situation?

4. Patient B., 37 years old. Complaints of missing molar teeth 15, 16, 17, 18 in the upper jaw, difficulty chewing food and unilateral chewing. Objective: tooth 14 is stable, there is a filling on the proximal surface, percussion is painless.

Make a diagnosis. Develop a treatment plan. Will this patient experience a decrease in the height of the lower face? Indicate possible options for fixing central occlusion.

5. Patient L., 48 years old. During the fitting of a metal-ceramic bridge prosthesis with support on teeth 13, 15, 18 in the articulator, the absence of fissure-cusp contact on the left side of the upper and lower jaws is determined, and there is "flush" contact on the frontal teeth. Specify possible errors in previous clinical and laboratory stages that led to the incorrect position of gypsum models in the articulator. Your tactics for correcting mistakes.

6. When determining the position of central occlusion in a patient, the nasolabial and chin folds are smoothed out. What mistakes were made? Methods for their elimination?

LITERATURE

Basic:

1. Removable Partial Dentures. A Practitioners' Manual / Editor Olcay Şakar. – 2nd Edition. – Springer, 2024. – 423 p.

2. Waliszewski, Michael P. Brudvik's Advanced Removable Partial Dentures. Book of Prosthodontics. – 2nd Edition. – UK : Quintessence Publishing, 2022. – 203 p.

Additional:

3. Complete dentures. Algorithm of producing. / S. A. Naumovich [et al.]. – 3rd ed. – Minsk : BSMU, 2018. – 32 p.

4. Fixed dentures. Algorithm of producing. / S. A. Naumovich [et al.]. – 3rd ed. – Minsk : BSMU, 2018. – 30 p.

5. Removable partial dentures. Algorithm of producing. / S. A. Naumovich [et al.]. – 3rd ed. – Minsk : BSMU, 2018. – 16 p.

Electronic courseware for the educational discipline «Non-removable»

6. <https://etest.bsmu.by/course/view.php?id=1401>

CLASS 8

Subject: Inspection of structures, final manufacture, application and fixation of bridge dentures.

Total time of class – 5 academic hours (200 min).

№	Stages of a practical class	Time in min.
1.	Organizational stage	10
2.	Control of the initial knowledge level	20
3.	Training stage	40
4.	Practicing a practical skill	90
5.	Monitoring the level of the obtained knowledge or mastery of a practical skill	30
6.	Final stage	10

Purpose of the lesson: To learn students to evaluate the quality of manufacturing of bridges, to correctly fit and fix them in the oral cavity.

Objectives of the lesson:

1. Learn to assess the quality of manufacturing of fixed dentures.
2. Master practical skills in fitting and checking the design of fixed dentures.
3. Learn to choose a fixing material and fix fixed dentures.

Class location - the clinical setting.

Practical skills mastered during the class:

Checking the construction of metal bridgework prostheses.

Form of control of the practical class: electronic tests; survey; solving situational tasks.

Place of practical skill implementation – at the outpatient appointment.

Practical skill assessment criteria – according to the assessment sheet (checklist) for monitoring practical skills in the academic discipline in points from 0 to 3.

Requirements for initial level of knowledge:

1. Sequence of clinical and laboratory stages of manufacturing of fixed dentures.
2. Basic and auxiliary materials used for the manufacture of fixed dentures.
3. Equipment and tools used in the manufacture of fixed dentures.
4. Anatomical shape of tooth crowns.

Control questions from related disciplines:

1. Anatomical structure of teeth.
2. Types of fixing materials used for fixed prosthetics in orthopedic dentistry.
3. Histological structure of the oral mucosa.
4. Functional and morphological changes occurring in the dentoalveolar system with partial loss of teeth
5. Preparing the oral cavity for prosthetics.

Control questions:

1. Criteria for assessing the quality of manufacturing a fixed dentures.
2. Stages of checking the design of the fixed dentures.
3. Types of the intermediate part of the fixed dentures and the requirements for it.

4. Possible errors made in the manufacture of fixed dentures and methods for eliminating them.
5. Rules for fixing of a fixed dentures.
6. Possible errors made at the stage of fixing fixed dentures and methods for eliminating them.

Scheme: Assessment of the quality of bridge prosthesis manufacturing

Assessing the quality of a bridge:	<ol style="list-style-type: none"> 1. The quality of manufacturing of the abutment crowns (no defects, anatomical shape, parallel arrangement of all abutment crowns). 2. Correct modeling of the intermediate part. 3. Quality of casting of the intermediate part. 4. The quality of adhesion of the intermediate part to the supporting elements of the prosthesis. 5. Quality of cladding. 6. Quality of processing and polishing of the prosthesis.
Checking the bridge design:	<ol style="list-style-type: none"> 1. The prosthesis must be applied to the supporting teeth. 2. Abutment crowns should tightly cover the necks of the abutment teeth. 3. The prosthesis should not interfere with the closure of teeth in all types of occlusion.
Requirements for the intermediate part of the bridge:	<ol style="list-style-type: none"> 1. Should touch the mucous membrane of the alveolar process in the anterior section or have a washing space in the lateral sections. 2. Should not have pronounced tubercles near the chewing teeth. 3. Should not have sharp corners. 4. Must have a smooth, polished surface. 5. Must be firmly connected to the abutment crowns.

Checking the design of a solid metal bridge frame.

Checking the solid metal frame of a prosthesis in the clinic should begin with a visual assessment of the quality of the casting and its processing by a dental technician. The frame should not have pores, sagging, defects, underfilling, and should be easily applied to and removed from the plaster model.

After checking, the metal frame is tried on the patient's supporting teeth. The frame should be placed freely, without tension, on the supporting teeth and from all sides (vestibular, oral, mesial, distal) reach the level specified by the doctor, i.e. to the gum or the middle of the gingival groove.

If the supporting crown(s) in any area does not reach the required level (ledge) or the frame is balancing, you should check whether the frame is seated on the supporting teeth. This can be done visually, using carbon paper or using a small portion of corrective impression material. In areas that interfere with the seating of crowns, the impression material will be pressed through. In this way, deficiencies in the preparation of abutment teeth or technical casting errors are identified. In addition, you should examine the mucous membrane of the gums: its pallor indicates elongated borders.

If the frame is lined with ceramics or plastic, then the interocclusal distance between the frame and the antagonist teeth is determined; it must correspond to the thickness of the porcelain lining (1.2 mm). If the prosthesis is without lining, then the occlusal contacts are verified. In addition, the relationship between the metal intermediate part of the prosthesis and the mucous membrane of the alveolar process is clarified. There should be a gap of 1.5–2 mm between them. At this clinical stage, the color of the ceramic veneer of the prosthesis is determined in natural light. It is advisable to do this together with the dental technician and taking into account the wishes of the patient.

Checking the design of a metal frame with ceramic lining

When fitting a solid-cast frame with ceramic lining, you need to pay attention to:

- ease of application of the prosthesis to the supporting teeth;
- aesthetic qualities of the prosthesis (color of porcelain lining, shape of crowns and facets);
- accuracy of crown boundaries in the cervical zone;
- the relationship between the intermediate part (body) of the bridge and the underlying mucous membrane of the alveolar process of the jaw;
 - interocclusal relationships of the prosthesis with antagonists in central, anterior and transversal occlusions, as well as in all phases of articulation of the dentition.

Verification of the stamped-brazed bridge design is an important clinical step. At this stage, all minor inaccuracies that interfere with both the application of the prosthesis and occlusal contact are identified and eliminated. First of all, the prosthesis is assessed by a doctor outside the mouth; the quality of soldering, cast intermediate parts of finishing, and grinding is checked; the anatomical shape of the intermediate part is assessed. The prosthesis should fit freely on the supporting teeth with the correct fit of the crowns and the absence of other errors. After application in a bridge, attention is paid, first of all, to the supporting crowns. They should be minimally immersed in the periodontal groove (about 0.2 mm), restore interdental and occlusal contacts, and have an appropriate anatomical shape. When assessing the intermediate part of the prosthesis, attention is also paid to its anatomical shape and contact with antagonist teeth. The lavage space is assessed using a probe or dental floss; there should be no sharp transitions or separations between artificial teeth on the lingual surface of the prosthesis. When checking occlusal contacts, the prosthesis is examined in central, anterior and lateral relationships. Premature contacts are eliminated on the balancing side, and the working side should have uniform multiple contacts.

The final processing of the prosthesis consists of grinding and polishing it, and applying a decorative titanium nitride coating. Also at this stage, the prosthesis is lined with plastic or a composite material, pre-matched in color to natural teeth.

If the bridge meets all the requirements stated above, it is easy to apply, has an optimal depth of insertion into the periodontal sulcus, multiple contacts with antagonists, etc., then it must be temporarily fixed on the supporting teeth for an adaptation period of 7–10 days. Before fixation with cement, the patient's sensations when using the prosthesis are determined, mobility is checked and the level of hygiene is assessed. The rules for cement fixation correspond to those recommended for single artificial crowns. We recommend using the following procedure: the bridge is cleaned, disinfected and dried. The material for fixation is measured in the proportion recommended by the manufacturer (the powder/liquid combination is more often used - 1/2); as a rule, 3 drops of cement are needed for one crown. After this, the supporting teeth are cleaned, disinfected and dried. A cement mixture is prepared, the crowns are filled 2/3 and fixed on the teeth. When fixing several dentures, we recommend using cementation of opposing structures, starting with the denture on the lower jaw. After the cement has hardened, the excess is removed using a probe, special attention is paid to removing residues from the interdental spaces, for this it is even recommended to schedule a patient for the next day. Recommendations for a two-hour period of abstinence from solid food are associated with complete crystallization of most cements within 2 hours.

Scheme: Errors in the manufacture of stamped-soldered bridges, identified at the stage of checking their design

Errors	Reason	Methods of repairing
Dentures are not placed on supporting teeth.	1. Incorrect preparation of abutment teeth. 2. Displacement of the supporting crowns in the impression.	1. Additional preparation of abutment teeth. 2. Soldering the prosthesis, fitting the supporting crowns, taking an impression, fitting the

	3. Displacement of prosthetic elements during soldering.	intermediate part and soldering.
The supporting crown does not fit tightly to the neck of the tooth.	The crown was made incorrectly.	Making of a new crown.
The denture increases the bite on the abutment crowns.	Teeth are underprepared. Incorrectly fitted crowns.	Additional preparation of abutment teeth, production of new crowns, their fitting, taking impressions, fitting of the prosthetic body
The denture increases the bite on the pontic.	The intermediate part of the prosthesis is modeled with overestimation.	Using carbon paper, areas that impede the movement of the lower jaw are identified and sanded off.

Scheme: Fixation of a bridge prosthesis

Stage	Equipment	Manipulations
1. Preparation of the prosthesis.	Alcohol, cotton wool, tweezers.	Using a cotton swab, thoroughly wipe the denture with alcohol and dry with air.
2. Preparation of fixing material.	Fixing cement, glass, spatula.	The required portions of liquid and powder are applied to the glass plate.
3. Preparation of abutment teeth.	3% hydrogen peroxide solution, alcohol, cotton wool, tweezers, mirror.	Abutment teeth are isolated from oral fluid with cotton wool, treated with a solution of hydrogen peroxide, alcohol and dried with warm air.
4. Mixing of cement.	Cement for fixation, glass, spatula.	Cement is mixed by adding powder to the liquid until it reaches a homogeneous creamy consistency and the abutment crowns are filled with cement to 1/3 of their height.
5. Application and fixation of dentures on supporting teeth.	Mirror, prosthesis with cement mixed in the supporting crowns.	The prosthesis is placed on the teeth and the supporting crowns are advanced to the gingival margin, the patient is asked to close the teeth, checking the correct closure in the central occlusion. Excess cement comes out of the crowns. After curing, remove excess cement.

SITUATIONAL TASKS

1. When a bridge is applied to the supporting teeth, the bite on the intermediate part of the prosthesis in central occlusion increases. Possible reasons and what to do next?
2. When fitting opposing bridges, cuspal contact was obtained in the area of the artificial teeth. Possible errors and complications, what are your next steps?
3. When fitting the bridge frame, it turned out that the distal crown does not tightly cover the neck of the tooth. Reasons, doctor's tactics.
4. When fitting a bridge in the lateral part of the dentition of the lower jaw, the intermediate part touches the mucous membrane of the alveolar process. Assess the clinical situation, name possible complications, what are your next steps?

5. When fitting the bridge, it was revealed that the intermediate part does not have occlusal contact with the antagonist teeth. Your actions?

6. When checking the occlusal contacts of the finished bridge, supracontacts with antagonist teeth are observed. Causes? Your actions?

LITERATURE

Basic:

1. Removable Partial Dentures. A Practitioners' Manual / Editor Olcay Şakar. – 2nd Edition. – Springer, 2024. – 423 p.

2. Waliszewski, Michael P. Brudvik's Advanced Removable Partial Dentures. Book of Prosthodontics. – 2nd Edition. – UK : Quintessence Publishing, 2022. – 203 p.

Additional:

3. Complete dentures. Algorithm of producing. / S. A. Naumovich [et al.]. – 3rd ed.– Minsk : BSMU, 2018. – 32 p.

4. Fixed dentures. Algorithm of producing. / S. A. Naumovich [et al.]. – 3rd ed. – Minsk : BSMU, 2018. – 30 p.

5. Removable partial dentures. Algorithm of producing. / S. A. Naumovich [et al.]. – 3rd ed. – Minsk : BSMU, 2018. – 16 p.

Electronic courseware for the educational discipline «Non-removable»

6. <https://etest.bsmu.by/course/view.php?id=1401>

CLASS 9

Subject: Clinical and laboratory stages of manufacturing of cast-metal, metal acrylic, metal ceramic dentures.

Total time of class – 5 academic hours (200 min).

№	Stages of a practical class	Time in min.
1.	Organizational stage	10
2.	Control of the initial knowledge level	20
3.	Training stage	40
4.	Practicing a practical skill	90
5.	Monitoring the level of the obtained knowledge or mastery of a practical skill	30
6.	Final stage	10

Purpose of the lesson: To study the clinical and laboratory stages of manufacturing solid-cast, metal-acrylic and metal-ceramic bridges. To teach students the correct choice of tools and equipment necessary for the manufacture of solid, metal-acrylic and metal-ceramic bridges.

Objectives of the lesson:

1. Master the clinical and laboratory stages of manufacturing solid dentures.
2. Master the clinical and laboratory stages of manufacturing metal-acrylic prostheses.
3. Master the clinical and laboratory stages of manufacturing metal-ceramic prostheses.
4. Learn to choose the tools and equipment necessary for the manufacture of solid, metal-acrylic and metal-ceramic bridges.
5. To study errors that arise during the manufacture of solid-cast, metal-acrylic and metal-ceramic bridges.

Class location - the clinical setting.

Practical skills mastered during the class:

Checking the construction of metal bridgework prostheses.

Form of control of the practical class: electronic tests; survey; solving situational tasks.

Place of practical skill implementation – at the outpatient appointment.

Practical skill assessment criteria – according to the assessment sheet (checklist) for monitoring practical skills in the academic discipline in points from 0 to 3.

Requirements for initial level of knowledge:

1. Occlusion and articulation.
2. Clinical and laboratory stages of manufacturing solid, MA and MK crowns.
3. Basic and auxiliary materials used for the manufacture of bridges.
4. Equipment and tools used in the manufacture of bridges.

Control questions from related disciplines:

1. Anatomical structure of teeth.
2. Histological structure of the oral mucosa.
3. Anatomical structure of periodontal teeth.
4. Functional and morphological changes that occur in the dental system with partial loss of teeth.
5. Preparing the oral cavity for prosthetics.

Control questions:

1. Clinical and laboratory stages of manufacturing solid, MA and MK bridges.
2. Features of tooth preparation during the manufacture of solid, MA and MK bridges.
3. Checking the design of solid, MA and MK prostheses.
4. Fixation of the prosthesis (temporary and permanent).
5. Possible errors made in the manufacture of various designs of bridges and methods for eliminating them.
6. Recommendations for the patient, doctor's tactics for damage to solid-cast, MA and MC prostheses.

Clinical and laboratory stages of manufacturing solid bridges

First clinical stage:

- examining the patient, making a diagnosis, treatment plan;
- preparation of abutment teeth;
- gum retraction;
- obtaining a working (two-layer) impression;
- obtaining an auxiliary impression of antagonist teeth;
- fixation of central occlusion;
- production of temporary bridges.

First laboratory stage:

- casting the working (collapsible) and auxiliary models, plastering them into the articulator;
- modeling of wax frames;
- replacing wax with metal;
- grinding.

Second clinical stage: testing the design of solid bridges.

Second laboratory stage: final grinding and polishing of solid bridges.

Third clinical stage: fitting and fixation of ready-made solid bridges on the supporting teeth, recommendations for care.

Clinical and laboratory stages of manufacturing metal-acrylic bridges.

First clinical stage:

- examining the patient, making a diagnosis, drawing up a treatment plan;
- preparation of abutment teeth;
- gum retraction;
- obtaining a working (two-layer) impression;
- obtaining an auxiliary impression of antagonist teeth;
- fixation of central occlusion;
- production of temporary bridges.

First laboratory stage:

- casting the working (collapsible) and auxiliary models, plastering them into the articulator;
- modeling of wax frames;
- gluing retention pearls to the bed of facing material;
- replacing wax with metal;
- grinding and polishing of metal frames of bridges.

Second clinical stage:

- checking the design of the metal frame;
- determination of the color of plastic cladding.

Second laboratory stage:

- wax veneer modeling;

- replacing wax with plastic;
- grinding and polishing of cladding.

Third clinical stage: fitting and fixation of finished metal-acrylic bridges on supporting teeth, recommendations for care.

Clinical and laboratory stages of manufacturing metal-ceramic bridges

First clinical stage:

- examining the patient, making a diagnosis, drawing up a treatment plan;
- preparation of abutment teeth;
- gum retraction;
- obtaining a working (two-layer) impression;
- obtaining an auxiliary impression of antagonist teeth;
- fixation of central occlusion;
- production of temporary bridges.

First laboratory stage:

- casting the working (collapsible) and auxiliary models, plastering them into the articulator;
- modeling the frame of a bridge prosthesis from wax;
- replacement of wax with metal.

Second clinical stage:

- checking the design of the metal frame of the bridge;
- determination of the color of ceramic cladding.

Second laboratory stage: sintering of ceramic cladding.

Third clinical stage: testing the design of a solid metal frame with ceramic lining.

Third laboratory stage: glazing and final processing of MC bridges.

The fourth clinical stage: checking and fixing ready-made MK bridges on the supporting teeth, recommendations for care.

SITUATIONAL TASKS

1. When a solid bridge is applied to the abutment teeth, the bite in the position of central occlusion increases. Possible reasons and what to do next?

2. When checking the design of a metal-ceramic bridge, a crack is observed in the ceramic lining of the supporting crown. When applying the prosthesis, did the ceramic mass chip without exposing the metal? What is the cause of this complication, methods for its elimination and prevention?

3. When fitting the MA bridge to the dentition of the upper jaw, a free space of 3 mm is observed in the lateral section between the intermediate part and the mucous membrane of the alveolar process. Possible causes and complications. What are your next steps?

4. When fitting the MC bridge prosthesis, it was revealed that the artificial teeth do not have occlusal contact with the antagonists, and the supporting crowns are in occlusal contact. The prosthesis in the position of central occlusion does not overestimate the bite. Your actions?

5. When checking the design of the MC bridge, a part of the ceramic lining chipped, exposing the metal frame. Name the possible reasons for what happened and determine the doctor's further actions.

6. When checking the design of the frame of a metal-ceramic prosthesis in the oral cavity with support on teeth 43, 45, 46, its balancing is observed. Possible reasons? Your actions?

LITERATURE

Basic:

1. Removable Partial Dentures. A Practitioners' Manual / Editor Olcay Şakar. – 2nd Edition. – Springer, 2024. – 423 p.

2. Waliszewski, Michael P. Brudvik's Advanced Removable Partial Dentures. Book of Prosthodontics. – 2nd Edition. – UK : Quintessence Publishing, 2022. – 203 p.

Additional:

3. Complete dentures. Algorithm of producing. / S. A. Naumovich [et al.]. – 3rd ed.– Minsk : BSMU, 2018. – 32 p.

4. Fixed dentures. Algorithm of producing. / S. A. Naumovich [et al.]. – 3rd ed. – Minsk : BSMU, 2018. – 30 p.

5. Removable partial dentures. Algorithm of producing. / S. A. Naumovich [et al.]. – 3rd ed. – Minsk : BSMU, 2018. – 16 p.

Electronic courseware for the educational discipline «Non-removable»

6. <https://etest.bsmu.by/course/view.php?id=1401>

LESSON 10

Subject: Adhesive bridge dentures. Modern construction materials for manufacturing and luting. Methods of manufacture and methods of luting.

Total time of class – 5 academic hours (200 min).

№	Stages of a practical class	Time in min.
1.	Organizational stage	10
2.	Control of the initial knowledge level	20
3.	Training stage	40
4.	Practicing a practical skill	90
5.	Monitoring the level of the obtained knowledge or mastery of a practical skill	30
6.	Final stage	10

Purpose of the lesson: To analyze and deepen students' knowledge about the features of special preparation of the oral cavity for prosthetics with adhesive bridges. Systematize knowledge of methods for manufacturing and fixing prostheses of this type.

Objectives of the lesson:

1. Reinforce knowledge of examining dental patients.
2. Systematize knowledge about the features of preparing the oral cavity for prosthetics with adhesive bridges.
3. To consolidate knowledge about methods of manufacturing and fixation of adhesive bridges.
4. Master practical skills in diagnosing patients who are indicated for prosthetics with adhesive bridges.
5. Master the skills of selecting structural materials and materials for fixing adhesive prostheses.

Class location - the clinical setting.

Practical skills mastered during the class:

Fixation of bridgework prostheses made from various construction materials.

Form of control of the practical class: electronic tests; survey; solving situational tasks.

Place of practical skill implementation – at the outpatient appointment.

Practical skill assessment criteria – according to the assessment sheet (checklist) for monitoring practical skills in the academic discipline in points from 0 to 3.

Requirements for initial level of knowledge:

1. Partial loss of teeth (partial primary and secondary adentia). Causes, prevalence.
2. Features of clinical examination of patients with partial loss of teeth.
3. Classification of partial edentia according to Kennedy.
4. Reserve forces of the periodontium (odontoparodontogram).

Control questions from related disciplines:

1. Anatomical structure of the dental system of the upper and lower jaw.
2. Histological structure of the oral mucosa.
3. Functional and morphological changes that occur in the dental system with partial loss of teeth.

Control questions:

1. Psychological preparation for prosthetics with partial edentia.
2. Features of prosthetics for diseases of the oral mucosa.
3. Indications and contraindications.
4. Types of adhesive prostheses.
5. Justification and choice of design of adhesive prostheses.
6. Fixation of adhesive prostheses.
7. Methods for making adhesive prostheses.

Special preparation of the oral cavity for prosthetics in case of partial edentia is carried out in accordance with the orthopedic treatment plan and consists of psychotherapeutic, therapeutic, orthodontic, periodontological and surgical measures. In recent years, much attention has been paid to medical psychology and psychotherapeutic measures during orthopedic treatment. It is very important for the doctor to establish contact with the patient and gain his trust, without which it is inappropriate to begin treatment. The patient should be aware of all the features of prosthetics, the limits of possible restoration of chewing function, aesthetics and speech regarding chewing function. If the patient comes to the doctor accompanied by relatives, then such a conversation should be conducted in their presence.

Psychological preparation should be carried out taking into account the temperament of the individual patient. The most favorable conditions for prosthetics when treating patients with a balanced psyche. People in this category are optimistic, calm, do not lose composure even in difficult situations, are friendly to the doctor and willingly follow all his advice and instructions. Conversations with patients who have a balanced psyche about the upcoming difficulties in getting used to partial adhesive dentures, ways to overcome them, as well as proper care of the prosthesis, give good results. Such patients easily overcome various inconveniences and quickly get used to the prostheses.

Preparation of patients with partial edentia comes down to creating conditions that will contribute to rational prosthetics. Prosthetics for patients with chronic diseases of the mucous membrane is possible only in the remission stage.

- Indications for installation of an adhesive bridge:
- Restoration of a small partial defect in the dentition (in the absence of one or two teeth);
- Cases when rapid restoration of aesthetics is required;
- Temporary replacement of a dental defect before implantation.
- Contraindications to installation of an adhesive bridge:
- Severe destruction of the supporting teeth, which will not provide effective fixation of the prosthesis.
- Crowded position of abutment teeth.
- Absence of more than two teeth in the oral cavity.
- Periodontal pathologies (gingivitis/periodontitis/periodontal disease, etc.).
- Increased tooth wear.
- Teeth grinding (bruxism).

There are quite a few types of fastenings and materials for adhesive bridge prosthetics. The most commonly used materials for these restorations are base metals, composites, fiberglass, ceramics and plastics.

Methods of fixation of adhesive bridges:

- Beam fixation system. In this case, the frame for fixing the adhesive bridge will be a metal beam. It is installed in small recesses on the supporting teeth. Then, an artificial crown is fixed onto the beam using a direct method. With this method of fixation, the prosthesis is made directly in the oral cavity (direct method). To make a bar adhesive bridge prosthesis, one visit to an orthopedic dentist is required, which lasts 1-2 hours. The disadvantages of such an adhesive bridge include

fragility in relation to large chewing loads. Because of this disadvantage, an adhesive bar bridge can only be installed on the anterior group of teeth and premolars.

- Fixation on fiberglass. The system is fixed to the abutment teeth using fiberglass tape. To secure the tape to the supporting teeth on the palatal or lingual side, it is necessary to make special grooves. The use of fiberglass reduces the risk of cracks and chips of the prosthesis. In addition, this method of fixation is more aesthetically pleasing, since the fiberglass tape is transparent and invisible.

- Fixation on wing plates. A classic method of fixing an adhesive prosthesis, which is characterized by minimal processing of the supporting teeth. In this case, it is enough to slightly grind the crown of the abutment tooth on the lingual or palatal side. The prosthesis has high aesthetic properties, but at the same time increased fragility. Fixation with wing plates can be used in cases where it is necessary to temporarily replace a small defect in the dentition. Often the method of fixation on the wing plates is a bridge-like prosthesis on the front teeth.

- Fixation on tabs. A plastic or ceramic adhesive bridge that is fabricated in a laboratory. In this case, inlays are made for the supporting teeth from the same material as the artificial tooth. The inlays are fixed in the cavities of the supporting chewing teeth. Often adhesive bridges with fixation on tabs are made using computer CAD\CAM technologies.

Adhesive bridges can be manufactured in the following ways:

- In a dental office setting. Typically these are fiberglass or beam adhesive bridges. The advantages of the technique are that the production time takes a small amount of time, since the process of creating the structure takes place directly in the oral cavity.

- In a dental laboratory

SITUATIONAL TASKS

1. Patient M., 36 years old, came to the orthopedic dentistry clinic with complaints of missing teeth 1.4, 1.5, 1.6. The doctor made an adhesive bridge prosthesis. After 3 weeks, the patient returned to the clinic with complaints about the breakage of the adhesive bridge. What mistake did the doctor make? What orthopedic device should be made for the patient?

2. Patient V., 43 years old, came to the clinic with complaints of missing tooth 1.1. The patient underwent an examination followed by installation of an implant in the area of the missing 1.1. A week after implantation, the orthopedic dentist made a removable denture in the area of the missing tooth. Evaluate the tactics of the orthopedic dentist and the correct choice of orthopedic design?

3. Patient K., 32 years old, came to the clinic with complaints of missing teeth 1.2, 1.1. The examination revealed a decrease in the height of the lower part of the face by 2 mm and the presence of wear facets on the occlusal surface of the teeth. The orthopedic dentist decided to make an adhesive bridge prosthesis in the area of missing teeth 1.2, 1.1. Evaluate the correctness of the doctor's tactics. What diagnostic and treatment plan should have been drawn up?

4. Patient L., 25 years old, complained of an aesthetic defect. On examination: tooth 21 is missing, the defect is replaced with an adhesive bridge. The color of the artificial tooth does not match the color of the patient's adjacent teeth. Where is the mistake? Your treatment plan.

5. Patient K., 31 years old, came to the clinic with complaints of missing tooth 1.5. Teeth 1.4 and 1.6 have class 2 fillings. An orthopedic dentist made an adhesive bridge prosthesis from ceramics. The bridge was placed in the oral cavity and fixed with phosphate cement. Evaluate the correctness of the doctor's actions.

6. Patient A., 57 years old, applied to the department of orthopedic dentistry with complaints of missing teeth 1.1, 2.1. The examination revealed tooth mobility of 1.2, 2.2 and 3 degrees. The x-ray shows bone tissue atrophy in the area of 1.2, 2.2 at 2/3 of the length of the tooth roots. The dentist made an adhesive bridge prosthesis for the missing 1.1, 2.1 with fixation on 1.2, 2.2. Evaluate the correctness of the doctor's actions.

LITERATURE**Basic:**

1. Removable Partial Dentures. A Practitioners' Manual / Editor Olcay Şakar. – 2nd Edition. – Springer, 2024. – 423 p.
2. Waliszewski, Michael P. Brudvik's Advanced Removable Partial Dentures. Book of Prosthodontics. – 2nd Edition. – UK : Quintessence Publishing, 2022. – 203 p.

Additional:

3. Complete dentures. Algorithm of producing. / S. A. Naumovich [et al.]. – 3rd ed.– Minsk : BSMU, 2018. – 32 p.
4. Fixed dentures. Algorithm of producing. / S. A. Naumovich [et al.]. – 3rd ed. – Minsk : BSMU, 2018. – 30 p.
5. Removable partial dentures. Algorithm of producing. / S. A. Naumovich [et al.]. – 3rd ed. – Minsk : BSMU, 2018. – 16 p.
Electronic courseware for the educational discipline «Non-removable»
6. <https://etest.bsmu.by/course/view.php?id=1401>

LESSON 11

Subject: Modern construction materials and methods of manufacturing metal-free bridge dentures.

Total time of class – 5 academic hours (200 min).

№	Stages of a practical class	Time in min.
1.	Organizational stage	10
2.	Control of the initial knowledge level	20
3.	Training stage	40
4.	Practicing a practical skill	90
5.	Monitoring the level of the obtained knowledge or mastery of a practical skill	30
6.	Final stage	10

Purpose of the lesson: analyze and deepen students' knowledge about the features of special preparation of the oral cavity for prosthetics with all ceramic bridges. Systematize knowledge about materials and methods for manufacturing prostheses of this type.

Objectives of the lesson:

1. To consolidate knowledge of patients examining.
2. Systematize knowledge about the features of preparing the oral cavity for prosthetics with all-ceramic bridges.
3. To consolidate knowledge about the methods of manufacturing all ceramic bridges.
4. Learn to choose structural materials for the manufacture of all ceramic dentures.

Class location - the clinical setting.

Practical skills mastered during the class:

Determining tooth color.

Form of control of the practical class: electronic tests; survey; solving situational tasks.

Place of practical skill implementation – at the outpatient appointment.

Practical skill assessment criteria – according to the assessment sheet (checklist) for monitoring practical skills in the academic discipline in points from 0 to 3.

Requirements for initial level of knowledge:

1. All-ceramic prosthetics. Kinds.
2. Indications and contraindications for prosthetics with all-ceramic structures.
3. Materials and methods for dentures manufacturing.

Control questions from related disciplines:

1. Safty zones according by Abolmasov, Gavrilov
2. Materials in dentistry.
3. Functional and morphological changes that occur in the dental system with partial loss of teeth.

Control questions:

1. General characteristics of all-ceramic bridges.
2. Indications for the use of bridges.
3. Features of tooth preparation for all-ceramic orthopedic structures.
4. Impressions taking for the manufacture of all-ceramic orthopedic structures.

5. Materials used for the manufacture of all ceramic bridges.
6. Fixation of all-ceramic orthopedic structures.

All-ceramic bridges are a type of permanent dental prosthesis that is used to replace one or more missing teeth. They are attached to the supporting teeth using various materials and fixation methods. All-ceramic bridges have a number of advantages over PFM prostheses, such as better aesthetics, biocompatibility, light refraction and lack of corrosion. They are one of the most innovative and popular methods of dental restoration. Dentures are made from special materials such as zirconium dioxide or ceramics, which makes them more aesthetically pleasing than metal dentures.

One of the main advantages of all ceramic bridges is their strength and durability. They are not subject to corrosion and are also less susceptible to wear than metal dentures. All ceramic dentures are also more biocompatible and may feel more pleasant to the touch than metal dentures.

In addition, all ceramic bridges have a higher aesthetic value. They blend better with natural teeth and do not have a metallic tint that can be noticeable when smiling.

The production of all ceramic bridges is carried out using CAD/CAM technologies, which allows obtaining more accurate results and reducing production time. However, it is important to consider that all ceramic dentures can be more expensive than metal dentures.

Indications for the use of bridges

Bridges are usually indicated if:

- up to 4 incisors are missing, but chewing function is provided by natural teeth or existing bridges;
- in the area of the lateral teeth on one side of the jaw no more than 3 teeth are missing and the dentition can be restored using a bridge with supports on both sides;

The bridge will serve to fix the removable denture.

Thus, bridges are made with support on natural teeth on both sides (with the exception of cantilever ones).

Bridges are not indicated:

- with insufficient ability of the periodontium to withstand the load and such general somatic
- diseases that adversely affect periodontal tissue;
- if an x-ray of the supporting tooth indicates a pathological process that cannot be stopped.

The choice of bridge construction is determined by:

- size of the defect;
- topography of the defect;
- condition of supporting teeth;
- condition of antagonist teeth.

Teeth are prepared according to the following principles:

The circular shoulder is formed to a depth of 1.0 mm, it is recommended to use cylindrical diamond tools with a rounded head for a rounded shoulder and a truncated head for a straight (90°) shoulder.

Diamond instruments with a grit of 30 microns can be used for preparation. The preparation is gentle, since due to its high strength, the minimum thickness of the zirconium oxide framework can be 0.4 mm, the minimum space for ceramic veneering is 0.6 mm.

Preparation of the frontal group of teeth is carried out according to the standard (general) scheme. It is necessary to form a circular shoulder to a depth of 1 mm at the preparation border. In addition, it is recommended to ensure a taper of the prepared tooth of 6 to 8°. The internal corners are also rounded, since the prepared tooth should not have sharp edges (minimum radius is about 0.4 mm).

In the area of the incisal edge, 2.0 mm of tooth structure must be removed to achieve a good aesthetic result. The minimum width of the cutting edge must be 0.9 mm to ensure an accurate reproduction of the inner surface of the zirconia framework.

To prepare the palatal surface of the teeth, it is recommended to use a special Palatinalschleifers bur. The same tool can be used to round sharp edges and transitions between axial surfaces and the cutting edge.

From the occlusal side of premolars and molars, 1.5 mm of hard tooth tissue is removed. Due to the high strength of zirconium oxide, the minimum wall thickness of the frame can be only 0.4 mm. When preparing, it is necessary to ensure the taper of the prepared tooth from 3 to 4°. Transitions between the approximal and occlusal surfaces should be rounded.

The occlusal surface should be a simplified form of the chewing surface. Opening angles of the occlusal surface from 120 to 140° guarantee accurate reproduction of the restored internal surfaces during milling and a good internal fit.

The rhomboid-shaped diamond bur, which is recommended for preparing the occlusal surface, should be positioned perpendicular to the axis of the tooth.

When preparing teeth for bridge structures, the proximal surfaces of the supporting teeth must have a taper of at least 6°. This contributes to a better program display when milling.

During the manufacture of bridge structures to replace two or more teeth, it is necessary to include a larger number of supporting teeth in the structure, therefore, to control the correct preparation of the teeth, it is necessary to take an impression with alginate, followed by making a model with quick-hardening plaster. Control is possible within just a few minutes.

The impression is taken with a standard or individual tray, which can be made in the laboratory or directly by a doctor from light-curing plastic or thermoplastic material.

The impression is taken in compliance with generally accepted principles. The following groups of impression materials can be used to obtain impressions: hydrocolloid, polysiloxane and polyester. Polysiloxane materials are used in one- and two-stage techniques for obtaining impressions.

Modern structural materials for metal-free bridges can be divided into three groups: polymers, composites and ceramics. Each group has its own characteristics, advantages and disadvantages.

Polymers are the least hard and cheap materials that are subject to wear, water absorption, biodegradation, color change, and also have a number of other disadvantages. They are used for the manufacture of temporary and budget prostheses, as well as for frames lining made of other materials.

Composites are materials consisting of a mixture of polymer and filler (glass, quartz, zircon, etc.). They have higher strength, wear resistance and color fastness than polymers, and are also easy to correct and repair. However, they are also subject to shrinkage, toxicity and may cause allergic reactions.

Ceramics is the hardest and most expensive material for all ceramic prostheses. It has excellent aesthetic properties, close to natural teeth, as well as high biocompatibility and corrosion resistance. However, it also has some disadvantages, such as fragility, difficulty in manufacturing and repair. Ceramics can be different in composition and processing method: feldspathic, aluminum, zirconium, glass-infiltrated, etc.

Zirconium dioxide is a material for the manufacture of premium dental prostheses, which also belongs to metal-free ceramics. Zirconium oxide (ZrO₂) consists of biocompatible, colorless crystals of high strength. Such dentures are designed to withstand severe chewing loads, and their appearance is close to a natural tooth. After installation, allergic reactions and gum inflammation do not occur. Zirconium dioxide prostheses are superior to ceramic prostheses in strength, but inferior to them in aesthetics. The material is supplied in the form of blocks for milling (mono-color or multi-color).

Modern methods for manufacturing all ceramic bridges include traditional and innovative technologies. Traditional technologies are based on manual molding and firing of materials (layer-by-layer sintering or pressing of wax reproduction). Innovative technologies are based on computer modeling and automated production of prostheses using CAD/CAM systems and 3D printing.

The most popular materials for the manufacture of all ceramic structures:

1. Polymers:

- GC (Japan)
- Zhermack (Italy)
- DETAH (Germany)
- Voco (Germany)
- ВладМиВа (Russia)
- 2. Composites:
 - 3M (Germany)
 - Voco (Germany)
 - Zhermack (Italy)
 - DMG (Germany)
- 3. Ceramics:
 - Ivoclar (Austria)
 - Dentsply Sirona (Switzerland)
 - Vita (Germany)
- 4. Zirconium dioxide:
 - Ivoclar (Austria)
 - Amann Girrbach (Австрия)
 - Zirkonzahn (Italy)
 - KINGCH (China)

Thus, all ceramic bridges are a modern and promising direction in dental orthopedics. They allow you to restore the function and aesthetics of teeth with minimal intervention in the hard tissues of supporting teeth and with maximum consideration of the individual characteristics of the patient. However, to select the optimal material and method of manufacturing a prosthesis, it is necessary to take into account many factors, such as the degree of defect, periodontal condition, occlusion, tooth color, financial capabilities of the patient, etc.

To fix all-ceramic structures, it is possible to use glass ionomer and composite cements.

For adhesive fixation of all-ceramic structures, dual-curing composite cements, for example, Variolink, RelyX, Maxcem Elite, can be recommended.

For temporary fixation, you can use eugenol-free materials Temp Bond, TempoCem.

SITUATIONAL TASKS

1. Patient S, 26 years old, contacted the department of orthopedic dentistry with complaints of missing teeth. The examination revealed that teeth 1.2., 1.1, 2.1, 2.2 were missing. A dentist made an all-ceramic bridge prosthesis of 6 units supported by 1.3,2.3. Evaluate the correctness of the doctor's tactics. What complications may the patient have?

2. Patient L, 67 years old, contacted the orthopedic department with complaints of missing tooth 4.6. Objectively: tooth 4.6 is missing, teeth 4.4,4.5 are with composite restorations (destruction of the occlusal surface according to the IDOST index of 60%). The orthopedic dentist made all-ceramic crowns for 4.4; 4.5 and a cantilever tooth was made in the area of the missing 4.6. Evaluate the correctness of the doctor's tactics. What complications may the patient have?

3. Patient M, 36 years old, contacted the orthopedic department with complaints of destruction of the frontal group of teeth in the upper jaw. Objectively, teeth 1.2;1.1;2.1;2.2 are with defective composite restorations with a violation of the marginal fit of the restorations, discoloration and signs of secondary caries. Also, wear facets were identified on the occlusal surface of all teeth and a decrease in the height of the lower part of the face by 2 mm. A dentist made single all-ceramic crowns for teeth 1.2; 1.1; 2.1; 2.2. Evaluate the correctness of the doctor's actions.

4. Patient K, 21 years old, contacted the orthopedic department with complaints of an aesthetic defect in tooth 2.1. After an examination and diagnosis, it was decided to make a zirconium dioxide crown for tooth 2.1. The tooth was prepared for a zirconium dioxide crown, impressions were taken from alginate impression material and transferred to the dental laboratory. At the stage of fitting the crown in the oral cavity, it was revealed that the edge of the crown does not reach the finish line

contacted of the prepared tooth by 1 mm. At what stages were mistakes made? Indicate the doctor's tactics.

5. Patient A., 46 years old, complained of biting her cheek on the right. According to the patient, about 5 months ago she had zirconium bridges made for her upper and lower jaws with supports on teeth 24, 26 and 3.4, 37. The patient has been smoking for more than 15 years. An area of leukoplakia is objectively determined on the inner surface of the cheek along the line of closure of the teeth on the right and left. In addition, on the left there is a zone of chronic trauma with dental imprints. When the teeth are closed in the position of central occlusion on the left, the palatal cusps of the upper premolars and molars are located at the same level with the lingual cusps of the lower antagonists. What could be the reason for the development of leukoplakia? What is the tactics of a dentist?

6. Patient B., 47 years old, came to the clinic with complaints of pain under the pontic of the bridge. From the anamnesis: 2 months ago, the patient had a zirconium bridge prosthesis made for the upper jaw supported by teeth 14, 15, 17. An examination of the oral cavity revealed: the pontic of the bridge is tightly adjacent to the crest of the alveolar process in the area of the missing tooth 16, the gums are swollen, hypertrophied, painful on palpation. Indicate the possible cause of the patient's complaints, what additional research methods need to be carried out? Your tactics to eliminate complications.

LITERATURE

Basic:

1. Removable Partial Dentures. A Practitioners' Manual / Editor Olcay Şakar. – 2nd Edition. – Springer, 2024. – 423 p.

2. Waliszewski, Michael P. Brudvik's Advanced Removable Partial Dentures. Book of Prosthodontics. – 2nd Edition. – UK : Quintessence Publishing, 2022. – 203 p.

Additional:

3. Complete dentures. Algorithm of producing. / S. A. Naumovich [et al.]. – 3rd ed.– Minsk : BSMU, 2018. – 32 p.

4. Fixed dentures. Algorithm of producing. / S. A. Naumovich [et al.]. – 3rd ed. – Minsk : BSMU, 2018. – 30 p.

5. Removable partial dentures. Algorithm of producing. / S. A. Naumovich [et al.]. – 3rd ed. – Minsk : BSMU, 2018. – 16 p.

Electronic courseware for the educational discipline «Non-removable»

6. <https://etest.bsmu.by/course/view.php?id=1401>

LESSON 12

Subject: CAD/CAM technologies in fixed dental prosthetics.

Total time of class – 5 academic hours (200 min).

№	Stages of a practical class	Time in min.
1.	Organizational stage	10
2.	Control of the initial knowledge level	20
3.	Training stage	40
4.	Practicing a practical skill	90
5.	Monitoring the level of the obtained knowledge or mastery of a practical skill	30
6.	Final stage	10

Purpose of the lesson: analyze and deepen students' knowledge about the use of modern computer technologies in fixed dental prosthetics (CAD/CAM technologies).

Objectives of the lesson:

1. To consolidate knowledge in the field of computer technology in dentistry.
2. Systematize knowledge about CAD/CAM technologies.
3. Study the clinical and laboratory stages when using CAD/CAM technologies in fixed prosthetics.

Class location - the clinical setting.

Practical skills mastered during the class:

Determining the index of the damaged occlusal surface of the tooth (IDOST) and choosing the type of orthopedic construction based on the index.

Form of control of the practical class: electronic tests; survey; solving situational tasks.

Place of practical skill implementation – at the outpatient appointment.

Practical skill assessment criteria – according to the assessment sheet (checklist) for monitoring practical skills in the academic discipline in points from 0 to 3.

Requirements for initial level of knowledge:

1. Materials used in dentistry for the manufacture of various orthopedic structures.
2. Materials used in dentistry for fixation of various orthopedic structures.
3. Instruments used in tooth preparation.
4. Tools used for milling orthopedic structures.
5. Immune zones according to Gavrilov.

Control questions from related disciplines:

1. Anatomical structure of the dentofacial system.
2. Physical and optical properties of materials used for CAD/CAM.
3. Odontoparadontogramma.
4. Knowledge of a personal computer.

Control questions:

1. Meaning of the abbreviation CAD/CAM.
2. Stages of operation of the CAD/CAM system.
3. Features of tooth preparation for all ceramic structures.
4. Materials for the manufacture of ceramic prostheses using CAD/CAM systems.

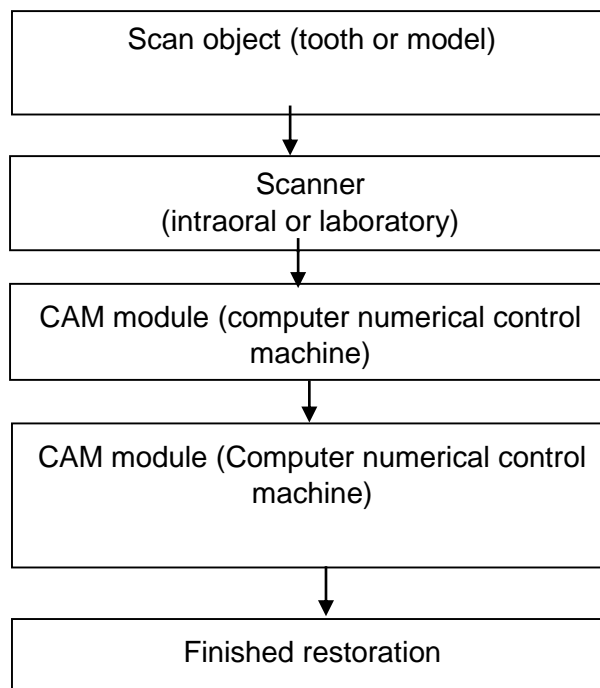
5. Main directions of development of dental CAD/CAM systems.
6. Clinical and laboratory stages of crown manufacturing using CAD/CAM technologies.

CAD/CAM – abbreviation for "Computer Assisted Design/Computer Aided Manufacturing"

CAD – computer modelling. The name is formed by the abbreviation of the English expression "Computer-Aided Design".

CAM – computerized production. The name is formed, accordingly, by the abbreviation of the English expression "Computer-Aided Manufacturing"

The basic operating principle of all modern automated dental systems can be represented in the form of a scheme:



The operation of the automated system consists of the following stages:

- Collection of data on the surface of the prosthetic bed with a special device and conversion of the received information into a digital format acceptable for computer processing. Surface scanning is carried out by optical or mechanical sensors. For the operation of extraoral scanners of other systems, preliminary taking of traditional impressions with impression materials and the production of plaster models are required.

- Virtual modeling of the prosthesis using special computer programs. In recent years, three-dimensional animated modeling has been developing, which greatly simplifies and speeds up the creation of a virtual prosthesis and makes it more visual. The doctor looks at the structure on the monitor screen from all sides at different magnifications and, if necessary, makes adjustments.

- Computer programs have also been developed that allow modeling prostheses taking into account the characteristics of articulatory movements and occlusal contacts, the so-called virtual articulators. When the design of the restoration is completed, the software converts the virtual model into a specific set of commands and transmits them to the production module.

- Direct production of dentures on special devices (modules) with computer control in automatic mode. The resulting set of commands is converted into a sequence of electrical impulses that control high-precision movements of the manufacturing tool. Various CAD/CAM systems use

one of three options for manufacturing ceramic dentures: milling from ready-made blocks (ceramic, zirconium, metal, plastic), sintering under pressure, and crystal deposition using electrophoresis.

Depending on the possibility of implementing all technological stages within one medical institution, dental CAD/CAM systems are conventionally divided into individual (mini-laboratories) and centralized (production centers). Customized systems allow the fabrication of dentures in one patient visit. However, for their full operation it is necessary to purchase all expensive components. In addition, they have lower productivity. Centralized systems are one high-tech production center that fulfills orders received from a whole network of peripheral scanning stations.

Today, using CAD/CAM technology, it is possible to produce a wide range of orthopedic structures: restorative inlays and onlays, veneers, partial and full crowns, post teeth, core pins, bridge frames, telescopic crowns and individual heads for implants.

The main directions of development of dental CAD/CAM systems are:

- Use of optical scanning. Its advantages are speed and accuracy. For example, the latest scanner models allow you to scan an entire plaster model of the jaw in one go.
- Scanning speed and volume are increasing, along with a desire to reduce scanner size.
- The capabilities of computer programs that simulate the future design are expanding.
- The list of milled materials is expanding. Titanium, gold alloys, all types of dental ceramics, plastics, and composites are used.
- The length of structures increases. Modern systems make it possible to mill prosthetic frames with a length of 14 units.
- High-strength ceramic materials (zirconia reinforced with yttria) and good marginal fit of the frame allow crowns to be fixed with conventional cement.

Sequence of stages in the manufacture of an all-ceramic (single-layer) crown in modeling mode.

Manufacturing an all-ceramic crown includes the following steps:

Clinical stages:

- Clean the tooth surface using paste and brush.
- Determine the color of the restoration, anesthetize the tooth.
- Prepare the tooth for a ceramic crown, taking into account the following requirements:
 - the minimum preparation depth on the occlusal surface is 1.5 mm;
 - the angle of inclination of all walls is 4–6°;
 - creating a circular finish line 1.2 mm wide at an angle of 90–110°;
 - absence of sharp edges and undercuts;
 - final processing of the stump with a diamond bur with a grain size of no more than 20 microns.
- Take an optical impression of the prepared tooth and antagonists.
- Select the tooth number, restoration type and modeling mode from the program menu.
- Position the scanner over the tooth so that there are no shadowed surfaces and take the required number of images.
 - Determine the CO using a scanner.
 - On the virtual model, draw separation lines with adjacent teeth and outline the working area of the antagonists.
 - Delineate the boundary of the finish line.
 - Select the required morphology option in the dental database.
 - Edit the proposed crown.
 - Check occlusal and proximal contacts.
 - Preview the virtual design and adjust it if necessary.
 - Send the virtual structure to the milling center or to the milling machine.

Laboratory stages:

- Select the required type of ceramic block and fix it in the grinding module holder. Start the grinding process, after which remove the finished crown and separate it from the shank using a diamond tool.

Clinical stages:

- Check the color and shape of the finished crown in the patient's mouth, avoiding the occlusion of the teeth.

Laboratory stages:

- Glaze the crown in accordance with the manufacturer's recommendations.

Clinical stages:

- Fix the finished crown on the tooth stump with composite cement, using an adhesive technique with mandatory etching of the inner surface of the ceramic structure with 5% hydrofluoric acid and subsequent silanization.
- Remove excess cement. Check and, if necessary, correct the occlusion with a water-cooled diamond instrument.

Thus, the following conclusions can be drawn:

- Almost all CAD/CAM systems are in the stage of constant improvement and updating.
- Modern CAD/CAM systems have become equal in their modeling capabilities and types of designs of fixed prostheses to the traditional, wax method of making frames.
- Using a CAD/CAM system requires the dental technician to have good computer skills.

Some CAD/CAM systems have surpassed 20 years of proven clinical success. This allows doctors to widely use the capabilities of these systems in their practice.

Restorations made using modern dental CAD/CAM systems are a reliable and aesthetic alternative to conventional methods for manufacturing prosthetic structures and can provide good prosthetic results.

Modern types of intraoral scanners:

- 3Shape (Denmark)
- SIRONA (Germany)
- Medit (Korea)
- Planmeca (Finland)

Modern types of laboratory scanners:

- Shining 3D (China)
- AutoScan (China)
- Amann Girrbach (Austria)
- Zirkonzahn (Italy)

Milling machines:

- Amann Girrbach (Austria)
- Zirkonzahn (Italy)
- Dentsply Sirona (Switzerland)
- Bloomden (China)
- Kavo (Germany)

Materials for the manufacture of ceramic prostheses using CAD/CAM systems

Ceramic blanks manufactured industrially have improved physical and mechanical properties compared to ceramic structures manufactured in a dental laboratory using traditional methods. The term "machine ceramics" is used to refer to the various types of ceramic materials used in CAD/CAM technology.

Based on their microstructure, machine-made ceramics can be divided into three types:

- partially filled glass ceramics containing 50% or more glass phase;

- highly filled glass ceramics with a glass phase content of up to 30%;
- polycrystalline ceramics that do not contain a glass phase.

Any ceramics for CAD/CAM can be called composite, since it consists of two or more components that are insoluble in each other. The components themselves and their quantity determine such a variety of ceramic materials. Based on their purpose, ceramics can be divided into structural (for making frames) and aesthetic (for solid structures)

SITUATIONAL TASKS

1. After preparation of the tooth for an all-ceramic crown, the tooth is out of occlusion, prepared along the chewing surface so that the tooth is shortened by 3 mm of the height of the tooth crown and the angle of inclination of all walls is 12°. What mistakes and complications are made when preparing a tooth? What's your tactic?

2. When adhesively fixating an all-ceramic crown, the inner surface of the crown was treated with 37% phosphoric acid, without subsequent silanization. Evaluate the correctness of the doctor's actions. What could such an error lead to?

3. Patient A., 28 years old, complained of an aesthetic defect. During examination: tooth 2.1 is covered with an all-ceramic crown. The color of the artificial crown does not match the color of the patient's adjacent teeth. Where is the mistake? Your treatment plan.

4. Patient S., 47 years old, complained of short-term pain from temperature stimuli in area 1.4. Tooth 1.4 is covered with an all-ceramic crown; a gap of 1 mm was found between the edge of the crown and the finish line of the tooth on the palatal side. Indicate the cause of the patient's pain. At what stages of production were errors made? Indicate the doctor's tactics.

5. When fitting a zirconium dioxide crown, an increase of the occlusal contacts by 0.5 mm was revealed. At what clinical and laboratory stages of crown manufacturing were errors made? Indicate the doctor's tactics.

6. When taking an optical impression in the area of the lower third of the prepared tooth, the program showed an area of the tooth colored red. What mistake did the doctor make and at what stage of making the crown?

LITERATURE

Basic:

1. Removable Partial Dentures. A Practitioners' Manual / Editor Olcay Şakar. – 2nd Edition. – Springer, 2024. – 423 p.
2. Waliszewski, Michael P. Brudvik's Advanced Removable Partial Dentures. Book of Prosthodontics. – 2nd Edition. – UK : Quintessence Publishing, 2022. – 203 p.

Additional:

3. Complete dentures. Algorithm of producing. / S. A. Naumovich [et al.]. – 3rd ed. – Minsk : BSMU, 2018. – 32 p.
4. Fixed dentures. Algorithm of producing. / S. A. Naumovich [et al.]. – 3rd ed. – Minsk : BSMU, 2018. – 30 p.
5. Removable partial dentures. Algorithm of producing. / S. A. Naumovich [et al.]. – 3rd ed. – Minsk : BSMU, 2018. – 16 p.

Electronic courseware for the educational discipline «Non-removable»

6. <https://etest.bsmu.by/course/view.php?id=1401>

LESSON 13

Subject: Clinical stages and modern materials for fixing metal-free fixed dentures.

Total time of class – 5 academic hours (200 min).

№	Stages of a practical class	Time in min.
1.	Organizational stage	10
2.	Control of the initial knowledge level	20
3.	Training stage	40
4.	Practicing a practical skill	90
5.	Monitoring the level of the obtained knowledge or mastery of a practical skill	30
6.	Final stage	10

Purpose of the lesson: analyze and deepen students' knowledge about the features and clinical stages of fixation of all ceramic fixed orthopedic structures and the materials used for this.

Objectives of the lesson:

1. To consolidate knowledge on fitting all ceramic orthopedic structures.
2. Systematize knowledge about the features of preparing orthopedic structures and dental tissues before fixation the structure.
3. Learn to choose materials used for fixation various non-removable all ceramic structures.
4. Master practical skills in fixation metal-free fixed orthopedic structures.

Class location - the clinical setting.

Practical skills mastered during the class:

Fixation of bridgework prostheses made from various construction materials.

Form of control of the practical class: electronic tests; survey; solving situational tasks.

Place of practical skill implementation – at the outpatient appointment.

Practical skill assessment criteria – according to the assessment sheet (checklist) for monitoring practical skills in the academic discipline in points from 0 to 3.

Requirements for initial level of knowledge:

1. Classification of fixing materials for fixation.
2. Indications for the use of various materials for fixation.
3. Methods of isolating the working field, using the Cofferdam system.
4. Methods of pain relief in dentistry.

Control questions from related disciplines:

1. Classification of anesthetics.
2. Histological structure of hard dental tissues.
3. Classification of materials used for finishing of all ceramic orthopedic structures.
4. Physical and optical properties of materials for fixation in dentistry: transparency, thixotropy, etc.

Control questions:

1. Materials and methods for fixation of all ceramic orthopedic structures.
2. Materials used for fixation of all ceramic orthopedic structures, depending on the material from which they are made.
3. Advantages and disadvantages of composite cements.

4. Advantages and disadvantages of glass ionomer cements.
5. Adhesive fixation of all ceramic orthopedic structures.
6. Fixation of all ceramic orthopedic structures on Fuji Plus.

There are no universal materials for fixation, since the requirements placed on them are numerous and sometimes contradictory. As a rule, this list includes: the quality of adhesion to hard dental tissues and to indirect restorations, aesthetic characteristics, biocompatibility, the presence of anti-cariogenic properties, ease of use, absence of postoperative sensitivity and, of course, price. Therefore, the dentist needs to have a variety of bonding materials on hand. I personally always have three cements in my clinic.

The fixation stage is undoubtedly an important stage that completes the cycle of fixed orthopedic treatment. The reliability and effectiveness of this stage determine the clinical durability of fixed orthopedic structures. If errors are made at this stage, de-cementation of orthopedic structures may subsequently occur, which can lead to significant problems.

To ensure reliable fixation, the dentist should:

- Select the correct fixation method.
- Select the correct material for fixation.
- Perform all procedures clinically competently and minimize possible errors.

Today's fixation methods include the following 3 techniques:

- Traditional fixation (GIC, modified GIC).
- Adhesive fixation.
- Fixation using self-adhesive composite cements.

In clinical practice, 4 main groups of materials for fixation are used:

- Traditional chemically cured GIC (Ketac Cem Easymix, Fuji 1).
- Modified (hybrid) chemically cured GIC (Relyx Luting 2, Fuji Plus).
- Dual-curing composite cements (Relyx ARC, Variolink, Pabavia F).
- Self-adhesive dual-cure composite cements (RelyX U200, Maxcem).

In clinical practice, the most important points are the correct choice of technique and material for fixation, as well as compliance with the technology of the procedure itself.

When using all ceramic construction, to select a method and material for fixation, you must first take into account the type of structure. Ceramic inlays, veneers, onlays, crowns are fixed only using the adhesive method, in which mutual stabilization of the ceramic structure and dental tissue occurs. The process of adhesive fixation is quite complex and labor-intensive work, which requires strict implementation of all technological steps according to the instructions. The use of a rubber dam is recommended in almost all cases of adhesive fixation of prosthetic restorations.

Adhesive fixation of inlays, onlays and endocrowns must be done using dual-curing composite cement, since the additional chemical polymerization mode ensures complete curing of the material in those places where light from the polymerization lamp cannot reach (RelyX ARC).

For veneers fixation, light-curing cements with trial pastes are used, which allow you to see the future result of fixation even at the stage of fitting the structures (RelyX Veneer Cement, Variolink).

All-ceramic structures with a reinforced framework do not require adhesive cementation and can be reliably cemented using traditional GIC or self-adhesive composite cements (RelyX Luting 2, RelyX U200).

The choice of adhesive cement is an important task for the dentist, who must know the advantages and disadvantages of various materials and the indications for their use. In recent years, composite cements have undergone significant development, thus, adhesive cementation of ceramic structures has become an integral part of modern restorative dentistry.

Variolink® Esthetic composite cement is available in two forms – LC (light-curing) and DC (dual-curing). It has a large number of indications for use and covers a wider range of clinical situations. It is convenient and optimized; you can remove excess material thoroughly and without haste. In addition, the material has an ideal consistency and allows fixation of restorations without stress or tension. The LC version is used for cementing relatively transparent glass-ceramic restorations up to 2 mm thick. The dual-curing version of Variolink Esthetic DC cement is intended for the installation of larger restorations or those made of more opaque glass-ceramics. Working with new materials requires closer communication with the dental technician. The doctor must know not only the shade of the ceramic used to make the restoration, but also its transparency/opacity. This information will allow him to more accurately select the appropriate cement for fixation. Ideally, cement for adhesive fixation of orthopedic structures should retain its aesthetic properties for many years. Until recently, the aesthetic stability of composite cements was not the best; they lost color over time due to the content of tertiary amines. Variolink Esthetic composite cement does not contain tertiary amines. Thus, long-term color stability is possible. The LC version has a neutral shade effect that provides complete camouflage of the ceramic restoration. This cement also has a chameleon effect. One of the difficulties in working with adhesive luting cements is the removal of excess material. Accidentally leaving material on a tooth can cause gum recession. Thanks to the radiopacity of Variolink Esthetic, material excess that is difficult to see with the naked eye can be detected using radiography. In addition, the material provides sealing or correction of clinically erroneous adaptation of the structure.

The use of high-quality ceramic materials for restoration, such as IPS e.max®, in combination with high-tech adhesive cement is the basis for high esthetic results. Variolink Esthetic cement is compatible with Tetric N-Bond® Universal - a universal adhesive for enamel and dentin and allows all etching techniques: selective etching, total etching, as well as self-etching. The adhesive is thoroughly rubbed into the tooth tissue for 20 seconds, then distributed over the surface and polymerized for 10 seconds. With this technique, bonding does not affect the accuracy of fixation of the restoration, since the thickness of the film formed is only 10 microns.

The choice of composite-modified glass ionomer cement is made taking into account various parameters that depend on the type of restoration and the condition of the oral cavity, such as:

- primary good retention of prepared elements,
- impossibility of installing a rubber dam,
- presence of gingival fluid,
- condition of hard tissues,
- risk of caries development.

GC's Fuji PLUS composite-modified glass ionomer cement can be used routinely, especially in cases where the prosthesis margins are below the gingival level and/or when the preparation provides a high degree of retention. This is typical for metal-ceramic bridges or crowns, ceramic crowns with a zirconia framework, and some ceramic inlays. Fuji PLUS, which has proven its value over time, is extremely easy to use and allows you to easily remove excess material. It also has unique properties such as excellent biocompatibility, good adhesion to moist hard dental tissues and anti-cariogenic effects due to the release of fluoride ions. The material is easy to use, has a simple application protocol, and one of the advantages is that the material is hydrophilic, therefore suitable for fixing orthopedic structures for subgingival tooth decay. The excellent “pulp tolerance” of this material, combined with its sealing properties, also argues for its use in vital teeth.

The choice of material for fixation must be justified. It, in turn, is dictated by a number of parameters that depend on the primary retention of the prepared units, aesthetics, materials used, location of the preparation margins, dimensions of the restoration, simplicity of the protocol, the ability to isolate gingival fluid during cementation and, finally, cost. Benefits of Fuji plus for patients: It is more resistant to hydrolysis and dehydration than traditional glass ionomer cement. This ensures excellent sealing and therefore good clinical behavior of the restorations. This factor is fundamental

to predicting the viability of prosthetic structures and provides some clarity as to what patient expectations may be.

RelyX Luting 2 is a hybrid resin-modified GIC with a low coefficient of expansion and zero water absorption coefficient. Along with high fracture resistance, it has good handling properties. Long working hours allow you several structures fixation at the same time. In addition, thanks to the white opaque shade, cement allows you to mask darkened stumps during fixation pressed glass-ceramic crowns.

Adhesive fixation of all ceramic structures:

- removing temporary restorations and cleaning teeth from temporary cement
- fitting of permanent restorations with demonstration of the result to the patient
- selection of the desired shade of composite for fixation using one of the trial pastes from the composite cement set
- treatment of ceramic structures with 5% hydrofluoric acid for 20 s.
- silanization of the orthopedic structure.
- isolation of the working field in the oral cavity
- treatment with 37% phosphoric acid, rinsing and drying.
- application of adhesive and exposure (when using a dual-curing adhesive system, exposure may not be required)
- filling an all ceramic structure with composite cement, applying it to the tooth, removing excess material with a microbrush and polymerizing the composite cement
- application of glycerin to prevent the formation of an oxygen-inhibited layer during the final polymerization of the composite cement.
- rinsing, removing residual excess material using a scalpel.
- polishing restorations using special rubber polishers according to the manufacturer's recommendations.

Fixation on Fuji Plus

The cement application protocol recommends pre-cleaning the preparation areas and then etching them with Fuji conditioner for 20 seconds. Using a conditioner improves adhesion to tooth tissue. Then the teeth must be rinsed and dried. Next, the contents of various capsules, previously stored in the refrigerator (to increase working time), are shaken sequentially for 10 seconds for optimal mixing of the components. Following this, the material is put into the prosthesis in such a way as to minimize its excess (a layer of material 1 mm thick is sufficient). After this, the crowns must be fixed in the desired position within 30 seconds. Approximately one minute after installation, which corresponds to the gelation phase, excess cement should be removed. Pre-installed dental floss makes it easier to clean areas around bridge pontics. The Isolation must be maintained until the cement has completely cured, which occurs after 4 minutes. The remaining excess cement can be visualized using x-ray; Once they are removed, the patient can finally leave the dental clinic.

SITUATIONAL TASKS

1. An all-ceramic crown is fitted to tooth 22, the color of the crown matches the color of natural teeth. During fixation, a color discrepancy was discovered. What is the doctor's tactics in this situation?

2. The finish line of the prepared tooth 4.6 is located 2 mm below the level of the gingival margin; the dentist made an all-ceramic crown for the patient and used the adhesive method of the orthopedic structure fixation without the use of a rubber dam. Evaluate the doctor's tactics. What complications may arise?

3. After fixation of the zirconium crown on tooth 2.4, the doctor did not remove the excess material for fixation. Evaluate the doctor's tactics. What complications may arise?

4. After receiving the manufactured all ceramic orthopedic constructions from the dental laboratory, the doctor fixated them in the patient's oral cavity without first showing him the work performed. Evaluate the doctor's tactics. What complications may arise?

5. Patient L., 21 years old, came to the clinic with complaints of broken tooth 1.5. The doctor made an all-ceramic crown for tooth 1.5 and fixed it with phosphate cement. Evaluate the doctor's tactics. What complications may arise?

6. Patient F., 33 years old, came to the clinic with complaints about the aesthetic defect of teeth 1.2, 1.1, 2.1, 2.2. A dentist made ceramic veneers for these teeth. After fitting the veneers into the mouth, the doctor fixated them with temporary cement and scheduled the patient for permanent fixation the next day. Evaluate the doctor's tactics. What complications may arise?

LITERATURE

Basic:

1. Removable Partial Dentures. A Practitioners' Manual / Editor Olcay Şakar. – 2nd Edition. – Springer, 2024. – 423 p.

2. Waliszewski, Michael P. Brudvik's Advanced Removable Partial Dentures. Book of Prosthodontics. – 2nd Edition. – UK : Quintessence Publishing, 2022. – 203 p.

Additional:

3. Complete dentures. Algorithm of producing. / S. A. Naumovich [et al.]. – 3rd ed. – Minsk : BSMU, 2018. – 32 p.

4. Fixed dentures. Algorithm of producing. / S. A. Naumovich [et al.]. – 3rd ed. – Minsk : BSMU, 2018. – 30 p.

5. Removable partial dentures. Algorithm of producing. / S. A. Naumovich [et al.]. – 3rd ed. – Minsk : BSMU, 2018. – 16 p.

Electronic courseware for the educational discipline «Non-removable»

6. <https://etest.bsmu.by/course/view.php?id=1401>

LESSON 14

Subject: Errors and complications in the prosthetic treatment of patients with partial defects of the dentition with bridge dentures.

Total time of class – 5 academic hours (200 min).

№	Stages of a practical class	Time in min.
1.	Organizational stage	10
2.	Control of the initial knowledge level	20
3.	Training stage	40
4.	Practicing a practical skill	90
5.	Monitoring the level of the obtained knowledge or mastery of a practical skill	30
6.	Final stage	10

Purpose of the lesson: errors and complications arising in the fabrication of bridges. To teach students how to identify, prevent and solve errors and complications arising at all stages of bridge prosthetics.

Objectives of the lesson:

1. To familiarise with the indications and contraindications for the fabrication of dental bridges.
2. to get acquainted with possible mistakes in orthopedic treatment of patients with partial defects of dental rows with bridges, to master, to consolidate
3. to master the practical skills of fabrication of bridges. 3. to familiarise with the practical skills of fabrication of bridges.
4. to familiarise with errors and complications in orthopedic treatment of patients with partial missing teeth with bridges.
5. To consolidate the acquired knowledge about possible mistakes in orthopedic treatment of patients with bridges.
6. To master practical skills of patient examination, filling in medical documentation.

Class location - the clinical setting.

Practical skills mastered during the class:

Checking the construction of metal bridgework prostheses.

Form of control of the practical class: electronic tests; survey; solving situational tasks.

Place of practical skill implementation – at the outpatient appointment.

Practical skill assessment criteria – according to the assessment sheet (checklist) for monitoring practical skills in the academic discipline in points from 0 to 3.

Requirements for the initial level of knowledge

1. Anatomical structure of teeth on the upper and lower jaws.
2. Morphological changes in tooth tissues after prosthodontics.
3. Clinical material science and laboratory techniques.
4. Management of gingival recessions.

Control questions from related disciplines:

1. Anatomy of the maxilla in age and tooth extraction.
2. Methods of radiological examination of the dento-mandibular system.
3. Alloys used in dentistry and requirements for them.

Control questions:

1. Indications and contraindications for the fabrication of bridges.
- 2 Peculiarities of bridge design.
3. Clinical and laboratory stages of bridge fabrication
4. Advantages and disadvantages of bridge prosthetics.
5. Errors and complications in prosthetic treatment of patients with partial missing teeth with bridges.

The most common errors are: 1) incorrect assessment of the clinical condition of the supporting teeth, 2) error in the selection of the number of supporting teeth, 3) unreasonable expansion of the indications for bridges, 4) violation of occlusal relations with antagonists, 5) violation of the rules for modelling the body of the bridge in relation to the mucosa, supporting crowns, and the height of the masticatory surface cusps, 6) violation of the patient's appearance by an aesthetically disadvantageous prosthesis.

An incorrect assessment of the clinical condition of the supporting teeth is always the result of a superficial examination of the patient, where even gross periodontal changes can be overlooked. The pulp may be necrotic in teeth with fillings, colour retention and stability. The seal created by a full crown may cause a serious complication immediately after the denture is placed or some time later. Support teeth with fillings should be examined radiologically and with an electroodontodiagnostic apparatus.

An error in selecting the number of teeth is due to an incorrect assessment of their functional capacity. It is also usually the result of an insufficiently detailed clinical examination. This error results in overloading of the supporting teeth and their premature destruction.

Expansion of the indications for bridges occurs when the pathogenesis of the developing pathology or the nature of the relationship between the bridge and the tissues of the denture bed, which in this case is the periodontium, is not taken into account. The most common error in which the pathogenesis of the developing pathology is not taken into account is the prosthetic treatment of bilateral inclusion defects of the lateral dentition in the case of a deep underbite. In this type of dentition, as is known, there are no incisor-bump contacts of the anterior teeth. After the loss of some of the lateral teeth, the remaining molars and premolars become overloaded and move vertically. This is followed by a decrease in the interalveolar height and the deep bite becomes a traumatic bite. Prosthetics with bridges using the remaining lateral teeth as support increase their functional overload. The primary traumatic syndrome that develops contributes to a further reduction in bite height. The mistake is as follows. Instead of preventing further lowering of the bite height, bridges create the conditions for further development of the pathological mechanism.

Increasing the bite height on bridges is a gross error that is not difficult to notice. Another error is that the contact between the artificial teeth and their natural antagonists is disturbed (either completely or partially). The functional efficiency of such prostheses is low.

Errors made when modelling the bridge body include the creation of excessively pronounced masticatory cusps, large areas of contact with the mucosa of the alveolar process, lack of sufficient contact area between the denture body and the crowns, which often leads to detachment of the denture body and damage to the mucosa. These are essentially a group of technical errors. They include poor bonding of the prosthesis parts, poor quality moulding (sinks), which can lead to prosthesis breakage. A gross error is deformation of the prosthesis during fusion. In this case, the prosthesis cannot be placed on the supporting teeth: it balances or the artificial teeth do not articulate with their antagonists. The thinning of crowns after careless bleaching or polishing should also be considered a technical error. The metal of such crowns wears out quickly. On the cusps of the chewing teeth or the incisal edges of the incisors, the hard tooth tissue is exposed. Dentures with defective crowns must be removed. Crowns are cut with a wheel-shaped bur No. 5 or special forceps. To protect the gingival margin from damage, a metal spatula is applied to it, then the edges of the crowns in the area of the cut are bent, after which the prosthesis is easily removed with a crown extractor.

Quality assessment of bridge fabrication

Assessment of the quality of the bridge prosthesis:	<ol style="list-style-type: none"> 1. Quality of fabrication of supporting crowns (no defects, anatomical shape, parallel positioning of all supporting crowns). 2. Correctness of the modelling of the intermediate part. 3. Quality of casting of the intermediate part. 4. Quality of bonding of the intermediate part to the prosthetic support elements. 5. Quality of the veneer. 6. Quality of machining and polishing of the denture.
Checking the design of the bridge:	<ol style="list-style-type: none"> 1. The prosthesis must be placed on the supporting teeth. 2. The supporting crowns must fit snugly around the cervicals of the supporting teeth. 3. The prosthesis must not interfere with the interlocking of the teeth in all types of occlusion.
Requirements for the intermediate part of the bridge:	<ol style="list-style-type: none"> 1. Must touch the alveolar mucosa in the anterior region or have a lavage space in the lateral regions. 2. Must not have sharply pronounced cusps at the chewing teeth. 3. Should not have sharp angles. 4. Must have a smooth, polished surface. 5. Must be firmly connected to the supporting crowns.

Checking the construction of an all-metal cast metal bridge framework

Inspection of the all-metal framework in the clinic should begin with a visual assessment of the quality of the casting and its processing by the dental technician. The framework should be free of pores, puffs, defects, undercastings, and should be easy to apply to and remove from the plaster model.

After checking the metal framework is tried on the supporting teeth of the patient. The framework should fit freely, without tension on the supporting teeth and from all sides (vestibular, oral, mesial, distal) to the level specified by the doctor, i.e. to the gingiva or the middle of the gingival groove.

If the supporting crown(s) does not reach the correct level (ledge) in any area or if the framework balances, it should be checked whether the framework is dorsalised on the supporting teeth. This can be done visually, with tracing paper or with a small portion of corrective impression material. The impression material will be pushed in areas that prevent the fit of the crowns. This is used to detect flaws in the preparation of the supporting teeth or technical errors in the casting. In addition, the gingival mucosa should be examined: its pallor indicates elongated margins.

If the framework will be lined with ceramic or plastic, the interocclusal distance between the framework and the opposing teeth must be determined; it must correspond to the thickness of the porcelain liner (1.2 mm). If the denture is not lined, the occlusal contacts are checked. In addition, the relationship between the metal intermediate part of the denture and the mucosa of the alveolar process is checked. There should be a gap of 1.5-2 mm between them. At this clinical stage, the colour of the ceramic lining of the denture is determined in natural light. It is advisable to do this in conjunction with the dental technician, taking into account the wishes of the patient.

Design verification of metal frame with ceramic cladding

When fitting an all-ceramic framework with a ceramic veneer, attention must be paid to:

- unobstructed placement of the denture on the supporting teeth;
- the aesthetic qualities of the prosthesis (colour of the porcelain veneer, shape of the crowns and facets);

- accuracy of the border of the crowns in the vestibular zone;
- the relationship between the intermediate part (body) of the bridge and the underlying mucosa of the alveolar process of the jaw;
- the interocclusal relationship of the prosthesis with the antagonists in central, anterior and transversal occlusion and in all phases of articulation of the dentition.

Errors in the fabrication of stamped-soldered bridges detected during the design verification phase

Mistakes	Reasons	Methods of elimination
Dentures are not superimposed on the supporting teeth.	1. Improper preparation of the supporting teeth. 2. Misalignment of the supporting crowns in the impression. 3. Displacement of the denture elements during fusion.	1. Preparing the supporting teeth. 2. Soldering of the denture, fitting of the supporting crowns, impression taking, fitting of the intermediate part and bonding.
The supporting crown does not fit snugly against the tooth neck.	Incorrectly fabricated crown.	Unsoldering of the denture, fabrication of a new crown, taking an impression of the denture parts and soldering.
The denture enhances the bite on the supporting crowns.	Under-prepared teeth. Incorrectly grafted crowns.	Pre-preparation of the supporting teeth, fabrication of new crowns, fitting, impression taking, fitting of the denture body and fusion of the denture components.
The denture raises the bite on the intermediate portion.	The intermediate portion of the denture is modelled with an elevated bite..	With the help of tracing paper, the places obstructing the movement of the mandible are identified and ground off with vulcanite circles.

SITUATIONAL TASKS

1. When determining the height of the artificial metal-ceramic prosthesis in the masseter, a significant underbite in the central occlusion was detected. What is your tactics?
2. When examining a metal-ceramic bridge supported on 12 and 14, a discrepancy with the anatomical shape of the tooth was found. What is the doctor's tactics?
3. During the examination, a discrepancy in the colour of the metal-ceramic bridge construction with natural teeth was found. What is the mistake? What is your tactics?
4. When determining the height of the artificial metal-ceramic prosthesis in the masseter, an overbite in the central occlusion was detected. What is your tactics?
5. Patient P. complained of mobility of a metal-ceramic bridge supported on 12 and 22, which had been placed the day before. What causes may lead to this complication?
6. Patient K complains of a frequent failure of fixation of an all-alloy denture supported on 45 and 47. What causes can lead to this complication?

LITERATURE

Basic:

1. Removable Partial Dentures. A Practitioners' Manual / Editor Olcay Şakar. – 2nd Edition. – Springer, 2024. – 423 p.
2. Waliszewski, Michael P. Brudvik's Advanced Removable Partial Dentures. Book of Prosthodontics. – 2nd Edition. – UK : Quintessence Publishing, 2022. – 203 p.

Additional:

3. Complete dentures. Algorithm of producing. / S. A. Naumovich [et al.]. – 3rd ed.– Minsk : BSMU, 2018. – 32 p.

4. Fixed dentures. Algorithm of producing. / S. A. Naumovich [et al.]. – 3rd ed. – Minsk : BSMU, 2018. – 30 p.

5. Removable partial dentures. Algorithm of producing. / S. A. Naumovich [et al.]. – 3rd ed. – Minsk : BSMU, 2018. – 16 p.

Electronic courseware for the educational discipline «Non-removable»

6. <https://etest.bsmu.by/course/view.php?id=1401>

LESSON 15

Subject: Types of dental implantation. Indications and contraindications for use. Characteristics of construction materials.

Total time of class – 5 academic hours (200 min).

№	Stages of a practical class	Time in min.
1.	Organizational stage	10
2.	Control of the initial knowledge level	20
3.	Training stage	40
4.	Practicing a practical skill	90
5.	Monitoring the level of the obtained knowledge or mastery of a practical skill	30
6.	Final stage	10

Purpose of the lesson: to teach students the methods of examination of patients when using implants, to teach them to determine the indications and contraindications for implantation. To familiarise students with the varieties of implants.

Objectives of the lesson:

1. to study the varieties of dental implants.
2. To master the practical skills of patient examination in prosthetics of adentia with the use of dental implants.
3. To study the materials used in prosthetics with dental implants.
4. To learn to determine the indications for the use of dental implants.
5. Learn to identify contraindications to the use of dental implants.
6. To master the definition of the tactics of treatment of patients with dental implants.

Class location - the clinical setting.

Practical skills mastered during the class:

Taking alginate impressions.

Form of control of the practical class: electronic tests; survey; solving situational tasks.

Place of practical skill implementation – at the outpatient appointment.

Practical skill assessment criteria – according to the assessment sheet (checklist) for monitoring practical skills in the academic discipline in points from 0 to 3.

Requirements for initial level of knowledge:

1. anatomical structure of the upper and lower jaws.
2. Morphological changes in the bone tissue of the jaws after tooth loss.
3. Clinical material science and laboratory techniques.
4. implant surgery.

Control questions from related disciplines:

- 1: Anatomy of the maxilla in age and tooth extraction. 1.
2. Anatomy of the lower jaw structure in the age aspect and at tooth extraction. 3.
3. Methods of radiological examination of the dento-mandibular system.
4. Alloys used in dentistry and requirements for them.

Control questions:

1. theoretical basis of implantation. Types of osteogenesis in implantation.

2. Characteristics of implants (classification, types of implants).
3. Examination of patients in prosthetic adentia with the use of implants.
4. Requirements to the materials used for implant manufacturing.
5. Indications and contraindications for prosthetics with the use of implants.

C. Mish (1990) proposed a detailed clinically orientated classification of jawbone quality with indication of bone volume and density, as well as the advantages and potential problems of performing dental implantation.

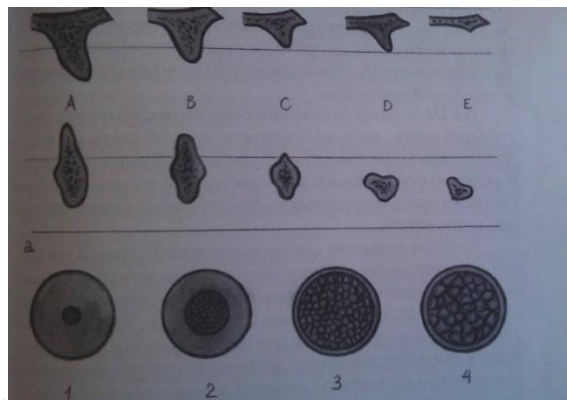
Type D1 - thick compact bone, average bone density on the Hounsfield scale of more than 1250 units (anterior section of atrophic edentulous mandible) provides good initial stability of the implant and a large area of contact with the bony structures, but makes it difficult to prepare the implant site and increases the time of reparative regeneration due to poor blood supply.

Type D2 - thick bone with evenly expressed compact and spongy substance, average bone density according to Hounsfield from 850 to 1250 units (alveolar part of the lower jaw) represents ideal conditions for dental implantation.

Type D3 - Thin bone with porous compact lamina and loose spongy substance, average Hounsfield bone density of 350 to 850 units (alveolar process of the maxilla, good condition after bone grafting) is associated with good blood supply, but the area of contact with mineralised structures is reduced, therefore it is necessary to increase the number of implants and use the method of bone consolidation in the formation of the perceptible bed.

Type D4 - thin compact substance and a layer of very loose cancellous bone, average Hausfield bone density less than 350 units (maxillary tuberosity, satisfactory situation after bone grafting) is considered the most difficult variant for dental implant placement.

A convenient rule for the diagnostic stage in dental implantology is the segmental registration of diagnostic parameters and planned treatment (Mirgazizov M.Z., 2003, Ivanov S.Y. et al., 2003). In this case for the jaw segment of each missing tooth the following parameters are recorded: bone type, parameters of the possible depth of the implant immersion and its width (diameter), as well as the recommended dental construction. In addition, the need for jaw bone reconstruction may be indicated.




Shape types of jaw alveolar processes depending on their atrophy

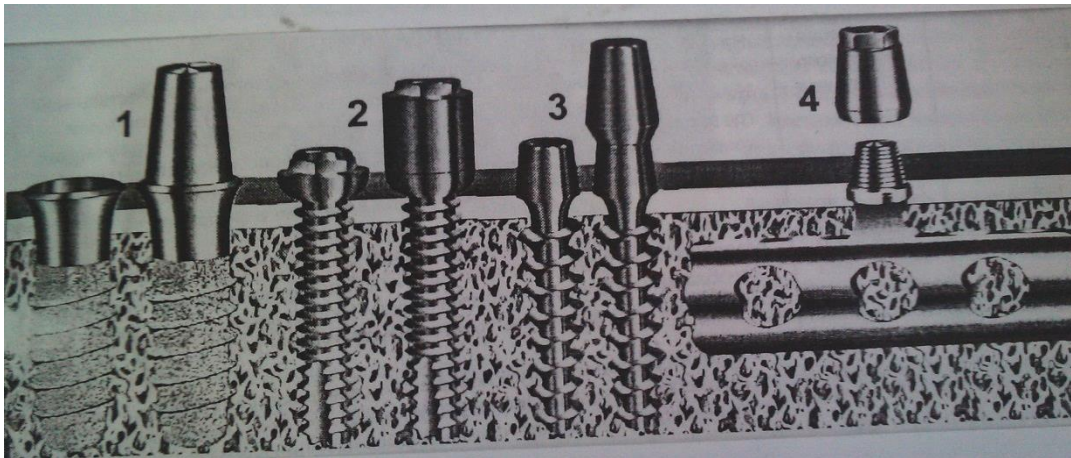
Dynamics of osseointegrated contact formation.

Phase I: healing (reparative regeneration) of the bone tissue of the host site		
Time after surgery	Regeneration stage	Morphological characterisation
0–12 hours	Primary tissue response	Haemorrhage, formation of blood clots in the medullary spaces and in the necrotic zone of the perceptible bed, adhesion of blood cells and plasma proteins (fibronectin and vitronectin) on the implant surface

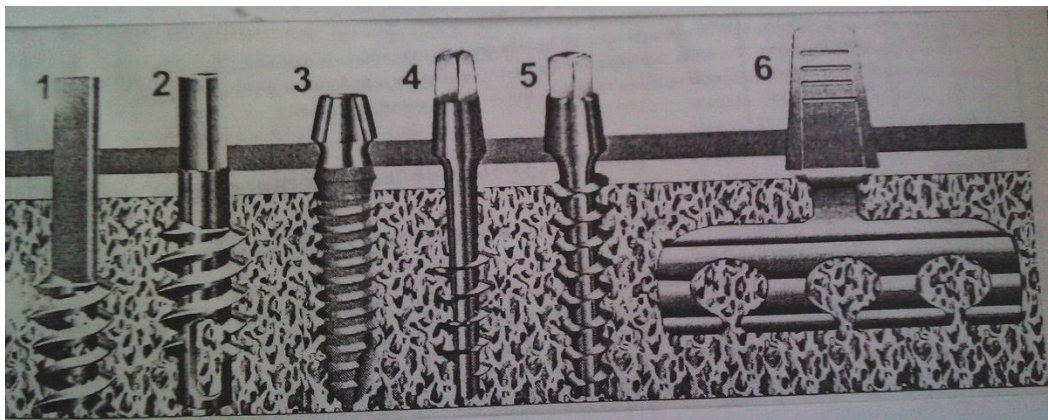
12–48 hours	Acute inflammation	Migration of polymorphonuclear leucocytes and macrophages. Formation of granulations in the medullary spaces and partially in the necrosis zone
2–5 days	Initiation of primary osteogenesis	The beginning of capillary and osteogenic cell proliferation on the periosteal and endosteal surfaces of the bone tissue adjacent to the implant. Differentiation of osteogenic cells into osteoblasts starts in the areas where capillary proliferation is intensive and blood circulation is restored. In areas where blood supply is insufficient, osteogenic cells differentiate into chondro- and fibroblasts
1–3 weeks	Initiation of secondary osteogenesis	Osteons and trabeculae in the necrosis zone undergo osteoclastic resorption. Osteoblasts formed on the endo- and periosteal surfaces of the bone synthesise collagen and connect with osteocytes of viable trabeculae and osteons with their outgrowths
3–6 weeks	Osteoid formation	On the endo- and subperiosteal surfaces, the synthesis of organic bone matrix by osteoblasts is completed and its mineralisation begins. Osteoblasts start collagen synthesis in place of resorbed osteons
6–8 weeks	Completion of reparative regeneration	The osteons and trabeculae of the necrotic zone damaged during surgery are replaced by partially mineralised coarse fibrous bone tissue. The bone healing process is complete
Phase II: structural remodelling (functional regeneration) of the bone		
Time since the start of the function	Regeneration stage	Morphological and functional characterisation
1–2 weeks	Initiation of structural adjustment	Under the influence of functional load, due to piezoelectric and electrokinetic effects on the surface of separate structural elements of bone interacting with the implant, there is an activation of osteoclastic resorption of those parts of osteons and trabeculae, which are represented by coarse-fibrous bone tissue
2–12 weeks	Formation of lamellar bone tissue	In resorbed areas, osteoblasts synthesise collagen fibres, which are oriented in accordance with the load vector and arranged in parallel rows. The synthesis of collagen fibres is followed by mineralisation of the organic matrix
3–18 months	Modification of bone architectonics	In place of resorbed coarse fibrous bone tissue, lamellar bone tissue is formed, which is adapted to functional load. The process of lamellar bone tissue formation is accompanied by reorientation of trabeculae and increase in their volume
До 25 years	Stabilisation of osteogenesis and osteointegration	After the formation of mature bone tissue, there is a resting phase of osteogenesis lasting up to 25 years. This state occurs when the amount of load and the nature of function do not change and the hormones responsible for mineral metabolism control and maintain calcium homeostasis



A



B



C

Design options for intraosseous implants

A - two-stage implants:

- one of the most common in the world is the Branemark screw implant;
- cylindrical IMZ implant with a cushioning system developed by A. Kirsch in 1980;
- one of the first domestic two-stage implants - Smirnov implant with a porous intraosseous part;
- conical screw implant of the "Radix" system.

B - collapsible one-stage implants:

- implant of the Bonefit system with plasma sprayed textured surface of the intraosseous part;
- The latest version of Branemark implants with an intraosseous diameter of 2.5 mm;

- Radix - DM implant with an intraosseous diameter of 2.8 mm;
- Radix-BL plate collapsible implant.

C - non-disposable implants:

- one of the first intraosseous implants, the Chercheve implant;
- screw implant invented 1962 by L. Linkov;
- plasma sprayed textured implants;
- borescope-type implant developed by Tramonte in 1964;
- Radix - I implant with trihedral anti-rotation protection;
- the classic L. Linkov.

Indications and contraindications for dental implantation.

Clinical variants of secondary adentia are indications for dental implantation:

- Absence of one of the teeth in the anterior region;
- Limited inclusion defects of the dentition;
- Terminal unilateral and bilateral defects of the dentition;
- Complete absence of teeth, especially when the height of the alveolar processes is reduced;
- Intolerance to removable dentures due to hypersensitivity to acrylates or in case of a strong gag reflex;
- Lack of functional occlusion and, as a consequence, the occurrence of TMJ dysfunction pain syndrome.

Absolute and relative contraindications to dental implantation are determined in the process of anamnesis collection, identification of patient's complaints and oral cavity examination.

Absolute contraindications:

- General somatic diseases in decompensation stage;
- Myocardial infarction (6 months from the moment of the disease)
- Cerebral circulatory disorder (6 months from the moment of the disease)
- Undergone heart valve replacement surgery;
- Immunosuppression;
- Malignant neoplasms in the maxillofacial region;
- Malignant neoplasms during radiation therapy and chemotherapy;
- drug addiction;
- intravenous administration of bisphosphonates;
- mental illnesses in which the patient is unable to adequately fulfil the recommendations of a medical specialist during and after the treatment.

Relative contraindications:

- allergies to local anaesthetics
- poor oral hygiene
- periodontal diseases in the stage of exacerbation
- smoking, alcoholism
- acute and exacerbation of chronic inflammatory processes of the maxillofacial region
- use of cytostatics
- diabetes mellitus
- autoimmune, rheumatoid and systemic connective tissue diseases
- acute respiratory diseases
- stages of rehabilitation and recovery
- pregnancy and lactation
- jastrophobia, dentophobia

SITUATIONAL TASKS

1. Patient K., 16 years old, complained of gingival trauma in the area of extracted tooth 16. The tooth was extracted 5 years ago. The other teeth of the upper and lower jaw are intact. What type of orthopaedic construction is most acceptable in this situation.
2. Patient A., 27 years old, complained of an aesthetic defect. On examination of the oral cavity, tooth 12 was missing (extracted as a result of chronic granulomatous periodontitis), the other teeth were intact, orthognathic bite. From anamnesis - diabetes mellitus, persistent bruxism. Suggest a plan of orthopaedic treatment to eliminate this defect of the dentition.
3. Patient B., 35 years old, applied for implant prosthetics in the area of the missing tooth 45. The tooth was extracted a year ago. What diagnostic methods should be prescribed and what specialists should be consulted.
4. Patient R. underwent implantation in the area of missing teeth 15,16 with subsequent fabrication of crowns from MC. During what time after prosthetics the functional state of the implants is assessed.
5. Patient P., 55 years old, complained of pain in the temporomandibular joint on the right side. On palpation of the TMJ the pain is on the right side. Palpation of masticatory muscles reveals painfulness of m.masseter,d, m.temporalis,d, m.pterygoideus lateralis.s.,On examination of the oral cavity the absence of teeth 35, 36, 37, 45, 46, 47 was noted. The bite is orthognathic. Diagnosis: TMJ arthrozoarthritis, partial secondary adentia of the lower jaw (Kennedy class I). Suggest a rational orthopaedic treatment plan.
6. Patient S., 25 years old, applied for prosthetics with implants in the area of missing teeth 25,26,27. The teeth were extracted 4 years ago. What diagnostic methods should be prescribed and what specialists should be consulted.

LITERATURE

Basic:

1. Removable Partial Dentures. A Practitioners' Manual / Editor Olcay Şakar. – 2nd Edition. – Springer, 2024. – 423 p.
2. Waliszewski, Michael P. Brudvik's Advanced Removable Partial Dentures. Book of Prosthodontics. – 2nd Edition. – UK : Quintessence Publishing, 2022. – 203 p.

Additional:

3. Complete dentures. Algorithm of producing. / S. A. Naumovich [et al.]. – 3rd ed.– Minsk : BSMU, 2018. – 32 p.
 4. Fixed dentures. Algorithm of producing. / S. A. Naumovich [et al.]. – 3rd ed. – Minsk : BSMU, 2018. – 30 p.
 5. Removable partial dentures. Algorithm of producing. / S. A. Naumovich [et al.]. – 3rd ed. – Minsk : BSMU, 2018. – 16 p.
- Electronic courseware for the educational discipline «Non-removable»
6. <https://etest.bsmu.by/course/view.php?id=1401>

LESSON 16

Subject: Types of dental implants and abutments.

Total time of class – 5 academic hours (200 min).

№	Stages of a practical class	Time in min.
1.	Organizational stage	10
2.	Control of the initial knowledge level	20
3.	Training stage	40
4.	Practicing a practical skill	90
5.	Monitoring the level of the obtained knowledge or mastery of a practical skill	30
6.	Final stage	10

Purpose of the lesson: To study the different types of abutments used for dental implant prosthetics. To teach students to distinguish and apply different types of abutments for different clinical situations.

Objectives of the lesson:

- 1 To study the indications and contraindications for the fabrication of dental implant-supported dentures on different types of abutments.
2. To form the knowledge about the peculiarities of the design of dentures on dental implants with the support on different types of abutments.
3. to master the practical skills of fabrication of fixed dental prostheses on dental implants with the support on different types of abutments.
4. to study errors and complications in the prosthetic treatment of patients with partial absence of teeth with fixed dental prostheses on dental implants supported on different types of abutments.

Class location - the clinical setting.

Practical skills mastered during the class:

Taking dual-layer silicone impressions.

Form of control of the practical class: electronic tests; survey; solving situational tasks.

Place of practical skill implementation – at the outpatient appointment.

Practical skill assessment criteria – according to the assessment sheet (checklist) for monitoring practical skills in the academic discipline in points from 0 to 3.

Requirements for initial level of knowledge:

1. anatomical structure of the upper and lower jaws.
2. Morphological changes in the bone tissue of the jaws after tooth loss.
3. Clinical material science and laboratory techniques.
4. implant surgery.

Control questions from related disciplines:

1. peculiarities of blood supply and innervation of the maxillofacial region. 1.
2. Anatomy of the structure of the upper jaw in the age aspect and at tooth extraction. 3.
3. Anatomy of the structure of the lower jaw in the age aspect and at tooth extraction.
4. Methods of radiological examination of the dento-mandibular system.
5. Alloys used in dentistry and requirements for them.

Control questions:

1. Varieties and characteristics of abutments.
2. Indications and contraindications for the fabrication of dental implant dentures based on different types of abutments.
3. Features of the design of prostheses based on different types of abutments.
4. Clinical and laboratory stages of fabrication of dental prostheses on dental implants supported on different types of abutments.
5. Advantages and disadvantages of prosthetics with the use of abutments.
6. Errors and complications in prosthetic treatment of patients with partial absence of teeth with fixed dentures on dental implants supported on abutments.

An implant consists of two parts - a titanium post, a substitute for the tooth root system, and an abutment, an attachment (adapter) that connects the artificial root to the crown.

Abutment is a metal or, in some cases, plastic cylinder, which is screwed onto the post. The crown is attached to it from above. The endurance and service life of the entire prosthetic structure depends on the abutment

Abutments can be removable elements, in which case they are screwed to the implant, or they can be an integral part of a solid-cast implant. In this case, the attachment is fixedly connected to the

implant head and forms a single structure with it.

Classification according to the type of connection between abutment and implant. The shape and nature of the connection between the abutment and the implant body has made it possible to categorise dental implants (abutments).

- The first variant is the internal hexagon
- Second variant - external hexagon
- Third variant - internal three-channel connection

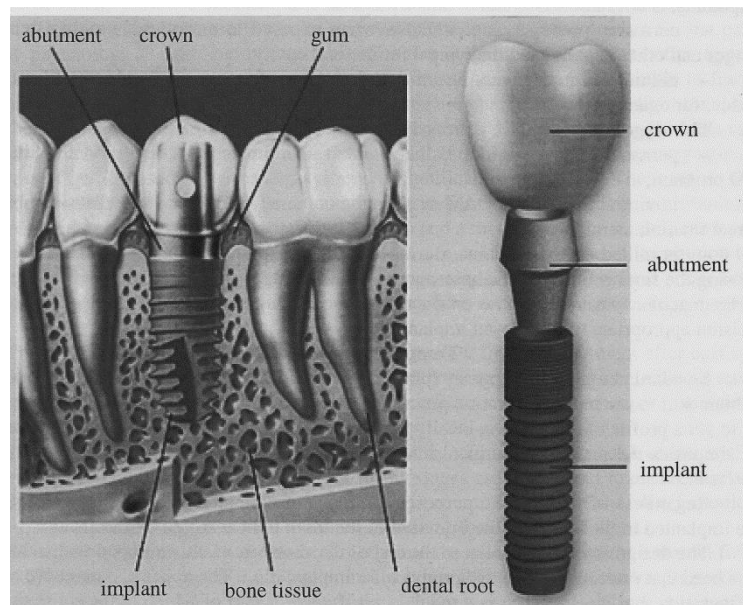
Abutments come in several types:

- Standard;
- Pre-milled abutments
- customised;
- straight;
- angled;
- temporary
- spherical;
- multiunit.

In addition, abutments, their types, are classified by shape, which in turn depends on what orthopedic design on them will be installed. According to this principle, the following types of suprastructures (abutments) are distinguished:

- Universal.
- Individual.
- Angular.
- Globular.
- Temporary
- One-piece.

The most common is the standard abutment. This type of abutment is made according to specific templates and is characterised by a variety of shapes and sizes.



Standard abutment: features

Manufacturers produce a range of standard abutments with different lengths and angles. In this category, there are six lengths and different inclinations (from 20 to 45 degrees) relative to the dental implant.

The advantages of standard abutments include their moderate cost, which has a positive effect on the price of the entire dental implant procedure, and their versatility - they are suitable for most implant techniques.

The disadvantages of this type of abutments include the fact that their diameter is significantly smaller than the crown, which can reduce the quality of its installation. Sometimes titanium shines through the material of the crown, which significantly worsens the aesthetics of the prosthesis.

In some cases, the standard design does not support the gingiva well, and gingival reconstructions may be necessary. Also, the standard abutment shape does not always match the individual tooth shape of the patient, in which case the abutment has to be shaped.

Pre-milled abutments are customised components for prosthetics. The creation process involves milling a cylinder-shaped blank with a finished end for fixation. Automated equipment processes the blank after collecting data on the state of the oral cavity, anatomical features of the patient. The finished part is characterised by high accuracy, the best parameters in terms of grafting and comfort, as well as reliability of operation.

The considered blanks are mainly made of titanium alloy. The metal is characterised by high strength, but it can be translucent in the installed form, as it has a dark tone. Because of this, the aesthetic qualities suffer, so the components are most often used in the chewing teeth area, where titanium shows its strength characteristics in the best way.

Metal also demonstrates:

- excellent resistance to all types of loads, so it is able to serve for a long time even under significant impacts and intensive use;
- complete safety for the patient, because in any conditions does not emit harmful compounds, is not radioactive and retains a constant composition;
- corrosion processes are excluded when exposed to enzymes, humidity, temperature changes and other negative factors typical for the oral cavity;
- titanium is a relatively cheap option compared to some alternatives like zirconium dioxide, for example

The stages of workpiece processing include the following operations:

- personal component for prosthetics is obtained in the process of modelling in a special CAD program;
- in virtual form in the CAM system, the obtained individual structure is combined with the real titanium component;
- is milled on the machine, during which excess material is cut off from the cylinder, exposing the final geometry. The base remains untouched, as the workpiece itself is produced on factory machines that mould the product with a very high quality, machining frequency and precision appropriate to the chosen implantation system.

Temporary abutments

Standard abutments temporary (plastic or titanium) are most often used in dental practice to obtain soft tissue in the restoration process with the desired shape. The use of structures allows you to get a profile of the gingiva, ideally suited for the installation of the crown. In combination, this simplifies the process of surgical intervention, accelerates tissue healing, components take root faster.

Regardless of the specific purpose, abutments are a connecting component between the base implanted in the bone and the imitation of the tooth to be restored - the crown.

The design is simple, similar to the rest of the abutment class, equipped with a threaded tip and a head that protrudes above the gingiva after implantation. The upper part can have a different configuration, but most often it is a regular cap, the lower part of which (adjacent to the tissues) corresponds to the seat of the crown.

Dentists strongly recommend the use of temporary elements when there is a long period of time between tooth loss and the immediate start of implantation. An abutment is needed because the density of the tissue decreases. It is not recommended to implant these structures during the first and third trimester of pregnancy, as well as in case of malignant growths on the oral tissues, tuberculosis and diabetes mellitus. Thanks to cad cam, it is possible to achieve maximum precision in connecting the parts.

There are several forms of temporary details:

- generic, standardised structures that interface with all screw types;
- narrow, suitable for implants up to and including 5 mm in diameter;
- wide, suitable in the case of implantation of bases with a cross-section of more than 5 mm.

Methods of use exist in several variants. In the two-stage technique, it is necessary to wait for the full engraftment of the base, which takes up to 5-6 months. At the stage of implantation of the temporary component, the tissue is incised and the part is screwed in. Permanent parts are installed after obtaining the desired geometry of the gum, which takes from a week to four. The second option involves express implantation, i.e. simultaneous implantation of the temporary component after the base has been installed. The disadvantage of the method is the complexity and a large number of contraindications, it is impossible to work with a large number of pathologies, the patient experiences more stress due to increased stress on the body.

A large number of factors must be evaluated to select the right structure in terms of material, geometry and other characteristics:

- method of installation on the implant
- soft tissue thickness;
- shape and dimensions of the final structure;
- distance between the remaining components of the jaw;
- the required aesthetics of the surgical intervention.

Plastic abutments

Most often, plastic abutments are used in dental restorations using an individualised approach. This way, the best results can be achieved and negative consequences for the patient, including psychological ones, can be excluded. The fact is that plastic elements often appear as temporary, since polymers are not able to last for a long time, are more vulnerable to fractures under increased loads. At the same time, the structures are characterised by a light tone, which allows them to be used even

in the area of the anterior teeth. The shape of the products can be equipped with a hexagon or not have it. Due to the installation in the form of temporary structures, the process of getting used to permanent systems is significantly simplified. The positive side of the products is their low cost, which is not comparable to, for example, zirconium or titanium.

Abutments of this type have a plastic cover cap and a metal base. The models can be fitted with a round seating module, which allows them to be screwed into the base. It is common to use burn-out structures, which are suitable for the casting technique. The last variant is created on the basis of combustible ashless plastic, the upper polymer part is fixed on a metal base created by milling.

The moulded composite blank allows you to create a finished abutment after casting the metal alloy. The heated alloy completely fills the mould, burning out the polymer, a base is retained which is perfect for further procedures. The method is effective and much cheaper than a number of alternatives.

The workpiece itself is shaped using a special modelling wax to achieve the optimum geometry for the specific clinical case. Several fitting stages are carried out to ensure that all the requirements and individual characteristics of the client are met. After the metal mould has solidified, it is also carefully processed to eliminate discrepancies and deviations.

Placement of the resulting abutment directly into the oral cavity requires a certain fixation force. In this case, a torque tool is used, which makes it possible to maintain the torque accurately. For proper fixation, 25-30 N / cm is sufficient. If the element is overtightened, there is an increased risk of breakage due to excessive load, if the abutment is weakened, it may twist during operation. In both cases, a doctor should be consulted as soon as possible to rectify the problems. The use of cad modelling is relevant for the production of individual connecting elements.

Straight abutments

Straight abutments are among the typical components for implantation, they are manufactured by various companies in several shapes and sizes that allow restorations in the simplest cases. These designs are relatively inexpensive, but the exact parameters will depend on a number of factors, such as the chosen material of manufacture and the country of origin.

The parts fulfil a function common to the whole class of products - the connection between the base implanted in the tissue and the crown that replaces the lost tooth. Straight parts are most often suitable for restoring lost components of the mouth in the area of the anterior teeth, however, in complex cases, congenital anatomical features or acquired as a result of trauma, such transitional components will not be suitable.

The material of execution of the products can be the following variants:

- titanium. The metal is very strong and durable, and quite affordable, but translucent on the aesthetic site. It is ideal for restoring teeth in the chewing area. Titanium is not afraid of serious stress, pressure, methodical abrasion, moisture, enzymes, temperature fluctuations and other negative factors that materials encounter in the oral cavity;

- zirconium. The best replacement for titanium, as it allows the restoration of front teeth without loss of performance. The material is light-coloured, so it does not show through, its strength and reliability are on a par with titanium. The only downfall is the excessive price, which is higher than most analogues;

- plastic. Various polymer variants are suitable for restorations, but the components obtained are less strong and durable than those described above. The positive side is the lowest cost compared to alternatives;

- ceramics. The material is often used in situations where individual intolerance does not allow working with other types. The substance does not provoke allergic reactions and allows you to create any shade, for example, to match the tone of preserved teeth;

- combination types. Technicians often work with combined compositions, such as titanium/zirconium, to achieve an optimal combination of performance and aesthetic aspects.

The choice of a suitable variant of components depends on many factors, in particular bone thickness, bite, distance between neighbouring teeth, the angle between the implant and the crown,

aesthetics as a result of the operation, the method of installation, and the budget the client is guided by are evaluated.

An installed abutment can last quite a long time under ideal conditions, however, not every case offers them. Usually, manufacturers guarantee a 5-year period, but the actual figures can be many times longer. Much depends on the condition of the patient's tissues, both bone and soft tissues, the professionalism of the doctor is also very important, for example, when observing the optimal screwing force. In addition, the structure needs to be cared for, which has a positive effect on its service life.

Angled abutments

Angled titanium abutments are a modified form of the straight parts, the difference being that the upper part is angled away from the seating position. Depending on the manufacturing company and the restoration conditions, the ratio can vary, usually the range is 15-45 degrees. The offer of each brand includes several options, which are selected based on the anatomical features of the client. This type of abutment is suitable for restorations in hard-to-reach areas, in complex cases.

The material options are the same as for direct moulds: titanium, zirconium dioxide, ceramics, polymers and combinations of several substances. Common factors for all types are absolute safety for humans. The material does not interact with mucous membranes, enzymes and retains its composition, physical and chemical properties for the entire service life. The strength is maintained at a high level regardless of the inclination, which can serve as a lever that increases the impact for weak materials. The substrate is reinforced, so there is no reduction in performance.

The most common reason for working with such parts is an unusual arrangement of teeth, characterised by anatomical defects, congenital or the results of trauma. Excludes work exacerbation of diseases, inflammatory processes, insufficient bone thickness for reliable fixation of the implant, various pathologies. Existing treatment methods allow you to bypass problems, restore and even build up bone. The variety of materials for particularly sensitive clients makes it possible to choose a substance that will not cause rejection or allergies.

Working with angled abutments is quite difficult, due to the need to carefully analyse the implant conditions and the inconvenience of fixation in some areas due to the geometry of the part. In the end, it is necessary to achieve perfect aesthetics, so that the crown does not protrude in comparison with the main tooth row, it is important to choose a shade characteristic of the preserved parts, or fully corresponding to the natural colour. Soft tissue and bone levels are taken into account, and careful positioning is carried out to achieve the best possible effect. The entire implanted structure is adapted to the bite features.

Aesthetic abutments

Aesthetic abutments are designed, similar to the entire class of materials, to restore masticatory function, diction and appearance. The area where it is most relevant to use these materials is the area that becomes visible in a full smile. The components must match the appearance of natural teeth, exhibit the same colour, as well as functional features when in use.

Obviously, the experts in this case will have to work with the front row, the incisors. This area is considered extremely responsible, if the shortcomings of natural teeth (including lost components) are not eliminated for a long time, it can lead to psychological problems. The patient feels constant discomfort, has to hide the imperfections all the time, which negatively affects the quality of life.

The leading edge is characterised by the absence of increased stresses that act on the implanted structures in the molar area. However, the components used must have sufficient strength to withstand the effects of biting food, regardless of its hardness.

Visually, there is no particular difference with the above described constructions, the abutments act as an adapter between the implant and the crown. The rod has a threaded part, which allows the element to be securely fixed in the implanted base, as well as an apex, the geometry of which is designed to hold the crown of the respective system.

Since aesthetics require careful adjustment to shape and position, the best results are obtained with a customised fabrication approach. The fixation of the structures can be screw-retained or with the use of special cement. Both methods have disadvantages and advantages. Screws are good for

single restorations or forming a series of support elements for bridge systems. Antirotation parts are suitable for a wide range of tasks in dental practice.

When choosing a material for the aesthetic row of teeth, light-coloured materials like zirconia are preferred. Titanium is rarely used in this case, although it is characterised by much greater cost savings. The disadvantage of metal is that it shines through the lighter-coloured components of the construction and can be visible when socialising and smiling.

The spherical abutment

The spherical abutment gets its name because the upper part of the structure resembles a small ball. The models are used to attach conventional removable prostheses, inside which there are sockets framed by rubber rings. When the elements fit into each other, a strong connection is formed.

Advantages of fixation on ball abutments:

- Easy handling
- Simplified prosthetics.
- Easy self-hygiene.
- Very affordable prosthetics for patients.

Disadvantages:

- Weaker denture retention.
- Accelerated wear of the matrix inlays.
- Uneven load distribution between implants.
- Increased soft tissue loading area.

The Multi-unit abutment

The Multi-unit abutment is designed for rehabilitation of complete and partial adentia, and in particular for use in conjunction with the scientifically proven and clinically proven All-on-4 treatment concept.

Multi-unit literally means "multi-unit". Consequently, they are multi-component, complex abutments with several functional elements. An important distinction of Multi-units is the screw fixation.

For your information! The fixation of the prosthetic structure on implants is different:
on cement - abutment and prosthesis are firmly "glued" together;
with screws - the elements are screwed together.

The fixation of the prosthesis on implants with multi-units is carried out exclusively with screws. A through-hole is created in the crown, through which the screw passes. The screw is inserted through the crown to disguise it from above.

SITUATIONAL TASKS

1. Patient K., 16 years old, complained of gingival trauma in the area of extracted tooth 16. The tooth was extracted 5 years ago. The other teeth of the upper and lower jaw are intact. What type of orthopaedic construction is most acceptable in this situation.

2. Patient T., 50 years old, complained of mobility of the prosthetic construction made on implants. The examination revealed micro gaps between the inner surface of the crown and the abutment of the supporting implant. Name the cause of mobility of the prosthetic construction.

3. When taking an impression on the implants the doctor used A-silicone impression material. However, the impression taken did not meet the quality requirements: poor adhesion to the spoon, unclear contours of the natural teeth ledges and marginal gingiva in the implant area. This could be the reason for the poor impression quality.

4. When taking an impression from the implants with divergence in the area of the missing teeth 45, 46 by the direct transfer method, deformation and damage of the impression material occurred. Who made the mistake (doctor or dental technician) and ways of its elimination.

5. Dynamic observation of patient N., 47 years old, after implantation revealed implant mobility in the area of the missing tooth 37. Possible cause of the implant mobility and ways of its elimination.

6. Patient V., 35 years old, applied for prosthetics with implants in the area of the missing tooth 45. The tooth was extracted a year ago. What diagnostic methods should be prescribed and what specialists should be consulted?

LITERATURE

Basic:

1. Removable Partial Dentures. A Practitioners' Manual / Editor Olcay Şakar. – 2nd Edition. – Springer, 2024. – 423 p.
2. Waliszewski, Michael P. Brudvik's Advanced Removable Partial Dentures. Book of Prosthodontics. – 2nd Edition. – UK : Quintessence Publishing, 2022. – 203 p.

Additional:

3. Complete dentures. Algorithm of producing. / S. A. Naumovich [et al.]. – 3rd ed.– Minsk : BSMU, 2018. – 32 p.
4. Fixed dentures. Algorithm of producing. / S. A. Naumovich [et al.]. – 3rd ed. – Minsk : BSMU, 2018. – 30 p.
5. Removable partial dentures. Algorithm of producing. / S. A. Naumovich [et al.]. – 3rd ed. – Minsk : BSMU, 2018. – 16 p.
Electronic courseware for the educational discipline «Non-removable»
6. <https://etest.bsmu.by/course/view.php?id=1401>