

# **COMPLETE DENTURES. ALGORITHM OF PRODUCING**

Minsk BSMU 2018

МИНИСТЕРСТВО ЗДРАВООХРАНЕНИЯ РЕСПУБЛИКИ БЕЛАРУСЬ  
БЕЛОРУССКИЙ ГОСУДАРСТВЕННЫЙ МЕДИЦИНСКИЙ УНИВЕРСИТЕТ  
КАФЕДРА ОРТОПЕДИЧЕСКОЙ СТОМАТОЛОГИИ

# КЛИНИКО-ЛАБОРАТОРНЫЕ ЭТАПЫ ИЗГОТОВЛЕНИЯ ПОЛНЫХ СЪЕМНЫХ ЗУБНЫХ ПРОТЕЗОВ

## COMPLETE DENTURES. ALGORITHM OF PRODUCING

Учебно-методическое пособие



Минск БГМУ 2018

УДК 616.314–77(075.8)-054.6

ББК 56.6я73

К49

Рекомендовано Научно-методическим советом университета в качестве  
учебно-методического пособия 21.03.2018 г., протокол № 7

**А в т о р ы:** С. А. Наумович, С. В. Ивашенко, С. С. Наумович, А. А. Остапович,  
В. А. Шаранда, Е. В. Шнип

**Р е ц е н з е н т ы:** канд. мед. наук, доц. Н. М. Полонейчик; д-р мед. наук, проф.  
Т. Н. Терехова; канд. филол. наук, доц. М. Н. Петрова

**Клинико-лабораторные** этапы изготовления полных съемных зубных протезов = Complete dentures. Algorithm of producing : учебно-методическое пособие / С. А. Наумович [и др.]. – Минск : БГМУ, 2018. – 32 с.

ISBN 978-985-21-0116-5.

Представлены данные и иллюстрации клинико-лабораторных этапов изготовления полных съемных пластиночных протезов.

Предназначено для студентов медицинского факультета иностранных учащихся, обучающихся на английском языке по специальности «Стоматология».

УДК 616.314–77(075.8)-054.6

ББК 56.6я73

ISBN 978-985-21-0116-5

© УО «Белорусский государственный  
медицинский университет», 2018

## MOTIVATIONAL CHARACTERISTICS OF THE TOPIC

Total time of the lesson:

- in the sixth semester, 78 h.
- in 9 semester — 7 h.
- in the 10th semester — 28 h.
- in the email. course — 28 h.

Full adentia is characterized by the absence of all teeth on the jaw. According to different data from the survey of population samples in the Republic of Belarus, it affects 5.2 % of the population aged 55–64, in the age group 65–74 years — 14.7 % and 26 % of the population over the age of 75.

Full secondary adentia causes a violation of the vital function of the body — chewing food, which affects the digestion and the intake of necessary nutrients in the body, and often causes the development of diseases of the gastrointestinal tract of an inflammatory nature. No less serious are the consequences of a complete secondary adentia for the social status of patients: violations of articulation and diction affect the communication abilities of the patient; they, simultaneously with changes in appearance and developing atrophy of the masticatory muscles, can cause changes in the psychoemotional state.

The untimely restoration of the dentition in their total absence (complete adentia) causes the development of such functional disorders as violations of the biomechanics of the dentoalveolar system, the development of various pathological processes in the temporomandibular joint area, rapid atrophy of the bone tissue of the alveolar processes of the jaws.

Causes of complete adentia can be:

1. Disturbances arising during the formation of the dentoalveolar system: Primary complete adentia, caused by the absence of rudimentary teeth.

2. Disturbances associated with loss of teeth in the already formed dentoalveolar system and arising from:

- a) complicated caries;
- b) periodontitis of different etiology;
- c) periodontal disease;
- d) surgical interventions for osteomyelitis, neoplasms;
- e) injuries of various etiologies;

Complete removable full acrylic prostheses are prostheses replacing completely missing dentition, transmitting the chewing load on the underlying mucosa of the oral cavity and bone tissue.

Indications for the manufacturing of the complete removable acrylic prostheses:

1. Complete removable dentures are shown with complete absence of teeth.
2. Can be used as an implant prosthesis for various surgical interventions.

Contraindications to the manufacturing of the complete removable plate prostheses.

**Relative:**

- unsanitary oral cavity (the destroyed teeth and their roots are not removed);
- hypersensitivity or allergic reactions to the components of removable dentures;
- severe decrease in general health condition (myocardial infarction, ischemic heart disease, acute form of hypertension);

Convulsive syndrome (epilepsy) and various psychological diseases;

Complete removable plate prostheses must meet the following requirements:

1. Maximize chewing efficiency for this type of dentures.
2. The base of the prosthesis should be adjacent to the mucous membrane of the prosthetic bed all the way, do not balance.
3. To provide a satisfactory level of fixation and stabilization of the prosthesis in the oral cavity.
4. Restore impaired aesthetic norms, the color of artificial teeth in a removable prosthesis should match the color of natural teeth or meet the needs of the patient.
5. Do not interfere with chewing and speech functions after the adaptation period.
6. The maximal fissure-tubercular contact between the teeth of antagonists and teeth in the complete removable lamina prosthesis should be preserved.
7. Do not block the articulation of the lower jaw.
8. The prosthesis should not have sharp edges, defects that will cause injury to the oral mucosa.

**Purpose:** to study the clinical and laboratory stages of the manufacturing of complete removable acrylic dentures.

**Objective:** To study the clinical and laboratory stages of manufacturing partial complete removable acrylic dentures.

**Requirements for the initial level of knowledge.**

To fully master the topic, the student must repeat from following disciplines:

- human anatomy: anatomical structure of jaws; types of bite; anatomical structure of the TMJ;
- histology, cytology, embryology: morphological features of the structure of bone tissue of the alveolar process of the upper and lower jaws;
- normal physiology: functional changes in the dentoalveolar system with complete defects in the dentition;
- material science: materials and tools necessary for the manufacture of removable plate dentures.

### **Control questions from related disciplines.**

1. Functional anatomy of the dentoalveolar system.
2. Types of bite, the structure of teeth and dentition.
3. Basic and auxiliary materials used for the manufacturing of the removable dentures.

## **EDUCATIONAL MATERIAL**

### **Orthopedic treatment of patients with complete dentition defects with complete removable acrylic dentures**

#### **Clinical and laboratory stages of manufacturing complete removable acrylic dentures**

<b>Clinical stage</b>	<b>Laboratory stage</b>
1. Patient examination. Diagnosis. Treatment plan. The choice of prosthesis design. Obtaining anatomical impressions.	1. Casting working models. Drawing the boundaries of the prosthetic bed. Making individual impression tray.
2. Customization of individual spoons according to the method of Gerbst. Obtainment of functional impressions.	2. Edging of functional impressions, the casting of working models. Drawing the boundaries of the bases of complete removable plate prostheses. Production of wax bases with occlusal ridges.
3. Fitting of wax bases with occlusal rollers in the mouth. Determination and fixation of the central ratio of jaws. Direction for setting artificial teeth.	3. Gypsum models fixation in the occludator or articulator. Selection and setting of artificial teeth on individual anatomical landmarks.
4. Checking the design of wax reproductions of complete removable acrylic prostheses (on the model and in the oral cavity).	4. Final modeling of the basis of complete removable plate prostheses. Replacement of wax for plastic. Processing, grinding and polishing of complete removable dentures.
5. Fit and install complete removable dentures in the oral cavity. Recommendations for care.	
6. Correction of complete removable dentures	

### **Control questions on the topic**

1. Complete loss of teeth (complete secondary adentia). Reasons, prevalence. Patient examination, diagnosis, treatment plan.
2. Functional and morphological changes occurring in the dentoalveolar system with complete loss of teeth.
3. Classifications of the upper toothless jaw according to Schroeder and Kurland.
4. Classification of the lower toothless jaw according to Keller and Kurland.
5. Fixation and stabilization of complete removable prostheses, definition, groups of methods.

6. Anatomical impressions: rules of impression tray selection, spoon types, choice of impression material. Method for obtaining an anatomical impression.

7. Individual spoons: general characteristics, materials for manufacturing.

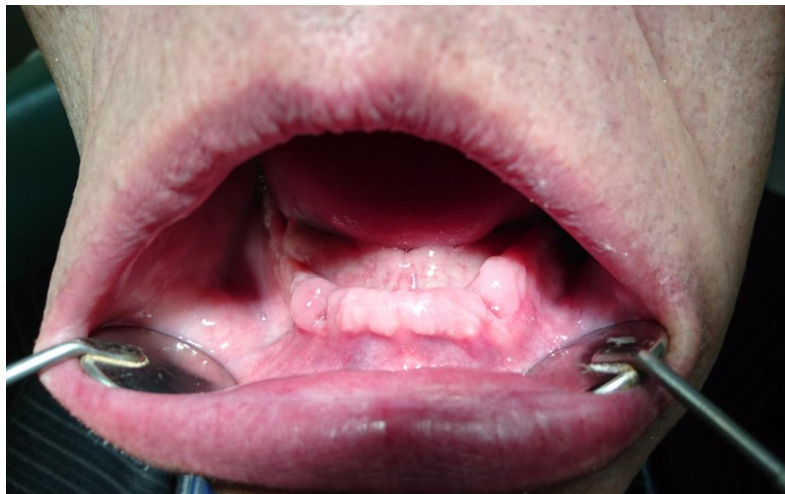8. Functional impression, definition, justification of the necessity of obtaining with complete removable prosthetics.

9. Filling individual spoons according to the method of Gerbst on the upper and lower jaws.

10. Borders of complete removable plate prostheses on the upper and lower jaws.

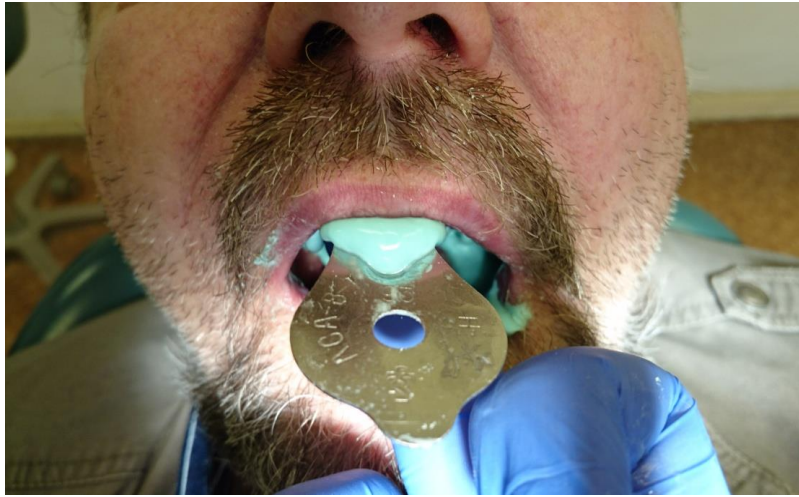
### **Clinical example of clinical-laboratory stages of orthopedic treatment of a patient with complete defects of dentition with complete removable acrylic dentures**

When examining the oral cavity of the patient, complete defects of the dentition on the upper and lower jaws are observed. From the anamnesis of the disease it follows that the patient lost his teeth due to complicated caries and periodontitis. Diagnosed: Complete secondary edentia of the upper jaw of the 1st class according to Schroeder, complete secondary adentia of the lower jaw I class according to Keller. Treatment plan: Restoring the complete secondary adentia of both jaws with complete removable acrylic dentures (fig. 1)

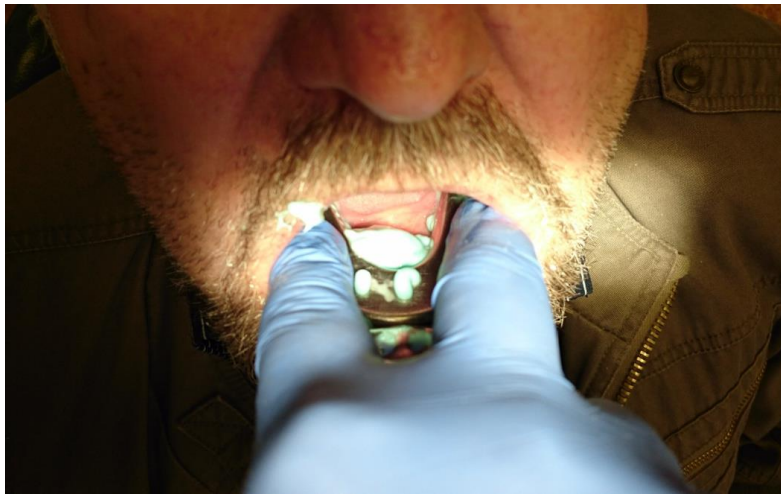


*Fig. 1. Clinical picture of complete secondary adentia of lower jaw*

At the first clinical stage we perform the «taking» of anatomical impressions with an alginate impression mass (fig. 2–4).



*Fig. 2. Anatomical impression from the maxillary*



*Fig. 3. Anatomical impression from the lower jaw*

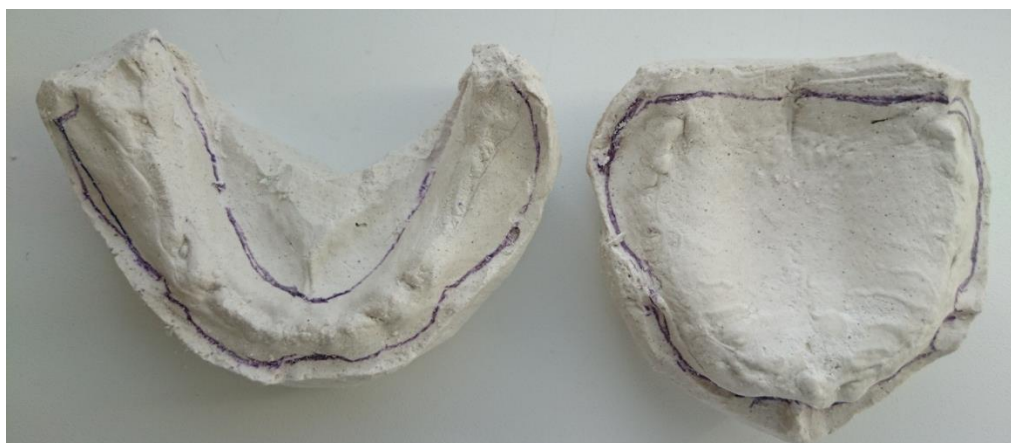

*Fig. 4. Taken (Solidified) anatomical impressions*

In the dental laboratory, the working models are cast, followed by the application/creation of borders and the production of individual impression tray (fig. 5–8).



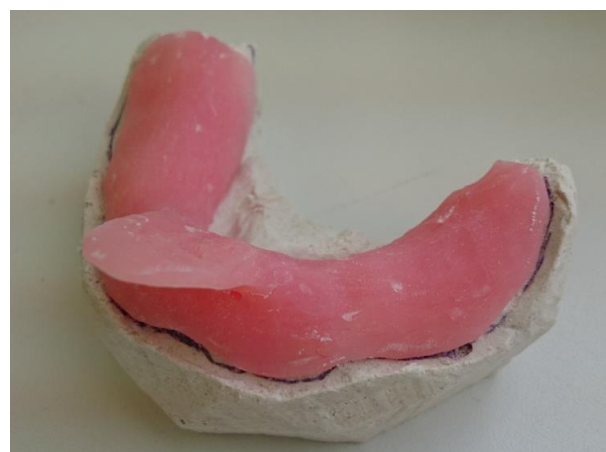*Fig. 5. Pouring of the working model*



*Fig. 6. Ready working model with borders of dentures*



*Fig. 7. The manufactured individual impression tray on the model of the upper jaw*

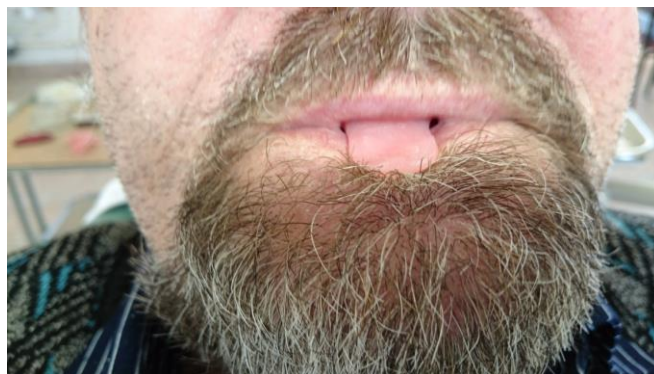

*Fig. 8. The manufactured individual impression tray on the model of the lower jaw*

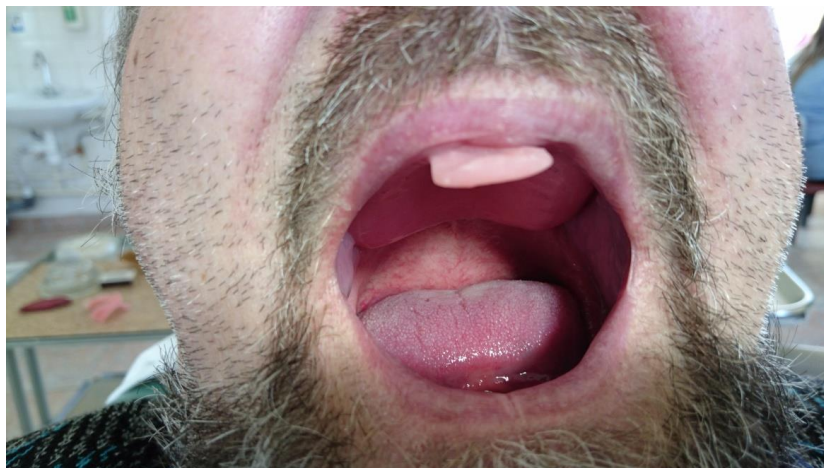Before the taking of the functional impression is carried out, the imposition and fitting of individual trays by a dentist-orthopedist takes place. Preliminarily, the boundaries of individual trays are corrected with the help of samples according to the Gerbst method. When carrying out a certain sample fitting of the impression tray, in the case of violation of the fixation of an individual tray, it is necessary to correct the corresponding zone (fig. 9–20).

### **Customization/Fitting of individual spoons according to the method of Gerbst**

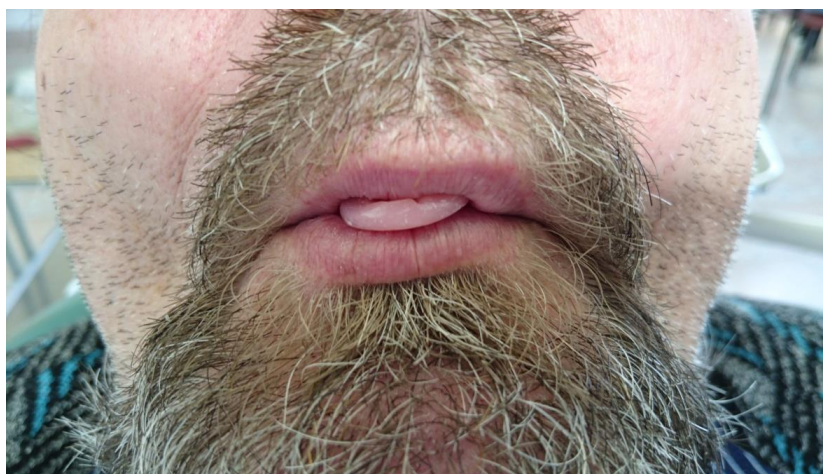
Fitting/Trying in	Zone of correction of an individual tray in case of violation of its fixation
<b>PLACEMENT OF THE CUSTOM IMPRESSION TRAY IN THE UPPER JAW</b>	
1. Swallowing	The distal boundary along the line "A"
2. Wide opening of the mouth	The zone of the maxillary tubercles and the retromolar zone from the vestibular surface
3. Sucking in the cheeks	The vestibular surface on the right and left in the region of the buccal mucocutaneous frenuli
4. Pulling out lips	Vestibular surface in the area of the frenulum of the upper lip
<b>PLACEMENT THE CUSTOM IMPRESION TRAY ON THE LOWER JAW</b>	
1. Swallowing	From the lingual side of the mucous tubercle to the jaw-hyoid line.
2. Wide opening of mouth	If the tray falls out in a broadly opened mouth from the behind, it is shortened from the vestibular side from the mucous tubercle to the projection of the first molar, and if the spoon falls out in the frontal region, it is shortened from the vestibular side between the canine teeth.
3. Place the tip of the tongue along the red vermilion border of the upper and lower lips	Along the mandibulo-lingual line
4. Touch with the tip of the tongue to the cheek with a half-closed mouth	Lingual side from the premolars region
5. Take the tip of the tongue forward towards the tip of the nose	Lingual side from the region of lingual frenulum
6. Tublike pulling out the lips	Vestibular surface between canines



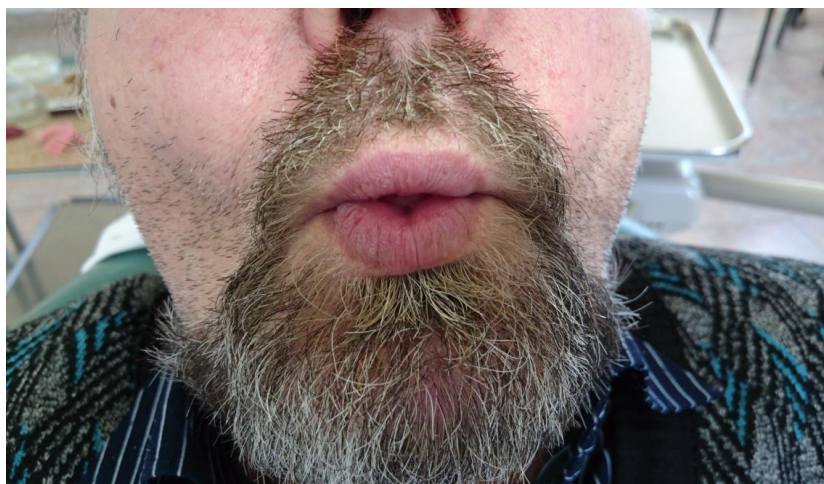
*Fig. 9.* The first test by the method of Gerbst for fitting an individual tray on the upper jaw — swallowing



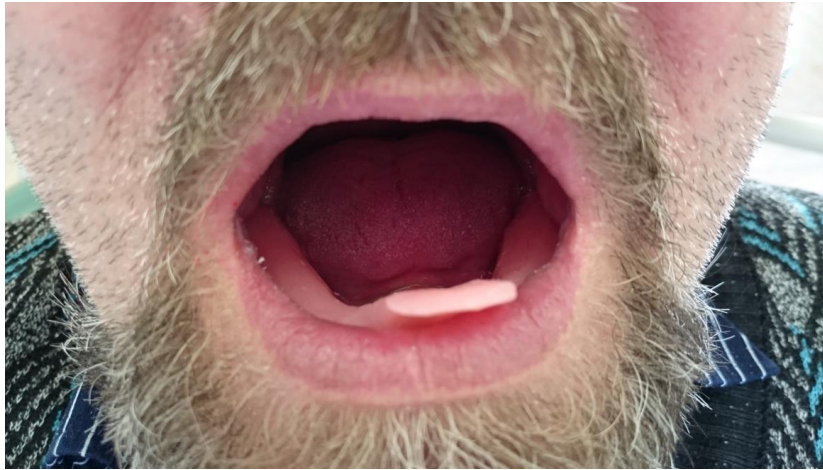*Fig. 10.* The second test — a wide opening of the mouth



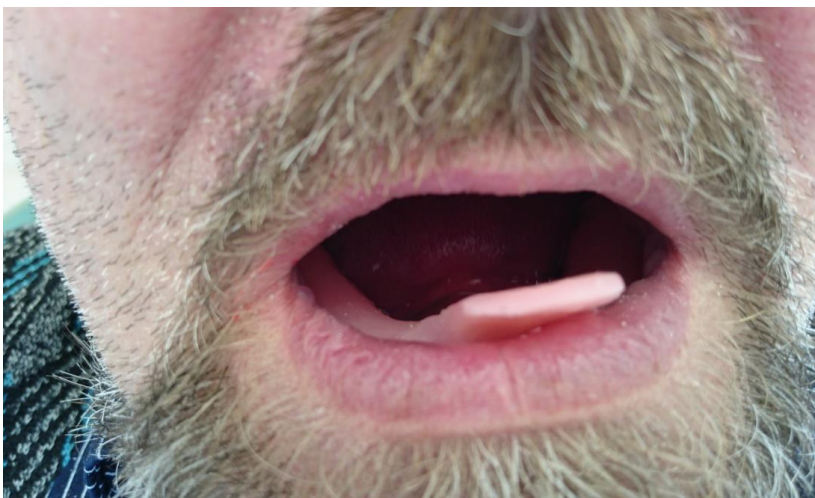*Fig. 11.* The third test — the sucking in of the cheeks



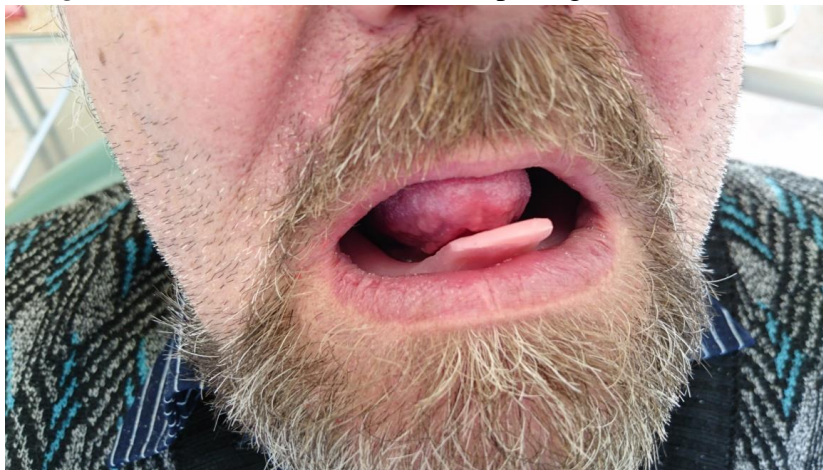*Fig. 12.* Fourth test — pulling the lips with a tube



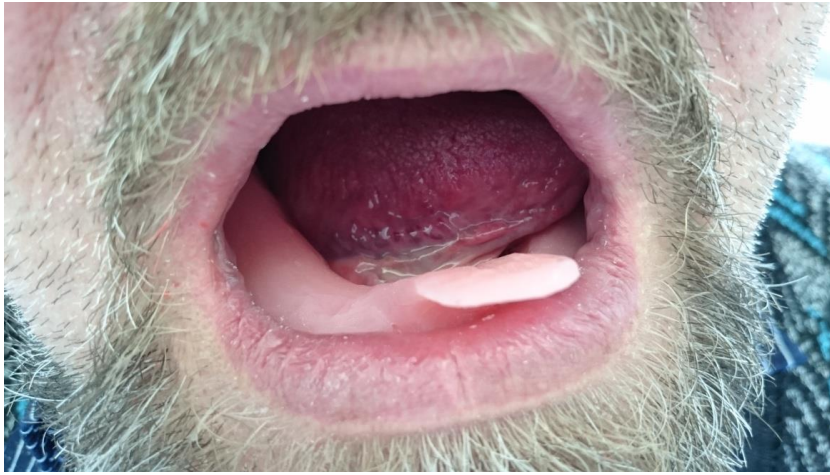*Fig. 13.* The first test for fitting an individual tray on the lower jaw - swallowing.



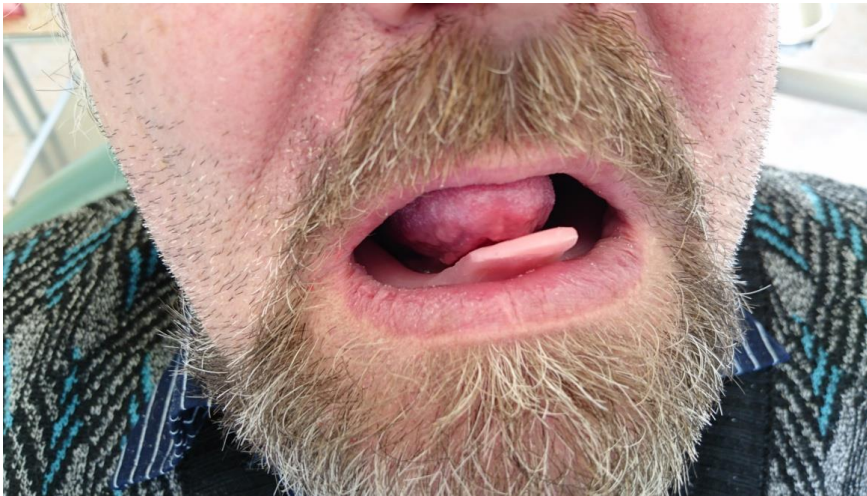*Fig. 14.* The second test — a wide opening of the mouth



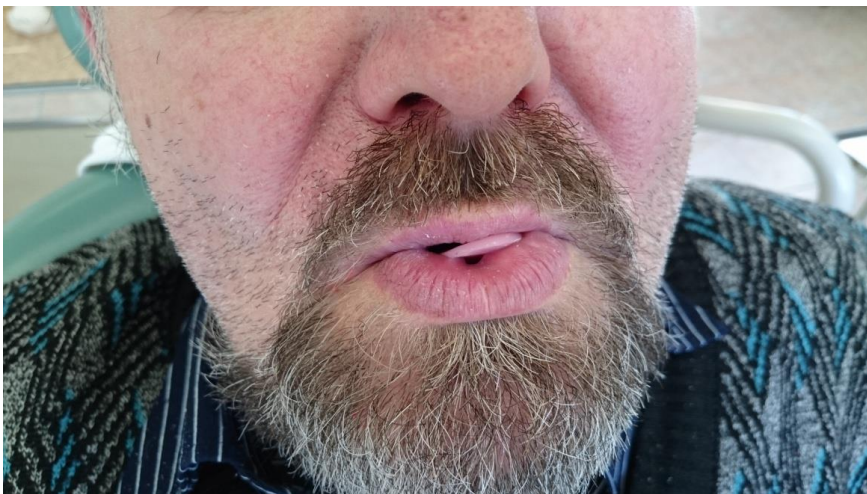
*Fig. 15.* The third test — to hold the tip of the tongue on the red border of the upper and lower lips



*Fig. 16.* Fourth test — touch with the tip of the tongue, the cheek vermillion with a half-closed mouth



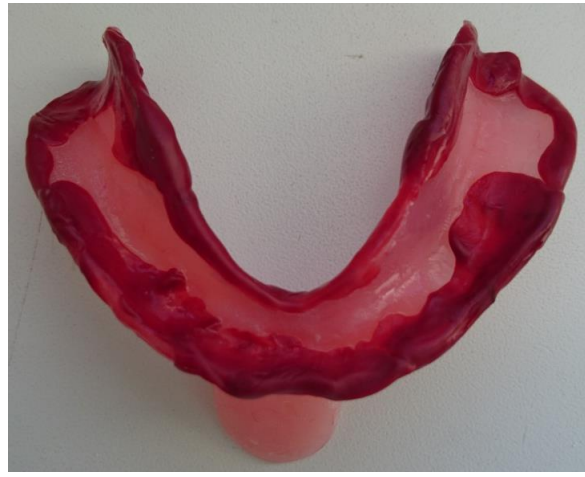*Fig. 17.* Fifth test — stick the tip of the tongue forward towards the tip of the nose



*Fig. 18.* The last test — the tubelike extension of the lips

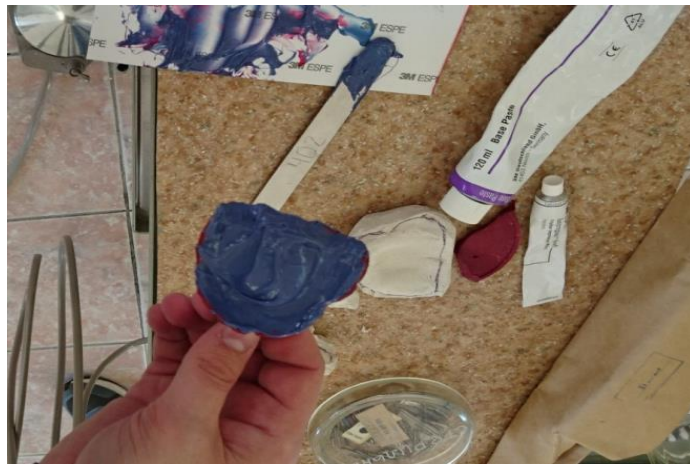

*Fig. 19.* Prepared individual tray before taking the functional impression on the upper jaw

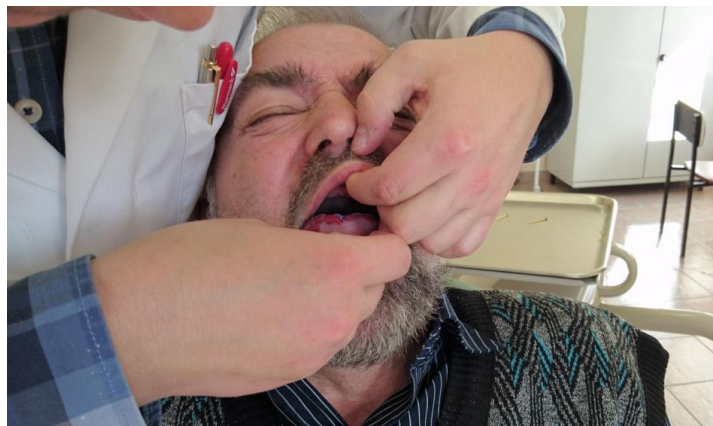

*Fig. 20.* Prepared individual spoon before taking the functional impression on the lower jaw

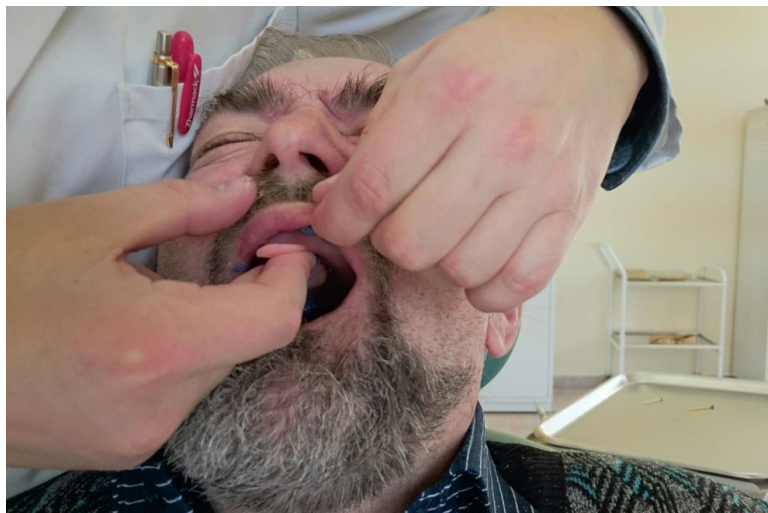At the end of the clinical stage, we perform the removal of functional impressions with polyester impression material using functional tests of Gerbst (fig. 21–27).



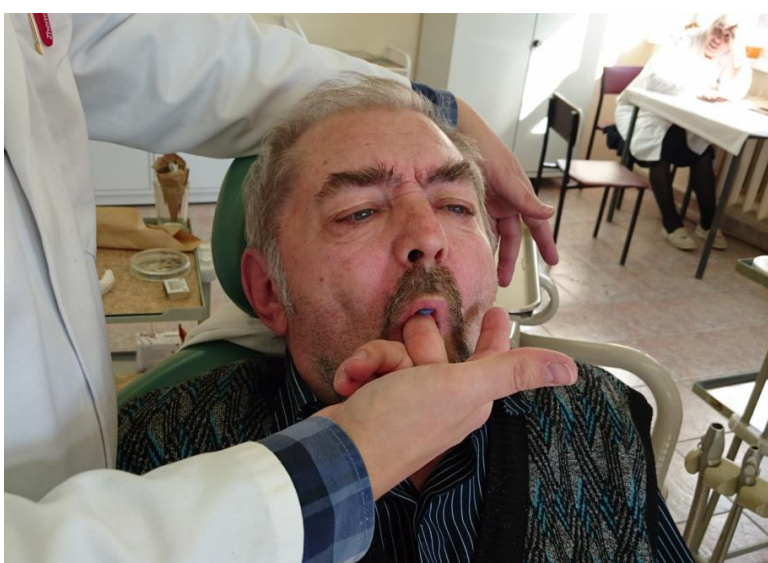*Fig. 21.* Placement of impression material in an individual tray



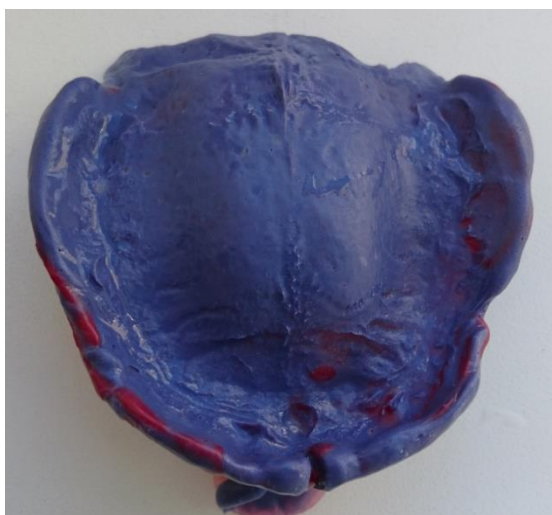*Fig. 22.* Introduction and centering of the functional impression in the oral cavity



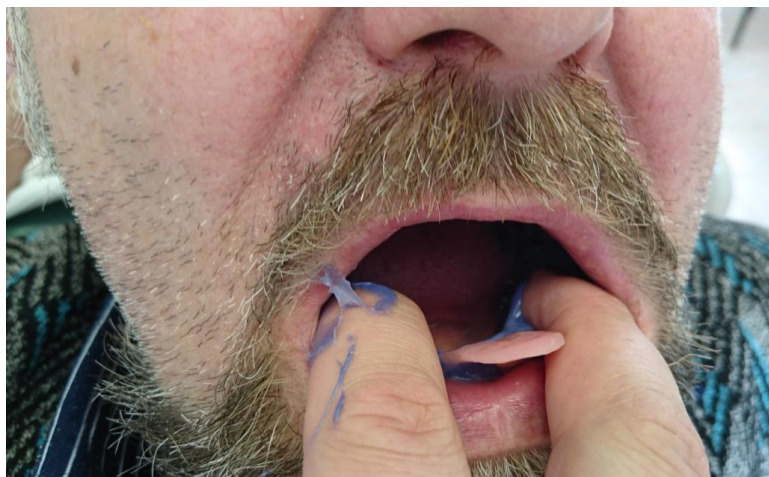*Fig. 23. Removing the functional impression*



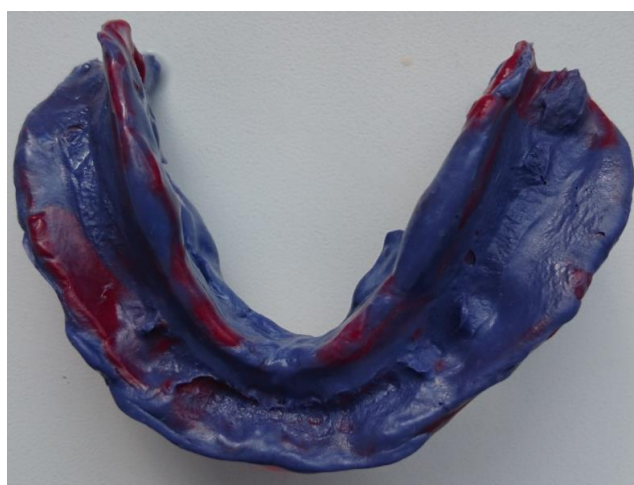*Fig. 24. Fixation of a functional impression in the oral cavity*



*Fig. 25. Functional impression from the upper jaw*



*Fig. 26. Removing the functional impression from the lower jaw*



*Fig. 27. Functional impression from the lower jaw*

Impressions are transferred to the dental laboratory for edging (trimming) and casting working models, fabrication of wax bases with occlusal ridges (fig. 28–33).



*Fig. 28. Edged functional impression of the upper jaw*




*Fig. 29. Edged functional impression from the lower jaw*



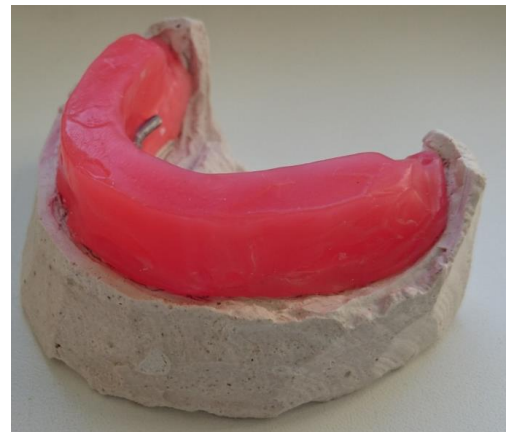*Fig. 30.* Working models are cast



*Fig. 31.* Working models with created edges of complete removable acrylic prostheses



*Fig. 32.* Wax base with occlusal ridge on upper jaw model



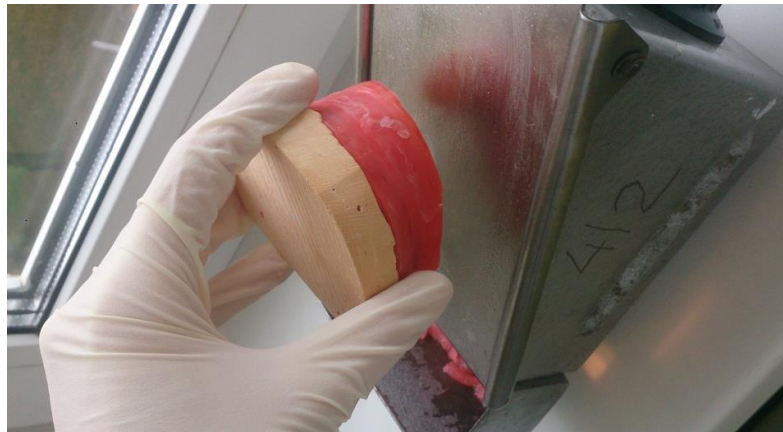*Fig. 33.* Wax base with an occlusive ridge on the model of the lower jaw

At the next clinical stage, the doctor determines the height of the lower part of the face (anatomical and physiological method), wax bases with occlusal ridges are fitted. The prosthetic plane of the wax base with the occlusal ridge on the upper jaw is determined with the aid of the Larin apparatus, formed by the

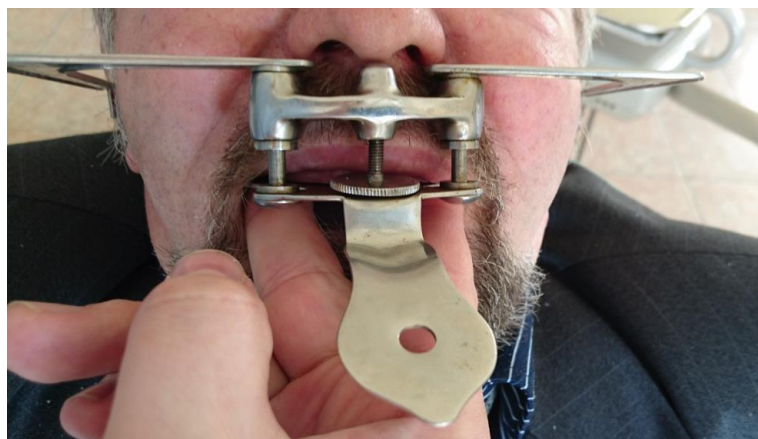apparatus of Naysh (electric heating device). The prosthetic plane in the lateral sections is parallel to the naso-auric line, and in the frontal one — to the interocular. Then, a wax base with an occlusal roller is placed on the lower jaw (between the occlusal rollers, the maximum tight contact must be made). The position of the central ratio of the jaws is determined and fixed (fig. 34–46).



*Fig. 34.* Measurement of the height of the lower part of the face in a state of physiological rest



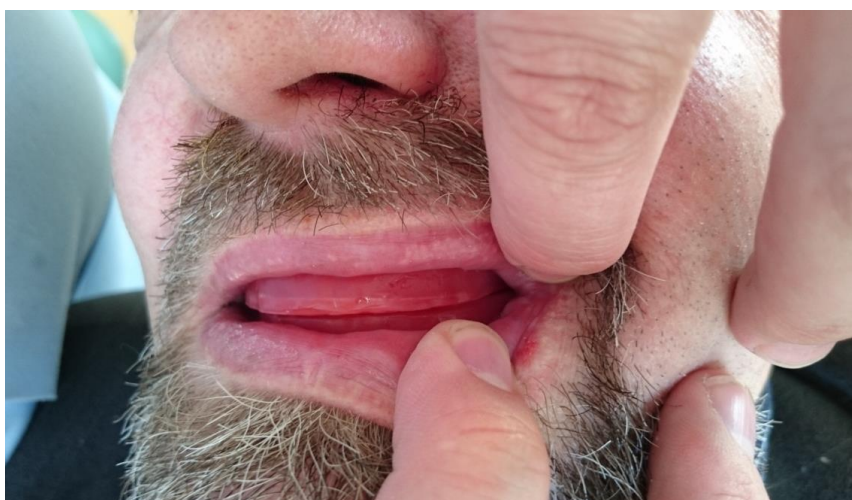*Fig. 35.* Formation of the prosthetic plane with the aid of the apparatus Naysh (electro-heating device)



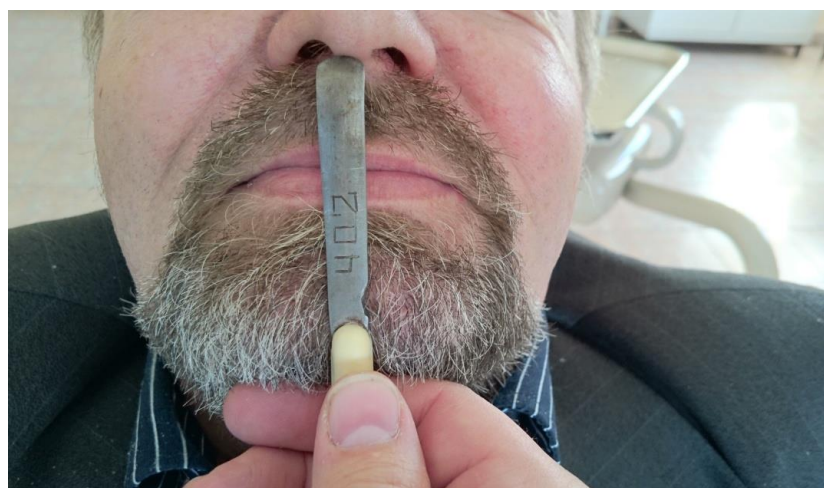*Fig. 36.* Determination of the prosthetic plane in the frontal compartment with the help of Larin's apparatus



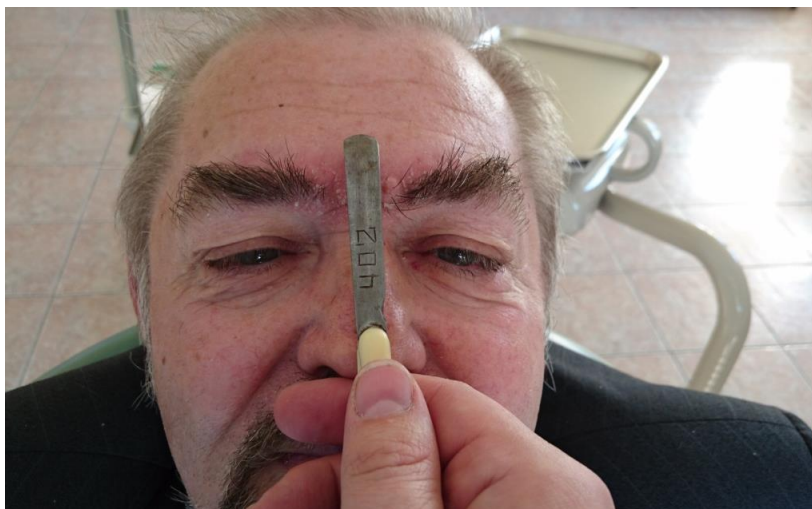*Fig. 37.* Determination of the prosthetic plane in the side section with the aid of Larin's apparatus



*Fig. 38.* Wax base was completed with occlusal ridges on the lower jaw



*Fig. 39.* Measurement of the height of the lower third of the face with closed wax bases with occlusal ridges



*Fig. 40.* Comparison of the height of the lower third of the face with the height of the middle third of the face



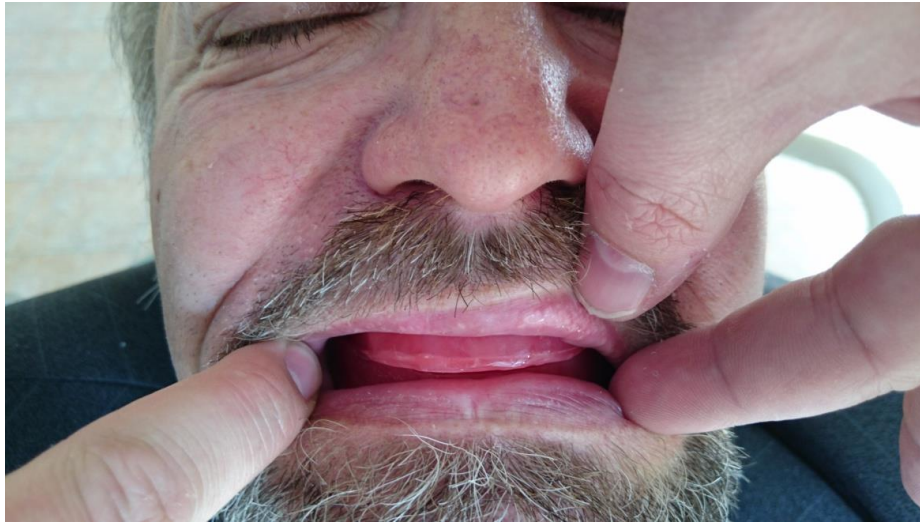*Fig. 41.* Cross-shaped incisions on the occlusal ridge of the upper jaw before fixing the central ratio



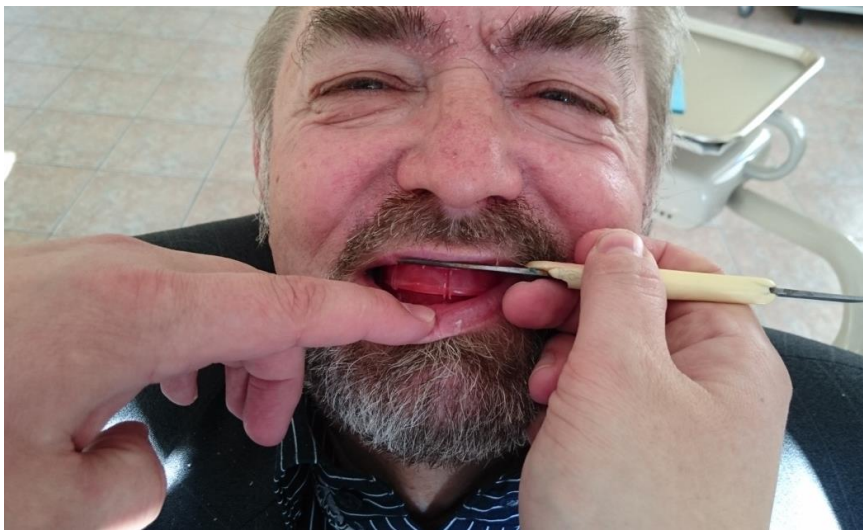*Fig. 42.* In the prepared grooves on the lower occlusal roller, plates of the base wax are applied




*Fig. 43.* Softening of the plates of the base wax on the occlusal platen of the mandible



*Fig. 44. Fixing the position of the central ratio of jaws*



*Fig. 45. Application of anatomical landmarks for setting artificial teeth*



*Fig. 46. Wax bases with occlusal ridges after determining the position of the central ratio of jaws on working models*

At the next laboratory stage, the working models are plastered into the occludator or articulator. Artificial teeth are selected according to size, color, shape, shape and group affiliation, followed by setting on wax bases (fig. 47, 48).

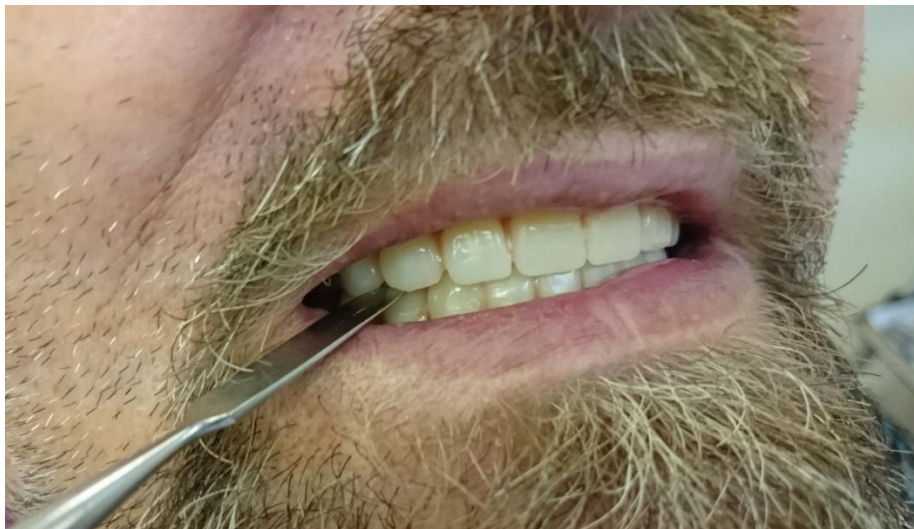

*Fig. 47.* Models are plastered (fixed) into the occludator

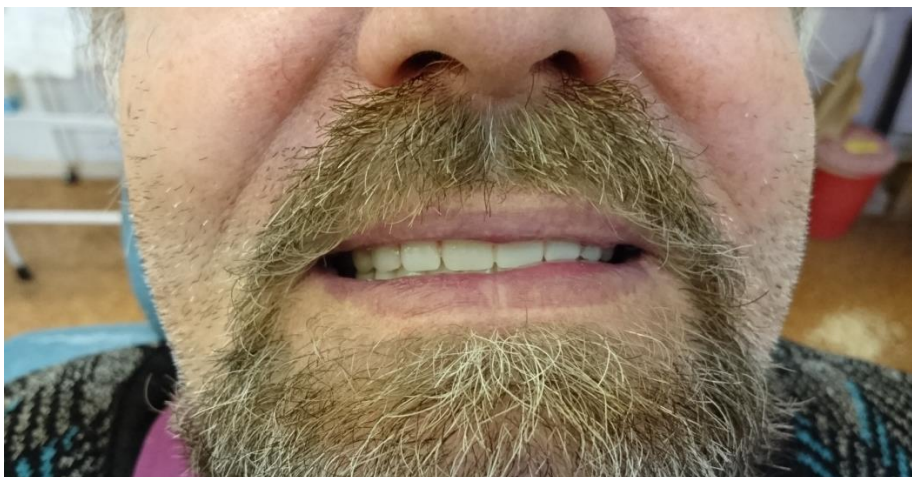

*Fig. 48.* Selection and setting of artificial teeth

At the clinical stage, the wax reproduction design of complete removable plate prostheses is checked to identify all possible errors that could have been committed at previous clinical and laboratory stages of manufacture. The tightness of the teeth is achieved by moving the dental spatula between them (fig. 49, 50).

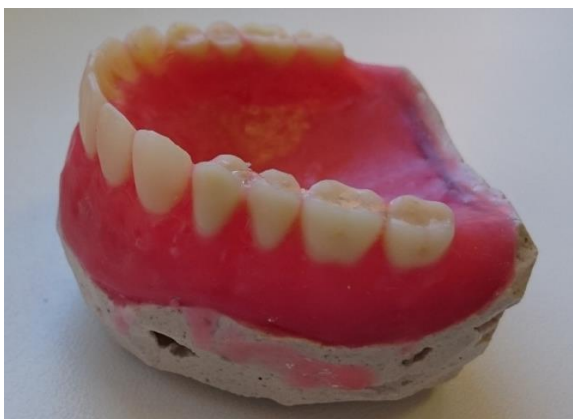

*Fig. 49.* Checking the tightness of the dentition.

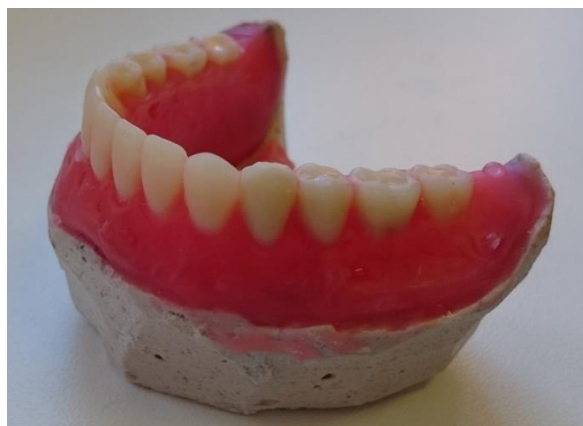

*Fig. 50.* Verification of the wax reproduction design of complete removable plate prostheses

At the last laboratory stage, the final wax bases of complete removable plate prostheses are made. Gypsovka them in a cuvette by the reverse method to replace wax with acrylic plastic hot polymerization (fig. 51–55).



*Fig. 51.* The final wax base modelling of the complete removable acrylic prosthesis on the upper jaw was performed



*Fig. 52.* The final wax base modelling of the complete removable acrylic prosthesis on the lower jaw was performed



*Fig. 53.* Gypsum model with wax reproduction of a complete removable plate prosthesis in the upper part of the flask



*Fig. 54.* Installation of the bottom of the flask and filling it with gypsum

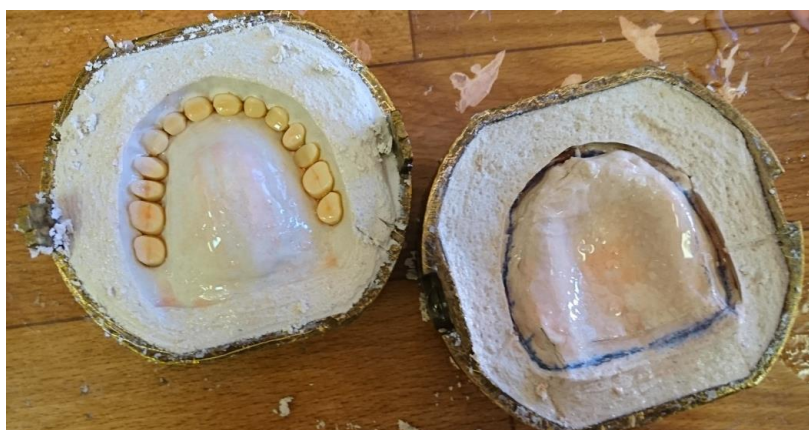

*Fig. 55.* Installation of the flask under press for extruding gypsum

After the gypsum solidifies, the cuvette is placed in clean boiling water until oil stains appear on the surface of the water to melt the wax from the mold of the cuvette. Then the cuvette is opened into two halves, excess waxes are removed and the wax residues are removed from the gypsum surface by a jet of boiling water (fig. 56–58).



*Fig. 56.* Opening of the hot flask after melting the wax



*Fig. 57.* Opened flask during wax removal

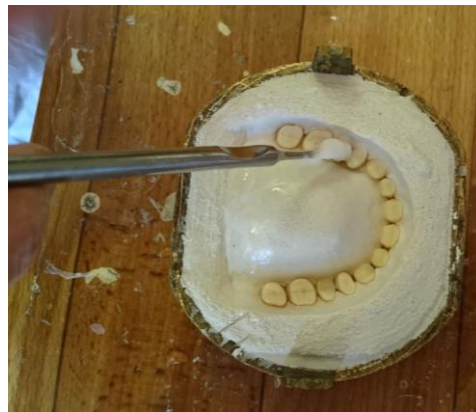

*Fig. 58.* Removal of wax residues from the cuvette by a hot water jet

After the inner part of the cuvette has been cleaned of the wax residues, the gypsum surface is covered with an insulating lacquer «Izokol» twice. For the first time, cover immediately when the cuvette is hot. The second time — when the cuvette cooled to room temperature. Before the plastic dough is inserted into the mold, the artificial teeth are degreased with a monomer of acrylic plastic of hot polymerization (fig. 59, 60).



*Fig. 59.* Processing models in the flask with an insulating varnish



*Fig. 60.* Degreasing artificial teeth with a monomer

Further preparation of acrylic plastic of hot polymerization is carried out and its packing on a dough-like stage in a cuvette press mold under the press and fixing them in a two-cell clasp (fig. 61–64).



*Fig. 61.* Preparation of acrylic plastic hot polymerization



*Fig. 62.* Packing the plastic dough into the mold of the flask



*Fig. 63.* Flask under the press for extruding plastic

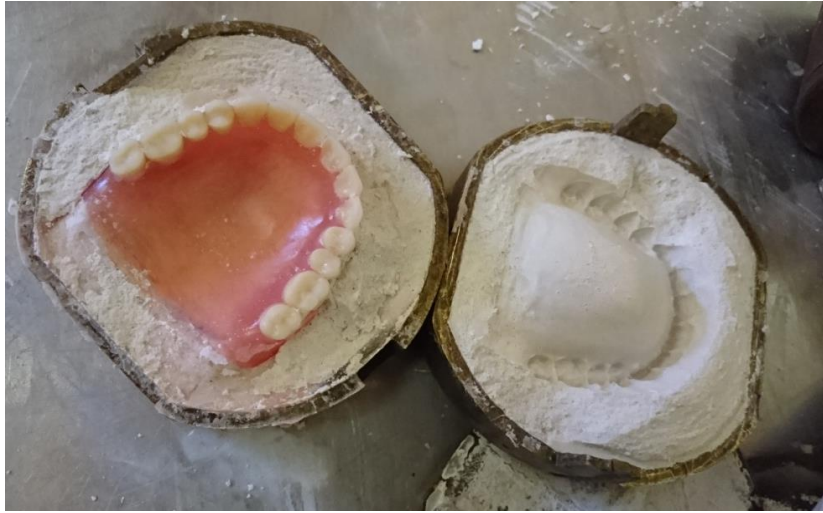

*Fig. 64.* The cuvettes are fixed in a two-cell clasp

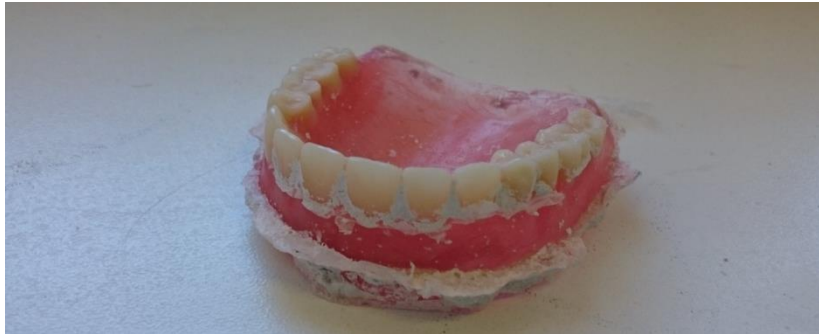Further polymerization of acrylic plastic is carried out in the polymerizer. The polymerization regime is as follows: 60 minutes water from room temperature is brought to a boil, followed by 60 minutes in boiling water. After the polymerization of the plastic, the cuvette is opened, the plate prostheses are conditioned from the gypsum and extracted. Formation of the boundaries of the bases is carried out by an emery circle. Rough treatment of the prosthesis is carried out with mills of various abrasiveness and carborundum grinding heads. Then grind the sandpaper on the paper holder from larger to finer with a grinding motor. Then polish the prosthesis with felt wheels and hard bristle brushes using polishing agents (pastes, powders, liquids) (fig. 65–72).



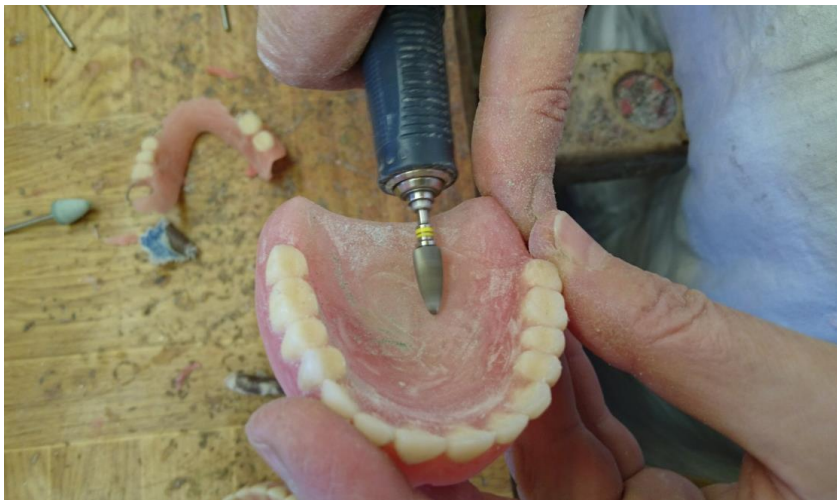*Fig. 65.* Polimerizator of plastic



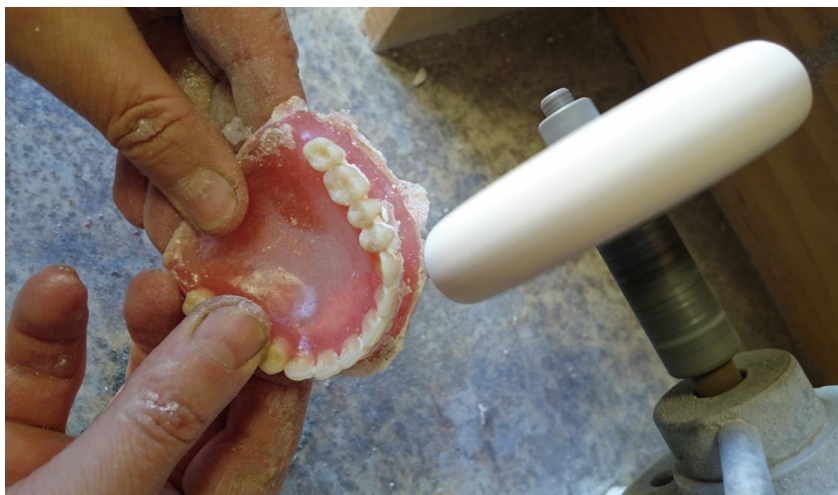*Fig. 66.* Open flask after polymerization of plastic



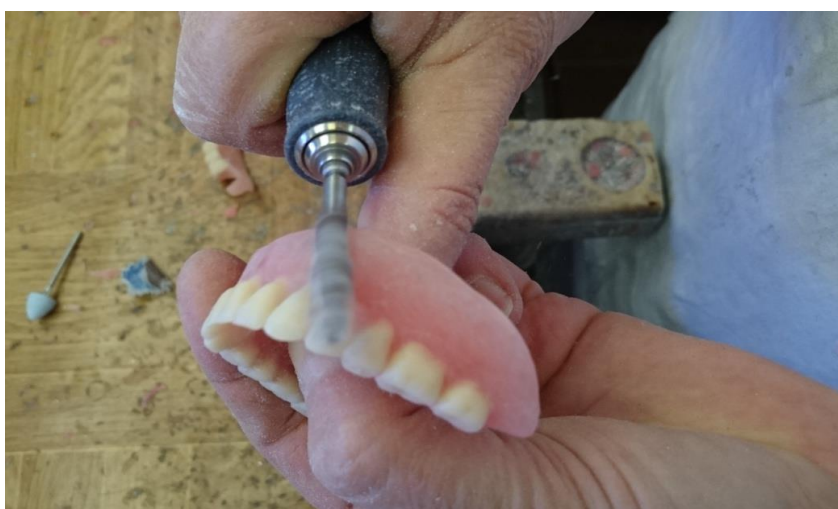
*Fig. 67.* Prosthesis after removal from the flask



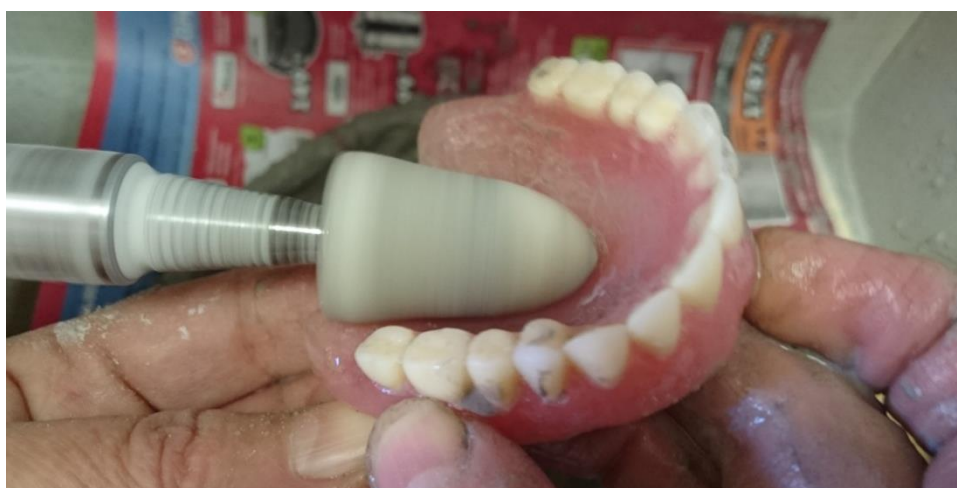*Fig. 68.* The formation of the boundaries of the prosthesis emery circle



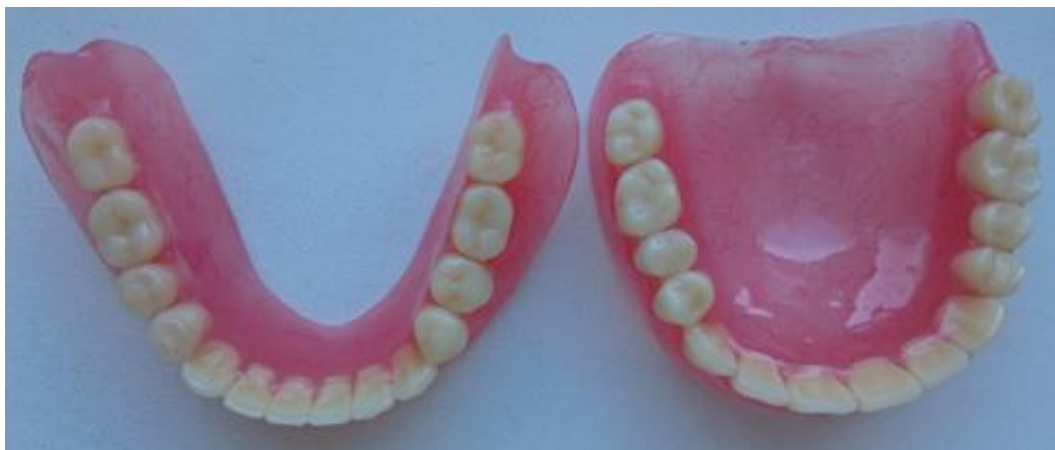*Fig. 69.* Treatment of the plate prosthesis with a milling cutter



*Fig. 70.* Sanding the prosthesis with abrasive paper on the paper holder

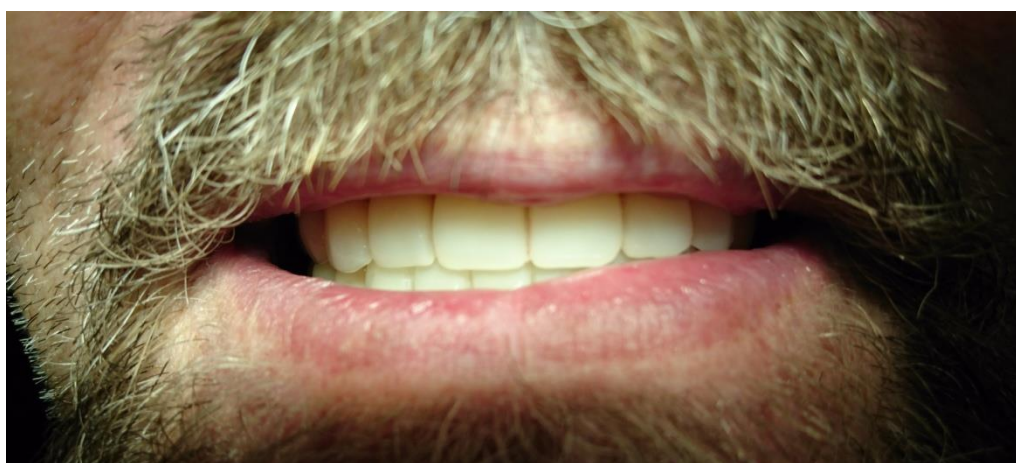


*Fig. 71.* Polishing the prosthesis with a felt head

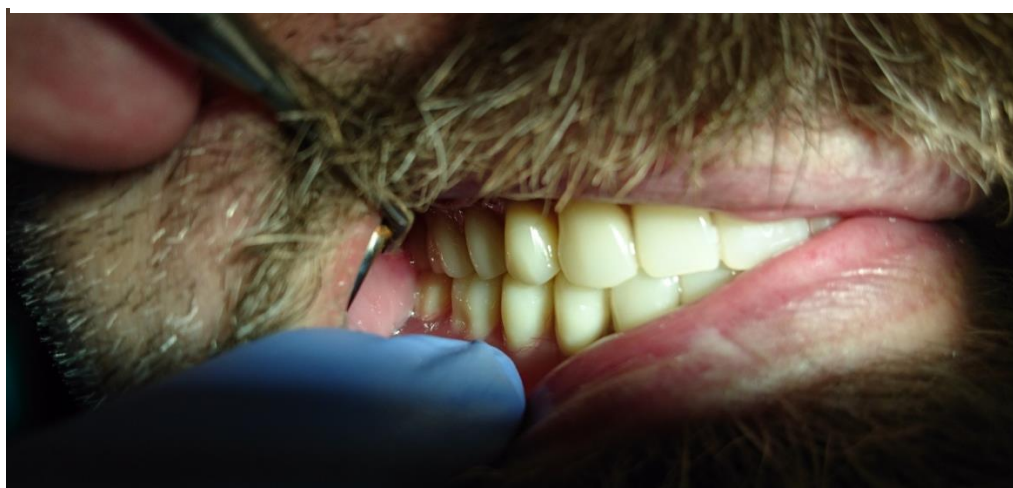

*Fig. 72. Complete removable acrylic dentures*

Complete removable acrylic prostheses at the subsequent clinical stage are pinned and placed in the oral cavity. Give advice to the patient on the care and correction of prostheses. Teach the rules of use (fig. 73, 74).



*Fig. 73. Complete removable acrylic prostheses in the oral cavity, front view*



*Fig. 74. Complete removable acrylic prostheses in the oral cavity, side view*

## LITERATURE

1. *Nallaswamy, D.* Textbook of Prosthodontics : Textbook / D. Nallaswamy, K. Ramalingom, V. Bhat. Jaypee Brothers, Medical Publishers. 2004/ 842 p.
2. *Stephen, F.* Contemporary Fixed Prosthodontics, Fourth edition : Textbook / Stephen F. Rosenstiel, Martin F. Land, Junhei Fujimoto, Elsevier Inc. 2010/ 940 p.
3. *Fundamentals of Fixed Prosthodontics* / Herbert T. Shillingburg [et al.]. Quintessence Publishing. 2008. 574 p.
4. *Prosthodontic Treatment for Edentulous Patients* / George Zarb [et al.]. Elsevier. 2014. 466.
5. *Полонейчик, Н. М.* Оттисковые материалы = Impression materials : учеб.-метод. пособие / Н. М. Полонейчик, К. И. Чистик. Минск : БГМУ, 2017. 39 с.

## CONTENTS

Motivational characteristics of the topic .....	3
Educational material .....	5
Literature.....	30

Учебное издание

**Наумович Семён Антонович**  
**Ивашенко Сергей Владимирович**  
**Наумович Сергей Семёнович и др.**

**КЛИНИКО-ЛАБОРАТОРНЫЕ ЭТАПЫ  
ИЗГОТОВЛЕНИЯ ПОЛНЫХ СЪЕМНЫХ  
ЗУБНЫХ ПРОТЕЗОВ**

**COMPLETE DENTURES.  
ALGORITHM OF PRODUCING**

Учебно-методическое пособие

На английском языке

Ответственный за выпуск С. А. Наумович  
Переводчики В. А. Шаранда, А. А. Остапович  
Компьютерная верстка А. В. Янушкевич

Подписано в печать 21.08.18. Формат 60×84/16. Бумага писчая «Хероx office».  
Ризография. Гарнитура «Times».

Усл. печ. л. 1,86. Уч.-изд. л. 1,31. Тираж 99 экз. Заказ 613.

Издатель и полиграфическое исполнение: учреждение образования  
«Белорусский государственный медицинский университет».  
Свидетельство о государственной регистрации издателя, изготовителя,  
распространителя печатных изданий № 1/187 от 18.02.2014.  
Ул. Ленинградская, 6, 220006, Минск.

ISBN 978-985-21-0116-5



9789852101165