

МИНИСТЕРСТВО ЗДРАВООХРАНЕНИЯ РЕСПУБЛИКИ БЕЛАРУСЬ  
БЕЛОРУССКИЙ ГОСУДАРСТВЕННЫЙ МЕДИЦИНСКИЙ УНИВЕРСИТЕТ  
КАФЕДРА ОРТОДОНТИИ

# ОБЩАЯ ОРТОДОНТИЯ

# GENERAL ORTHODONTICS

Учебно-методическое пособие



Минск БГМУ 2019

УДК 616.314-0809.23(075.8)-054.6  
ББК 56.6я73  
О-28

Рекомендовано научно-методическим советом университета в  
качестве учебно-методического пособия 21.06.2019 г., протокол №10

**А в т о р ы:** д-р мед. наук, проф. И.В. Токаревич; канд. мед. наук, доц.  
А.О. Сакадынец; асс. О.Л. Коваленко; асс. А.П. Полещук; асс. С.А.  
Ушакова; асс. А.С. Хомич.

**Р е ц е н з е н т ы:** зав. каф. стоматологии детского возраста, д-р мед.  
наук, проф. Т.В.Терехова; зав. каф. общей стоматологии, канд. мед. наук,  
доц. Н.М. Полонейчик

**Общая ортодонтии =General orthodontics : учеб.- метод О-28 пособие /**  
И. В. Токаревич [и др.]. – Минск: БГМУ, 2019. – 90 с.

Описаны основные и некоторые дополнительные методы  
исследования, используемые в ортодонтии – клинический,  
функциональный, рентгенологический. Кроме этого рассмотрены общие  
принципы и методы лечения зубочелюстных аномалий в различные  
периоды формирования прикуса. Кратко характеризуются основные виды  
аппаратов, используемых при ортодонтическом лечении.

Предназначено для студентов 4-го курса медицинского факультета  
иностраннх учащихся, обучающихся на английском языке по  
специальности «Стоматология».

**УДК 616.314-0809.23(075.8)-054.6**  
**ББК 56.6я73**

**ISBN 978-985-21-0432-6**

УО «Белорусский государственный  
медицинский университет», 2019

## PRACTICAL SESSION 1

**TOPIC:** Methods of diagnostics in orthodontics. Clinical methods of diagnostics. Clinical functional tests.

**Total time of session:** 7 academic hours.

**Topic description.** Diagnostic is a difficult process based on connection between objective and subjective thought. To manage this process, you should use logic, structure, opportunities. There are a lot of classifications of malocclusion in orthodontics. Systematization of knowledge will help to use advantages from different classification.

**Aims and objectives of the lesson. Students should know:**

- 1) Basic steps of development of malocclusion classification
- 2) Basic principles of classification of malocclusion and basics of contemporary orthodontic terminology
- 3) Put diagnosis using systematic approach and method of 3d analysis.

**Requirements for the initial level of knowledge. Student should repeat from:**

- from morphology – developmental stages of dentofacial region, morphology of the bones;
- physiology – anatomical and physiological correlations between organs and maxillofacial region;
- orthodontics- anthropometrical research.

**Practical questions of related disciplines:**

1. Name periods of human bite formation.
2. Which bones are formed facial skeleton and neurocranium?
3. Which neuro-muscular reflexes are produced chewing, breathing, speech, swallowing?
4. Name planes of the head.

**Practical questions:**

1. What are the diagnostic methods used in orthodontics in the formulation differential diagnosis? Describe them in terms of informativeness.
2. Give a general description of the clinical diagnostic method. How to interpret the results of static studies during its implementation?
3. Give examples of techniques for clinical functional tests.

**Educational grants.** For diagnostics of dentofacial anomalies in orthodontics the following methods are used: clinical, radiological (X-ray, magnetic resonance imaging), functional, anthropometrical.

The main method of examination of patients with dentofacial abnormalities is clinical method, including medical history (survey) and examination. During interview, we try to find out personal data, complains, social, medical and dental history. Personal data include the name, age, gender, place of residence of the patient. Then find out the complaints of the patient and his/her parents (in case of

the examination of a minor patient). The patient's subjective opinion and objective medical assessment often differ. In such cases, doctor needs to inform the patient of identified abnormalities revealed in the course of examination, of their possible influence on function, aesthetics and general state of the body. When planning medical manipulations, obtain parents or guardians' agreement for performance thereof. During interview, find out information about persons with whom the child lives, whether the child goes to school, parents' professions, child's interests, which allows establishing the contact with the patient. Find out information about general development of the patient: a child's ability to learn quickly, body mass compliance with the height of the child, a hobby (it indicates activity, ability for cooperation, responsibility). As a result of the interview psychosocial conditions for orthodontic treatment can be determined.

Studying out medical history (history of common diseases), begin with information about mother's pregnancy and birth. Then ask about any child's diseases of all systems of the body, which may affect the choice of the method, course and outcome of orthodontic treatment. Thus, diseases during which the structure and physiology of connective tissue are changed, including the bone tissue, can cause adverse reactions to orthodontic treatment or the appliance used. Diabetes mellitus, kidney disease, colon disease may contribute to predominance of bone resorption process over the process of its organization when moving teeth and cause excessive tooth mobility after orthodontic treatment or relapse due to calcium and phosphorus balance disorder associated with these diseases. In case of above diseases, the medication correction of existent pathology is required (it is prescribed by physician).

If there is allergy to various substances (nickel, acrylates and composites, etc.), the reaction of oral mucosa is possible. In case of high proneness to allergic reactions, it is necessary to perform a skin test, reveal the antibody titer to the possible allergen. If the test result is negative, it is necessary to observe the reaction of the mucosa during 1-2 weeks after the installation of the appliance. If allergy occurs, replace the construction with an alternate one. Vasomotor or allergic rhinitis hinders the nasal breathing and may limit the time or ability of wearing some orthodontic appliances. Besides, find out a history of infectious diseases to prevent possible contamination.

In patients with epilepsy one should be aware of the possibility of aspiration of parts of the appliance during an epileptic seizure, and of likely development of hyperplastic gingivitis when taking certain anticonvulsants.

A history of injuries and surgeries of the maxillofacial area (jaw fracture, tooth dislocation, etc.) may complicate movement of teeth.

While studying out dental history, find out the following: whether orthodontic treatment was performed earlier; whether parafunctions of maxillofacial area exist (bad habits associated with sucking, bruxism, facial muscle movement during swallowing, the habit of sleeping on one side), time of occurrence thereof, frequency and duration; breathing type; masticatory activity.

Ask about dentofacial abnormalities in other family members, whether they had orthodontic treatment (family history).

The next stage of assessment, i.e. examination, can be divided into the external examination, head examination, oral examination, study of functions of the maxillofacial area. While performing external examination, pay attention to the general condition of the child and compliance of his/her mental, physical and mental development with the age. Pay attention to correct posture of the patient, as its pathology is sometimes accompanied by dentofacial abnormalities. When examining the head, evaluate shape and proportions of the skull, if necessary, using anthropometric research methods. Determine symmetry of the face focusing on pupillary line and lip seal line (should be parallel with the horizontal plane). Asymmetry of the face may be caused by facial hemiatrophy or hemihypertrophy, hemangioma, partial adentia, growth disorder of temporomandibular joint resulting from, e.g., injury or osteomyelitis. Determine height of upper, middle and lower parts of the face, which is important for patients with abnormalities in vertical plane (deep and open bite). Pay attention to submental and nasolabial folds, depth of which increases with a decrease in height of lower part of the face.

Evaluate patient's facial profile. In case of concave profile, large external nose treated with extraction is undesirable as it would result in deterioration of aesthetics. Also pay attention to value of the nasolabial angle, which depends on position of alveolar bone and teeth. In case of protrusion of incisor teeth, the nasolabial angle decreases, and in case of retrusion thereof - increases. Examination of lips allows revealing short upper lip, position of incisor teeth on lower lip, etc.

During intraoral examination, evaluate oral soft tissues, periodontal tissues, dental health, bite. Examine vestibule of the mouth (its depth, structure of frenulums of the lips) and the bottom of the mouth, tongue and pharynx (low position and large size of tongue stimulate growth of the lower jaw, and can contribute to mesial bite formation), teeth (presence of retained primary, impacted, missing teeth, mobility, presence of excessive attrition, caries, filled teeth, determine oral hygiene). Poor oral hygiene and gingivitis are contraindications to treatment with fixed appliances. Further, describe abnormalities of the bite, dental arches and teeth.

When examining the functions of maxillofacial area, pay attention to lip seal at rest, dryness of vermillion border (the type of breathing can be determined based on this information), evaluate the function of swallowing (may be somatic, mixed or infantile) and speech (violation of pronunciation of sounds - dyslalia may be both a cause and a consequence of dentofacial abnormalities), function of temporomandibular joint (limitation or asymmetry of mouth opening, occurrence of noise, pain during functioning, palpation and compression), parafunctions of muscles of maxillofacial area.

Mouth breathing contributes to protrusion of upper incisor teeth, distal displacement of lower jaw, narrowing of upper jaw, formation of anterior open bite. In this case, the external examination allows revealing the abnormality of lip seal and tongue position, a broad nasal bridge, narrow nose, double chin. The reasons for mouth breathing can be a decreased tone of the orbicularis oris muscle, sagittal overjet interfering with the lip seal, nose and nasopharynx diseases (adenoiditis, rhinitis, etc.), as well as the habit which preserved after eliminating the mouth breathing cause. In order to identify the causes of mouth breathing, the otolaryngologist's consultation may be required.

Among impairments of masticatory function lazy and unilateral mastication may be distinguished. Unilateral chewing can lead to formation of cross and mesial bite. Lazy mastication contributes to retardation in growth of the jaws. The above impairments can be revealed during interview with parents, as well as using other laboratory research methods. Sucking is a congenital inborn reflex which should extinct by the end of the first year of life. Preservation of this reflex at a later age (fixation of it) can occur in children who have nervous tension, emotional anxiety. Often fixation of sucking reflex is observed in children who are bottle-fed. The bad sucking habit may cause protrusion of the incisor teeth and dentoalveolar shortening, distal displacement of lower jaw, narrowing of upper jaw due to pressure of cheeks on dissociated dental arches, formation of cross bite.

The long-term thumb-sucking habit leads to a change in posture: forward flexion of the head and, as a consequence, to reduction of the volume of lung capacity, breathing and circulation disturbance. Protrusion of incisor teeth can contribute to lip sucking. The habit of retraction of cheeks is often formed after loss of lateral teeth and leads to dentoalveolar shortening. If differential diagnosis is necessary, perform clinical functional tests.

Eschler-Bittner test allows suggesting the cause of distal bite: morphological abnormalities (changes in the relative sizes and position) of lower or upper jaw. During test evaluate facial aesthetics full face and half face during slow advancement of the lower jaw by the patient to neutral relation of jaws. It is suggested that the distal bite is caused by pathology of the lower jaw in case of aesthetics improvement, pathology of upper jaw – in case of deterioration of aesthetics. If aesthetics improves and then deteriorates, it is concluded that there is pathology of both jaws.

Ilyina-Markosyan test allows evaluating the position of lower jaw at rest and when moving it in order to establish the cause of functional jaw displacement while functioning. The test consists of following five tests:

1. Determination of position of lower jaw during relative physiological rest. Evaluate the symmetry of patient's face, the height of a lower part, record posterior, anterior and lateral displacement of lower jaw.

2. Occlusion of dental arches in usual position of lower jaw. Evaluate the relationship of dental arches paying attention to matching of the midline of upper and lower jaw, which is sometimes absent in abnormalities in transversal plane.

3. Lowering of lower jaw and its subsequent lifting with occlusion of dental arches. Evaluate the displacement of lower jaw while wide mouth opening. If asymmetry increases while opening the mouth, it may be assumed that the displacement of lower jaw is caused by pathology of temporomandibular joint; if increases in occlusion - bite disturbance of dental arches.

4. Advancement of lower jaw forward. Evaluate any premature contacts, the size of the interocclusal space on the right and on the left, which may evidence of dentoalveolar disorders, abnormalities of teeth position.

5. Displacement of lower jaw to the right and to the left. Evaluate any premature contacts, which can limit movement of lower jaw. In normal condition there is a canine guidance (contact on the canine tooth) on the working side when the lower jaw is displaced.

The test for differential diagnosis of mesial bite type. If patient can put the incisor teeth in the edge to edge occlusion, suspect the dentoalveolar type of pathology (it can be treated functionally by appliances), if can not - gnathic (requires a combined method of treatment). After complete clinical examination, orthodontist makes orthodontic diagnosis according to the scheme proposed by F. Ya. Khoroshilkina. If further information about the patient state is needed, engage additional research methods: functional, radiological, anthropometric.

## **REFERENCES**

1. Lecture material.
2. Contemporary orthodontics / William R. Proffit [et al.] third edition 2010.

## **TASKS FOR INDEPENDENT WORK OF STUDENTS**

**1. What kind of diagnostics is carried out during clinical examination in orthodontics?**

- a) Biometric;
- b) static;
- c) Functional;
- d) anthropometric.

**2. Indicate the type of malocclusion, when Eschler – Bittner probe can be used?**

- a) cross-bite;

- b) mesial bite;
- c) deep bite;
- d) distal occlusion.

## **PRACTICAL SESSION 2**

**TOPIC:** Functional methods of diagnostics in orthodontics. Electromyography. Myotonometry. Chewing efficiency diagnostics. Methods of diagnostics of TMJ.

**Total time of session:** 7 academic hours.

**Topic description.** Systematic approach in diagnostic of malocclusion suggests reliable data during patient examination. Malocclusions have multi-etiology nature and their development and prediction of treatment need to consider in correlation with all organs and systems.

**Aims and objectives of the lesson. Students should know:**

1. Main diagnostic methods used in orthodontics
2. How to explain results of static examination?

**Requirements for the initial level of knowledge. Student should repeat from:**

- from morphology – developmental stages of dentofacial region;
- general dentistry – contemporary methods of intraoral examination;
- prosthetic dentistry- methods used for analyzing of chewing efficiency;
- orthodontics- biometric anthropometric methods.

**Practical questions of related disciplines:**

1. Name periods of human bite formation.
2. Name contemporary methods of examination of functional condition of periodontium.
3. Name methods used to move mandible in distal position.
4. Name main anthropometric points.

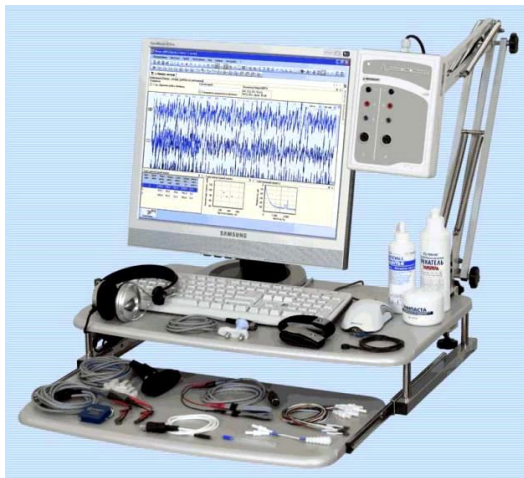**Practical questions:**

1. Describe the functional methods used for diagnostic respiratory and swallowing disorders?
2. How to determine abnormalities in the chewing and speech?

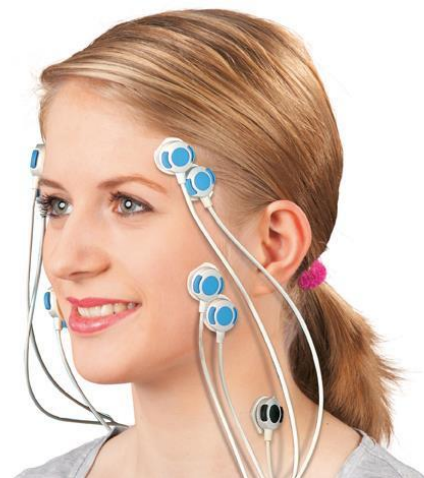**Educational grants.** These methods are used if examination of maxillofacial area functions is required for complete diagnostics of pathology to choose an optimal method of treatment and monitoring of its dynamics.

Examination of muscles of the maxillofacial area. Pathologies of masticatory and facial muscles, such as a decrease in tone, endurance, contractile force, are often the cause of development of dentofacial abnormalities. The above impairments can be revealed with the help of additional diagnostic methods. If patient has muscles dysfunction, it is necessary to correct it in order to avoid

relapse of corrected dentofacial abnormality. Electromyography and myotonometry, methods of studying the muscle condition, are the most commonly used. Electromyography allows recording of bioelectric potentials of superficial muscles (facial, temporal, masticatory, genioglossus) arising from their contraction, using the device (electromyograph). (Fig. 1). To record the electromyogram, surface electrodes are often used which are applied to the degreased skin at a certain point of the examined muscle (Fig. 2). Next step is to record an electromyogram at rest and during functional tests (for examination of masticatory muscles the patient squeezes the jaws as much as possible, orbicularis oris muscle - pull lips into a tube). Then evaluate the results obtained by amplitude, frequency and duration of signals comparing them with the age norm.

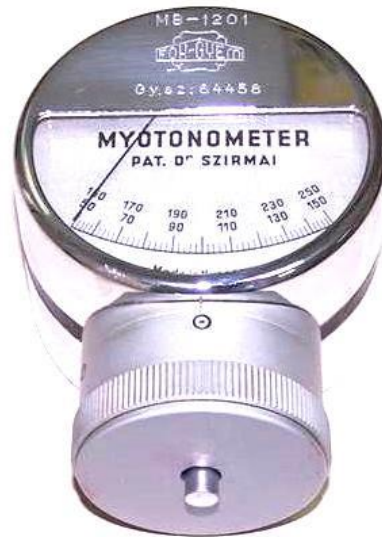

*Fig. 1.* Electromyograph muscles.



*Fig. 2.* Record of bioelectric activity of masticatory muscles.

Myotonometry allows us to determine the tonus of muscles at rest and during contraction by its density. This type of examination is carried out using the myotonometer (Fig. 3). This device shows force that needs to be applied for the probe to immerse into relaxed and contracted muscle. This force is expressed in relative units - myotons.



*Fig. 3. Myotonometer*

Examination of masticatory efficiency is carried out using tests of N.I. Agapov, I.M. Oksman, V.Yu. Kurlandsky, S.E. Gelman, I.S. Rubinov, which are studied during studies on general and orthopedic dentistry. At the Orthodontics Department Professor I.V. Tokarevich and Assistant Yu.Ya. Naumovich have developed the test to examine masticatory efficiency. This functional masticatory test is carried out using silicone impression material of type 0 with viscosity under ISO (C-type material Zetaplus (Zhermack)). For preparation of test tablets, the template has been developed that is a perforated plexiglass plate with thickness of 6 mm and hole diameter of 16 mm. Place the silicone impression material with a plastic consistency into the template holes. After curing of the material, obtain tablets of a cylindrical shape and a predetermined size. To perform the test, the patient is recommended to chew two tablets of the test material one by one with 20 masticatory movements with a one-minute pause in order to prevent fatigue of the masticatory muscles. Then the patient removes the contents of oral cavity on a double paper filter for coffee. Dry the particles of the test material and pour onto the sheet of black cardboard. Then distribute the particles with a stiff brush so that they lie in one layer. Afterwards make a digital photo of the test material particles and store data on the computer, where the results of masticatory test are processed using specially designed programs. These programs help to analyze the test material particles, calculate the area of each particle, calculate the basic characteristics of test particles such as the median, 25 and 75% quartiles, average and maximum values, build the histogram of distribution of test particles, and the masticatory index is determined. Data is displayed on the computer screen in the form of a graphical report.

Methods for examination of functions of temporomandibular joint. Dentofacial abnormalities are often the cause of pathology of temporomandibular

joint (TMJ). Besides, orthodontic treatment itself may be accompanied by a change in habitual occlusion and lead to development of joint pathology.

Artrophonography is a method of recording sounds arising during the joint functioning by a microphone, with subsequent recording of a artrophonogram. Normal operation of TMJ is characterized by noiseless movement of articular head during rotation and during translational movement. Noise in the joint occurs during lower jaw movements: its lowering and lifting. The mechanism of click formation is associated with interaction of the head of the lower jaw and the disc. In case of reduction of the disc the click occurs (when returning back). In case of impairment of configuration of articular surfaces and degradation of the disc, such noise as crepitation, noise of wearing surfaces and etc., is observed. Typically, the artrophonogram is recorded for four cycles of maximum opening and closing of the mouth. Then the program analyses noises, and the doctor interprets the obtained data (fig. 4, 5).



*Fig. 4. Artrophonograph*



*Fig. 5. Artrophonography.*

Axiography is a method of examination of trajectory of the heads of lower jaw in different planes. In orthodontics axiography is used as a part of examination of patients with TMJ functional disorders, in order to confirm its pathology and determine the impact of occlusion disorders on development of joint dysfunction. The method allows evaluating volume, symmetry of movements of articular heads, reveal premature contacts restricting or changing the movement pattern of lower jaw (fig. 6, 7).

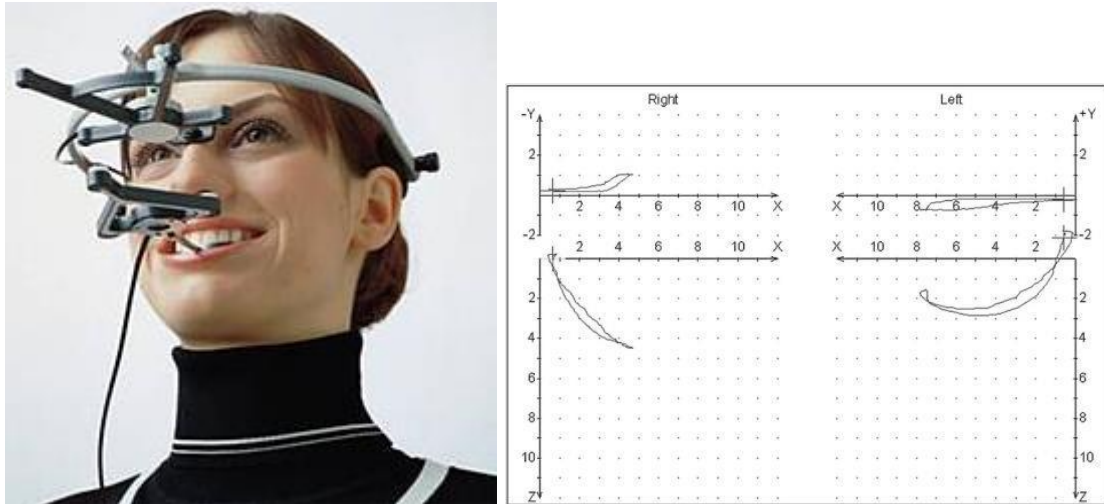


Fig. 6. Axiograph

Fig. 7. Axiogram of opening and closing of patient's mouth with TMJ osteoarthritis (decreased length, change in shape of curves, their mismatching while opening and closing of the mouth).

Rheography allows examining haemodynamics of the joint at rest and during functioning using a rheograph. Effectiveness of treatment can be assessed by haemodynamics.

## REFERENCES

1. Lecture material.
2. Contemporary orthodontics / William R. Proffit [et al.] third edition 2010.

## TASKS FOR INDEPENDENT WORK OF STUDENTS

### 1. What are the aims for myotonometric and electromyographic diagnostics?

- a) diagnosis of changes in the functional activity of the muscles;
- b) diagnosis of respiratory dysfunction;
- c) diagnosis of maxillofacial muscle tone changes;
- d) diagnosis of speech dysfunctions.

## PRACTICAL SESSION 3

**TOPIC:** Radiologic method of diagnostics in orthodontics. Dental radiography. Radiography of the median palatine suture.

**Total time of session:** 7 academic hours.

**Topic description.** X-ray method of diagnosis in orthodontics is the main of the additional (laboratory) method of diagnosis of dentoalveolar pathology, it is impossible to establish good result in orthodontics treatment without it, because it shows the cause-effect and morphofunctional reasons of the pathology.

**Aim and objectives of the lesson. Students should know:** the basic techniques that are used for X-ray diagnosis in orthodontics, determine the indications for their use, be able to evaluate the results of X-ray research from the position of an orthodontist.

**Requirements to the initial level of knowledge. Student should repeat from:**

- from morphology - topography of the bones of the skull and hand;
- radiation diagnostics - X-ray diagnostic symptoms, the permissible level of doses of X-ray irradiation during research in dentistry;
- therapeutic, prosthodontics and surgical dentistry - methods of X-ray diagnosis of diseases and pathological;
- conditions of the teeth and organs of the oral cavity.

**Practical questions from related disciplines:**

1. Name the parts of the skull base. What bones they form? Describe the topography of the inner surface of the skull base.
2. Name contraindications to the X-ray examination in children and adults, depending on the physical status and the level of the absorbed doses of ionizing radiation during a year.
3. Justify the difference in approaches in analyzing of the dental X-ray by an orthodontist and a dentist of another specialization.

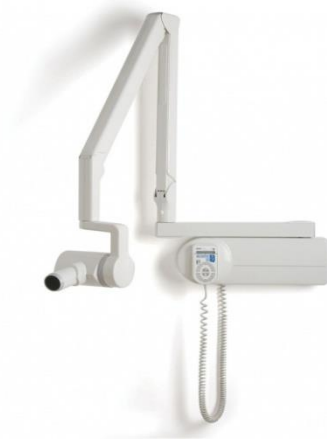**Practical questions:**

1. Which radiological methods are applied in orthodontics? Give their brief characteristics.
2. Define the indications and give the clinical interpretation of dental radiography from the view of an orthodontist.
3. Define the indications and give the clinical interpretation of palatal suture radiography.

**Educational grants.** X-ray method of diagnosis in orthodontics is the main of the additional (laboratory) method of diagnosis of dentoalveolar pathology. Radiologic investigation is necessary for diagnosis clarification, defining the plan and prognosis of treatment, studying changes that take place in the process of child's growth under the influence of medical procedures. It is important, depending on the aim, to choose the most effective method of radiologic investigation correctly. A wide range of X-ray techniques is used for diagnosis of the maxillofacial area. Radiography is a technique involved in producing various radiographic images. Radiograph is a record of an image produced by transmission of X-ray through an object. Radiology is interpretation of radiographic images.

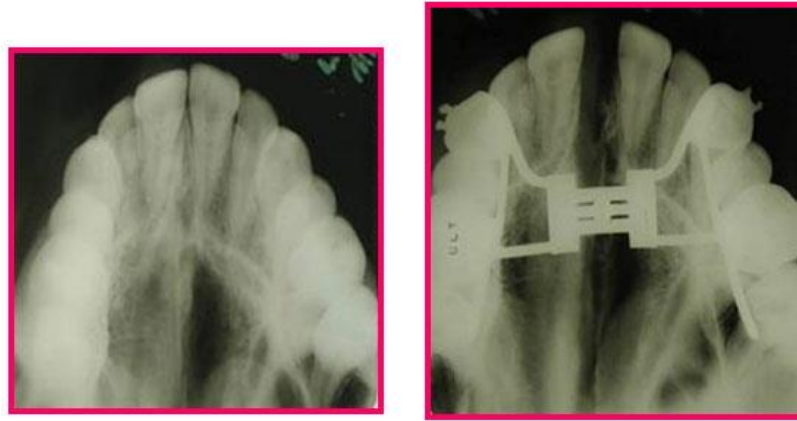
**Intra-oral periapical radiographs.** Intra-oral periapical radiographs are used to view the teeth and their supporting structures, to confirm presence or

absence of teeth, to establish presence or absence of supernumerary teeth, to determine size and shape of unerupted teeth, to assess axial inclination of roots, to study alveolar bone and periodontal tissue, finding out destructive changes: cysts, new formations, congenital and acquired defects, and also the clarification of teeth germs position anomalies, the degree of their crowns and roots formation, teeth retention, their form anomalies, correlation of deciduous teeth roots and permanent teeth crowns. This type of research is carried out on apparatus for intra-oral periapical radiography (fig. 8). Intra-oral periapical radiographs have several advantages: it gives low radiation load (0,15– 0,33 mSv), excellent clarify of the teeth and their supporting structure, it is possible to obtain localized view of area of interest. But the assessment of entire dentition requires too many radiographs. Nowadays digital intraoral radiography (radiovisiography) is widely used, it allows to reduce of radiation load (0.002 - 0.005 mSv), also it has the possibility of increasing the image, the possibility of making measurements, and creating a database.



*Fig. 8.* Apparatus for intra-oral periapical radiography.

**Occlusal radiographs (intraoral radiographs of the median palatine suture).** Occlusal radiographs are carried out with the help of dental X-ray machines by direct, close-focus method. It is used for studying of the median palatine suture structure, the degree of ossification, changes that take place at slow or rapid suture opening (fig. 9) in the process of upper jaw dilation, specifying indications to surgical operation of the frenulum of the upper lip, if its fibers interweave into the median palatine suture and promote diastema formation. The radial load during the radiography of the median palatine suture is 0.26 mSv.



*Fig. 9. Occlusal radiogram.*

## REFERENCES

1. An Introduction to Orthodontics Fourth Edition / Laura Mitchell; 2013
2. Contemporary orthodontics / William R. Proffit [et al.] third edition 2010.
3. Diagnosis of the Orthodontic Patient / F. McDonald;. J. Ireland 280 p.,1998.
4. Facial Aesthetics: Concepts and Clinical Diagnosis/ Farhad B. Naini 454 p 2011.
5. Comparing and contrasting two orthodontic indices, the Index of Orthodontic Treatment need and the Dental Aesthetic Index / [Jenny J](#), [Cons NC](#). Am J Orthod Dentofacial Orthop 1997 Apr;111 (4):454.
6. Lecture material.

## TASKS FOR INDEPENDENT WORK OF STUDENTS:

1. **Which type of X-ray is used for proof frenulun plastic indications :**
  - a) intra-oral periapical radiographs;
  - b) panoramic radiography;
  - c) occlusal radiographs;
  - d) cephalometry.
2. **Intra-oral periapical radiographs are performed:**
  - a) to view the teeth and their supporting structures;
  - b) to establish the level of the malocclusion (cranial, gnathic, dental, mixed);
  - c) to evaluate impacted teeth and multiple unerupted supernumerary teeth;
  - d) to study the median palatine suture structure;
  - e) to estimate the skeletal age of a person.

## PRACTICAL SESSION 4

**TOPIC:** Radiologic method of diagnostics in orthodontics. Panoramic radiography. TMJ (temporomandibular joint) radiography.

**Total time of session:** 7 academic hours.

**Topic description.** X-ray method of diagnosis in orthodontics is the main of the additional (laboratory) method of diagnosis of dentoalveolar pathology, it is impossible to establish good result in orthodontics treatment without it, because it shows the cause-effect and morphofunctional reasons of the pathology.

**Aim and objectives of the lesson. Students should know:** the basic techniques that are used for X-ray diagnosis in orthodontics, determine the indications for their use, be able to assess the results of X-ray research from the position of an orthodontist.

**Requirements to the initial level of knowledge. Student should repeat from:**

- from morphology - topography of the bones of the skull and hand;
- radiation diagnostics - X-ray diagnostic symptoms, the permissible level of doses of X-ray irradiation during research in dentistry;
- therapeutic, prosthodontics and surgical dentistry - methods of X-ray diagnosis of diseases and pathological conditions of the teeth and organs of the oral cavity.

**Practical questions from related disciplines:**

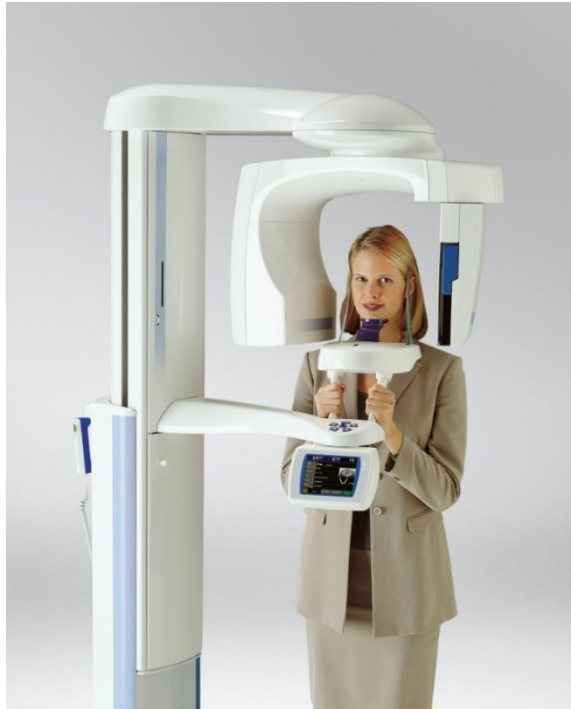1. Which radiological methods are applied in orthodontics? Give their brief characteristics.
2. Define the indications and give the clinical interpretation of dental radiography from the view of an orthodontist.
3. Define the indications and give the clinical interpretation of palatal suture radiography.

**Practical questions:**

1. Define the indications and give the clinical interpretation of TMJ (temporomandibular joint) radiography.
2. Define the indications and give the clinical interpretation of panoramic radiography.

**Panoramic radiography (rotation panoramic radiography, pantomography).** Panoramic radiography is a specialized extra-oral radiographic technique used to examine of the facial structure, including both maxillary and mandibular arches and their supporting structures (temporomandibular joints, paranasal sinuses, zygomatic bones) in a single film. Panoramic radiography is always performed at the stage of diagnosis of dentoalveolar anomalies, as well as planning orthodontic treatment. In this technique, the film and the tube head rotate around the patient, who remains stationery and produce a series of

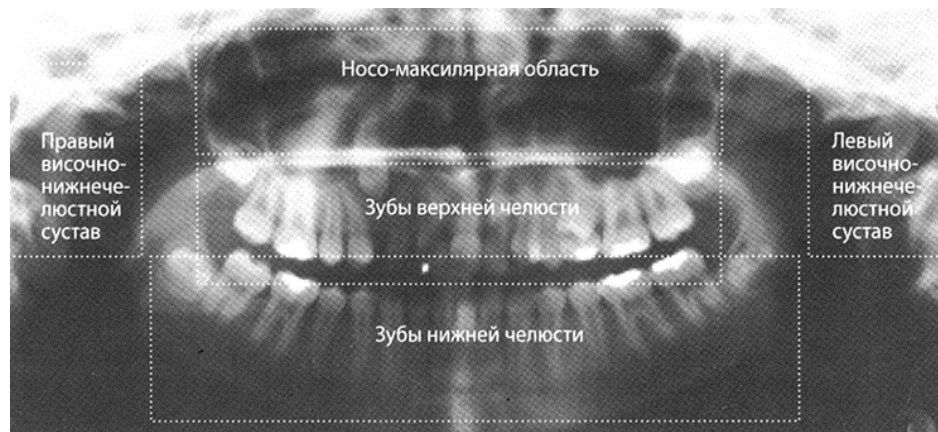
individual images successively in a single film (fig. 10). It is used for visualizing maxilla and mandible in one film, to evaluate impacted teeth and multiple unerupted supernumerary teeth, to detect any pathology involving jaws, to determine the extent of a large lesion (cyst, tumors and development anomalies in the body and rami of mandible), to evaluate traumatic injuries, fractures of mandible, periodontal diseases, to assess the presence and position of wisdom teeth, to evaluate vertical height of the bone before insertion of implants.



*Fig. 10. Panoramic radiograph.*

Advantages of the method: broad anatomic region image, relatively less radiation dose (0,055 - 0,07 mSv), over all views of facial structures. Disadvantages that resulting image does not resolve the fine anatomic detail that can be seen on intra-oral periapical radiogram, soft tissue and air shadow can overlie the required hard structures. It is recommended to evaluate the pantomography in the five topographic areas:

- dentition of the upper jaw;
- dentition of the lower jaw;
- the right temporomandibular joints;
- the left temporomandibular joints;
- the nasal region (fig. 11).



*Fig. 11.* Panoramic radiogram.

Such an approach to the evaluation of the radiograph allows to avoid errors in diagnosis and to compile a comprehensive picture presented in the image of the structures.

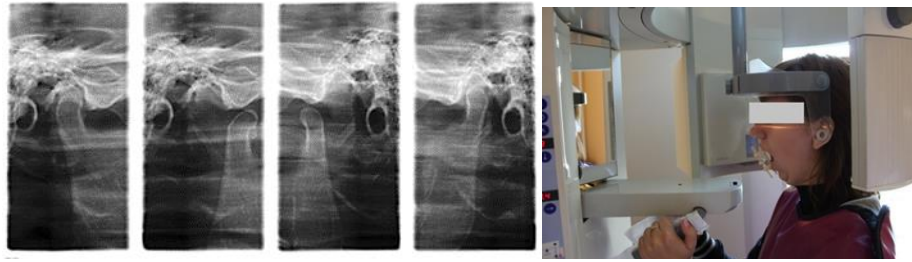
**X-ray examination of the temporomandibular joint (TMJ).** In radiology, a large number of radiography methods of the TMJ are known. However, the projectional distortions arising from their use, superimposed shadows of bone formations reduce the value of this method of investigation.

A large diagnostic capability of the image of the bone structure of the TMJ has a method of tomography of the TMJ.

**Tomography.** Tomography is a general terms used for technique that provides an image of a layer of tissue. The versatility of this technique makes tomography highly desirable for accurate imaging of maxillofacial structures, including the TMG and for crosses sectional imaging of the maxilla and mandible. Modern complex-motion tomography units can be optimized to image any selected region of the facial region. Tomography of TMJ is the most widely used technique for examining the hard tissue of jaw point, because of its ability to image the TMJ quickly and relatively inexpensively (fig. 12). The value of this technique is limited a priori its two-dimensional nature, as well as by inability to show the disc. Tomography can be conventional or computed.

**Conventional tomography.** Conventional tomography is a process by which a layer of an image with in the body is produced while the images of structure above and below that layer are made invisible by blurring. Blurring of the image outside the plane of interest is accomplished by simultaneous movement of X-ray tube and film during the expose. The tube and the film are connected so that movements occur around a point of fulcrum. As the distance from the point of rotation increases, amount of image blurring also increases. As the angle between the source/film and tissue increases thickness of the image is reduced. Principles of tomography can be mechanically implemented in two ways. The X-ray and film can move synchronously in opposite direction in parallel planes. The X-ray and film can move synchronously in opposite direction

in parallel planes but with motions other than straight lines that is circular spiral etc.

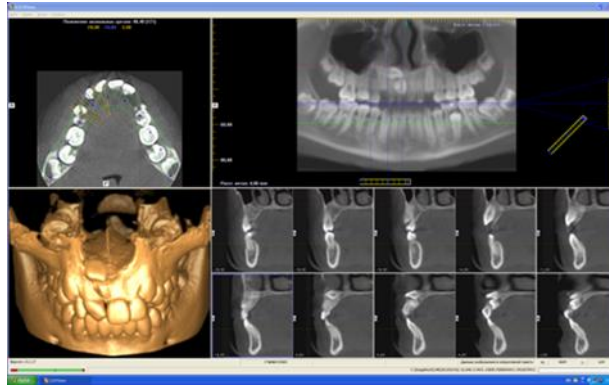


*Fig. 12.* Tomography of TMJ.

**Computed cone-beam tomography.** Computed cone-beam tomography uses a computer to aid in generating the image, and allow multiple computed tomography slices to be stacked to give an idea of 3D form. CT system are mainly complex imaging system which use the beams of X-ray that moves in asynchronous manner with an array of detectors (fig. 13) which calculates and attenuate the X-ray beam ay different angles and in different planes. This data is spread in to computer which perform numerous calculations as per the program and constructs accurate image in the coronal axial plane (fig. 14). Advantages of CT are accurate visualization and possibility of computer programming makes view images in different shape densities. Disadvantage that computed tomography is inefficient at producing suitable soft tissue contrast.

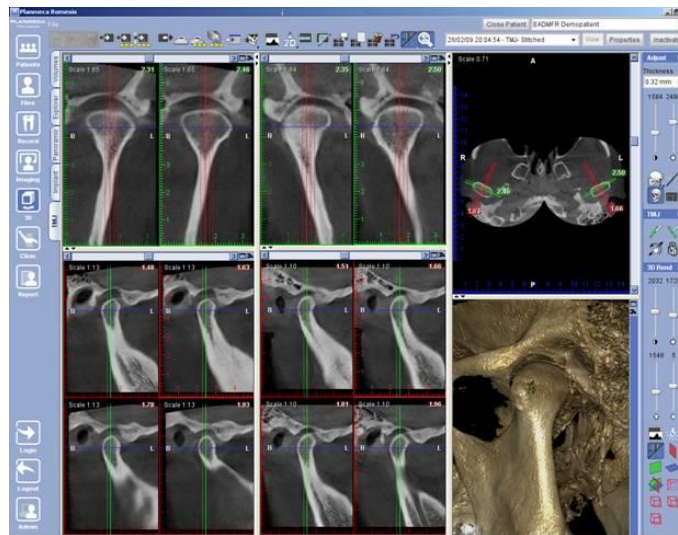


*Fig. 13.* Conduction computed cone-beam tomography.



*Fig.14.* CBCT processed result.

The CBCT method allows to visualize mainly bone anatomical structures of the joints, to assess their functional state with help of the open and closed mouth research (fig. 15).

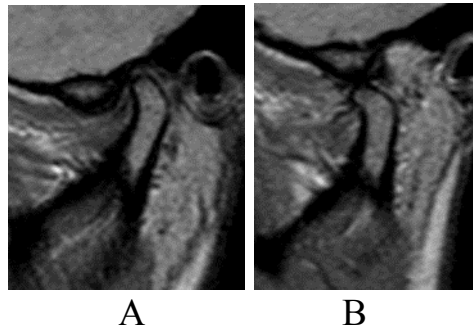


*Fig. 15.* Visualization of the TMJ using the CBCT method.

**Magnetic resonance imaging (MRI).** MRI makes use of two fundamental properties of protons is spin and magnetic movement. Protons behave like small spinning magnets and when placed in a magnetic field they tend to move parallel to the field. Because of the spin the proton differently within their axis progressing about the direction of the magnetic field. It a coil is now wound around a volume of protons; they now progress at 90 degrees around the magnetic field at the same frequency and induce a minute current in the coil which when amplified can be displayed over oscilloscope this energy is utilized in scanning procedure.

Magnetic resonance imaging is preferred when information regarding the articular disc, or presence of adhesion, perforation or joint effusion is desired (fig. 16). MRI produce image without ionizing radiation. Para magnetic contracting

material is required in distinguishing between soft tissue of similar signal intensity.



*Fig. 16.* MRI-cuts of the TMJ in the skew-sagittal plane:  
A- the mouth is closed; B- the mouth is open;

Advantages of the TMJ: does not have hazards as its uses non ionizing electromagnetic radiation, anatomic details are as good as in CT scan, greater tissue characterization is possible, imagining of blood vessel, blood flow, visualization of thrombus is possible. Disadvantages hat takes more time, does not visualize bone, which makes it useless in bony lesions.

## REFERENCES

1. An Introduction to Orthodontics Fourth Edition / Laura Mitchell; 2013
2. Contemporary orthodontics / William R. Proffit [et al.] third edition 2010.
3. Diagnosis of the Orthodontic Patient / F. McDonald; J. Ireland 280 p.,1998.
4. Facial Aesthetics: Concepts and Clinical Diagnosis/ Farhad B. Naini 454 p 2011.
5. Comparing and contrasting two orthodontic indices, the Index of Orthodontic Treatment need and the Dental Aesthetic Index / [Jenny J](#), [Cons NC](#). Am J Orthod Dentofacial Orthop 1997 Apr;111 (4):454.
6. Lecture material.

## TASKS FOR INDEPENDENT WORK OF STUDENTS

1. **Panoramic x-ray is performed:**
  - a) to identify the position of teeth;
  - b) to identify the quantity of teeth;
  - c) to study the structure of the facial cranium;
  - d) to predict the growth of the jaws;
  - e) to decide if surgical treatment of diastema is needed.
2. **X-ray of temporomandibular joint allows you to explore:**
  - a) dynamic and direction of the growth of the mandible articular processes;

- b) the shape and size of the articular processes of mandible, heads and joint pits, the location of the articular heads;
- c) jaw growth;
- d) the influence of masticatory muscle function on the jaw growth;
- e) the shape and size of articular discs.

## **PRACTICAL SESSION 5**

**TOPIC:** Radiologic method of diagnostics in orthodontics. Lateral cephalometry. Hand and wrist radiography.

**Total time of session:** 7 academic hours.

**Topic description.** X-ray method of diagnosis in orthodontics is the main of the additional (laboratory) method of diagnosis of dentoalveolar pathology, it is impossible to establish good result in orthodontics treatment without it, because it shows the cause-effect and morphofunctional reasons of the pathology.

**Purpose and objectives of the lesson. Students should know:** the basic techniques that are used for X-ray diagnosis in orthodontics, determine the indications for their use, be able to assess the results of X-ray research from the position of an orthodontist

**Requirements to the initial level of knowledge. Student should repeat from:**

- from morphology - topography of the bones of the skull and hand;
- radiation diagnostics - X-ray diagnostic symptoms, the permissible level of doses of X-ray irradiation during research in dentistry;
- therapeutic, prosthodontics and surgical dentistry - methods of X-ray diagnosis of diseases and pathological; conditions of the teeth and organs of the oral cavity.

**Practical questions from related disciplines:**

1. Which radiological methods are applied in orthodontics? Give their brief characteristics.
2. Define the indications and give the clinical interpretation of dental radiography from the view of an orthodontist.
3. Define the indications and give the clinical interpretation of palatal suture radiography.

**Practical questions:**

1. Define the indications and give the clinical interpretation of panoramic radiography; hand and wrist radiography.
2. Define the indications and give the clinical interpretation of regression analysis of the lateral cephalogram.

**Educational grants.**

**Hand-wrist radiography.** Radiograph of hand and wrist are useful in estimating the skeletal age of a person. The hand and wrist region have number of small bones whose appearance and progress of ossification occur in a predictable sequence. This enables skeletal age of a person they are useful in assessing growth modification procedures and surgical respective procedures. In some cases, it is important to know exact status of growth for treatment planning: potential vector of facial development, growth potential left, onset of treatment timing, type of effective treatment (for using functional appliance, orthodontic fixed treatment, orthognathic surgery), treatment prognosis.

This method based on assessing of numerous small bones which show a predictable sequence of ossification from birth to maturity (fig. 17). Ossification of the bones of hand and wrist is standard for skeletal development. Skeletal maturation assessment involves the stages of the epiphysis growth: widening, capping, appearance of sesamoid bone of the thumb, fusion.

Stage 1. Width of epiphysis equal that of diaphysis  $E=D$

1. Middle finger proximal phalanx PP3
2. Middle finger middle phalanx MP3
3. Little finger middle phalanx MP5

Stage 2. Adductor sesamoid of thumb S

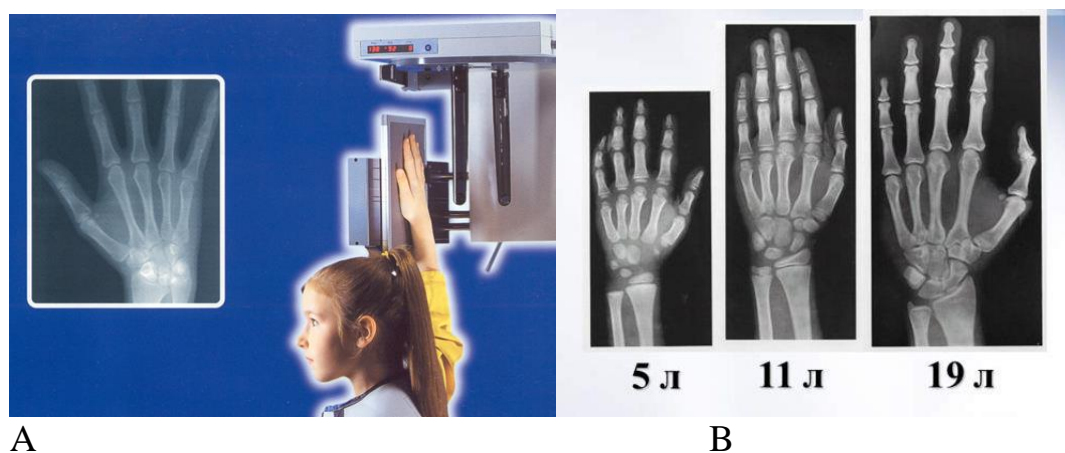
4. Centre of ossification medial to the junction of the epiphysis and diaphysis of the proximal phalanx of the thumb

Stage 3. Fusion

5. Middle finger distal phalanx DP3
6. Middle finger middle phalanx MP3
7. Little finger middle phalanx MP5

Stage 4. Fussion

8. Middle finger distal phalanx DP3
9. Middle finger proximal phalanx PP3
10. Middle finger middle phalanx MP3
11. Radius.



*Fig. 17. Hand-wrist radiography.*

A-Carrying out of hand-wrist radiography. B- Hand-wrist radiography of patients of different ages.

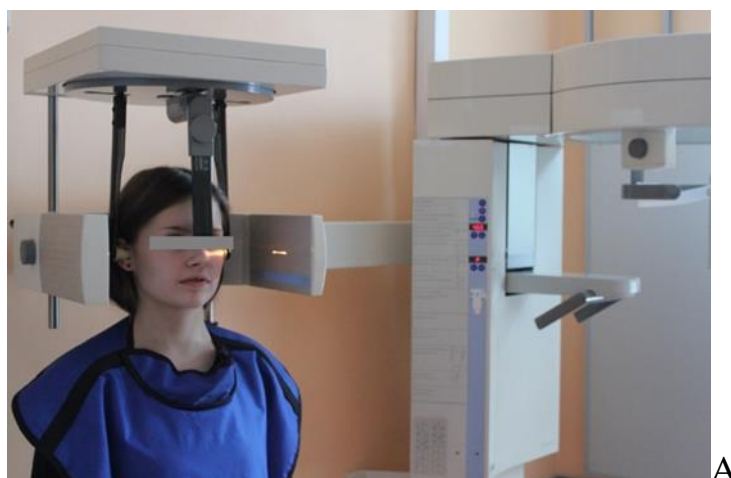The various indicators outlined have been related to the various stage of skeletal development. Ossification of adductor sesamoid of thumb (S) occurs shortly before or at the beginning of the pubertal growth sput. During the the third stage of hand-wrist maturation diaphysis is covered by the cap-shaped epiphys. The MP3cap stage of hand-wrist ossification marks the peak of the pubertal growth. Visible union of epiphysis and diaphysis at the distal phalanx of the middle finger (DP3fusion) signify the end of pubertal growth. Complete union of epiphysis and diaphysis of the radius (R fusion) indicate that the ossification of all the hand bone is completed and skeletal growth is finished.

**Cephalometry of the head.** Cephalometry the analysis and interpretation of radiographs of facial bones are used to assess facial, dental and skeletal relationships. Cephalometry allows establishing the level of the malocclusion (cranial, gnathic, dental, and mixed) in order to select the optimal method of treatment. Cephalometry are used in orthodontics diagnosis and treatment planning (assessment of sagittal /horizontal/vertical skeletal relationship, incisors position/inclination, soft tissue profile), helps in evaluation of treatment results, helps in predicting growth related changes. Several types of cephalometry exist:

1) Lateral cephalogram- lateral view of skull, X-ray beam perpendicular to the patient's sagittal plane (fig.18).

2) Frontal cephalogram- anteroposterior view of skull, X-ray beam perpendicular to the patient's frontal plane (fig.18).

Cephalogram are most often performed with a special equipment: collimated X-ray source (placed 5 feet from midsagittal plane of a patient), cephalostat- head positioned (with 2 ear rods and forehead clamp, film, which placed 1,5-1,8 foot behind midsagittal plane of the patient (fig. 18). This a distance of 1.5 m (international standard, approved at the congress of orthodontists in Boston, 1956), which makes it possible to obtain a view corresponding to the object's size.



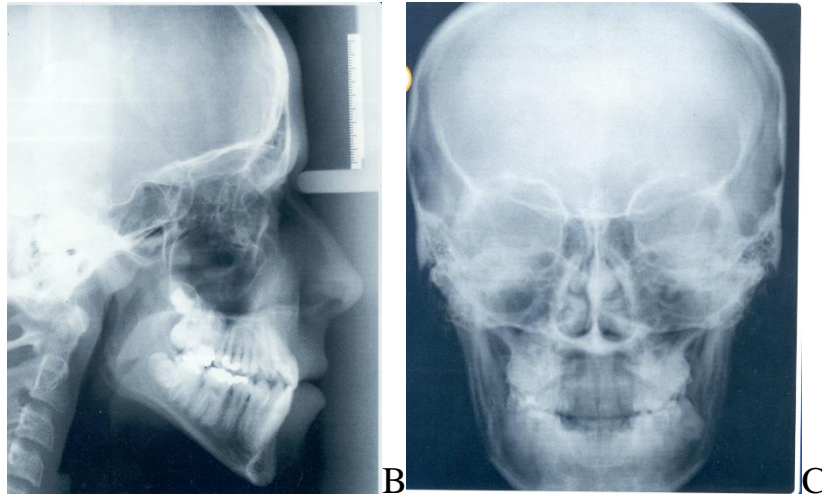


Fig. 18. Cephalography of the head:

A - apparatus for carrying out cephalography, B- lateral cephalogram , C- Frontal cephalogram.

Evaluation of cephalometric radiograph carried out with help of light viewing box (X-ray viewer) by applying anthropometric points on it and further studying the linear and angular parameters. It is convenient to use transparent instruments for measurement. More than 100 anthropometric points and 200 methods of cephalometric analysis have been described in the literature.

**Regression analysis method.** Taking into account the violation of the location of the jaws in the sagittal plane relative to the skull and the variants of the relationship between the length of the apical bases of the jaws, a method for individual differential diagnostics of their morphological varieties was developed (IV Tokarevich, 1986).

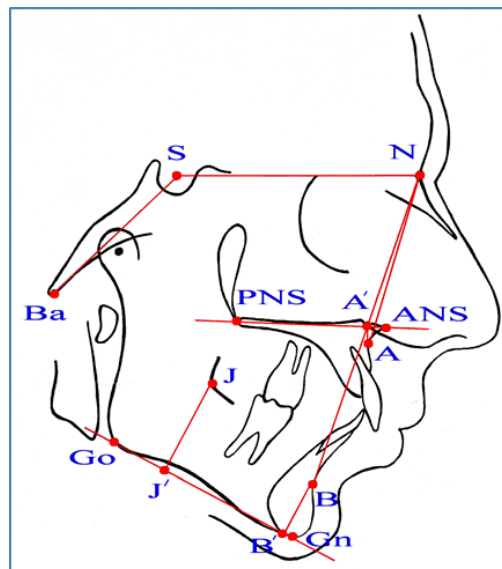


Fig. 19. Anthropometric parameters of regression analysis method.

Anthropometric points:

- S(Sella)- the midpoint of the sella tursica;

- N (Nasion)-the most anterior point midway between the frontal and the nasal bones suture;
- Ba (Basion)- the most anterior point of the foramen magnum;
- A-point of the maximum concavity in the midline of the alveolar process of the maxilla viewed sagittaly;
- ANS (Anterior nasal spine) - it is a tip of the sharp bony process of the maxilla in the midline;
- PNS (Posterior nasal spine)- the most posterior point in the bony hard palate in the sagittal plane;
- B- point of the maximum concavity in the midline of the alveolar process of the mandible viewed sagittaly;
- Gn (Gnathion)- the most antero-inferior point on the symphysis of the chin
- Go (Gonion)-point midway along curvature of angle of mandible between inferior border of body and posterior border of ramus of mandible viewed sagittaly;
- J- The place of transition of the upper contour of the body of the mandible into the anterior contour of its coronal process in the retromolar region.

If the contours of the branches and (or) the body of the mandible do not coincide with the right and left sides, the desired points are found in the middle of the line, connecting points of the same name.

Lines and planes:

- NS –the plane of anterior cranial base;
- SpP- the spinal plane (palatal plane)- a line linking nasal spine of the maxilla and the posterior nasal spine of the palatine bone;
- MP- the mandibular plane -a line connecting gonion and gnation;
- A'-PNS- the length of the apical base of the upper dentition (A 'is the projection of point A onto the spinal plane);
- B'-J'-the length of the apical base of the lower dentition (B 'and J' - projections of the points B and J on the mandibular plane);
- A'-B' - anterior height of the lower part of the face;
- PNS-J' - posterior height of lower part of the face.

Angles:

- NSBa- skull base angle;
- SNA- an angle characterizing the location of the maxilla relative to the base of the skull;
- SNB- an angle characterizing the location of the mandible, relative to the base of the skull (fig. 19);

For diagnosis the cranial level of disorders (position of the jaws), measure the value of the NSBa angle using a protractor on the cephalogram and mark it in the table (Table 1).

*Table 1*

**Evaluation of the location of the jaws in the sagittal plane.**

SNA	NSBa	SNB	SNA	NSBa	SNB
75,6 + 2,5	150	72,2 + 2,5	81,9	132	78,5
76,3	148	72,9	82,6	130	79,2
77,0	146	73,6	83,3	128	79,9
77,7	144	74,3	84,0	126	80,6
78,4	142	75,0	84,7	124	81,3
79,1	140	75,7	85,4	122	82,3
79,8	138	76,4	86,1	120	82,7
80,5	136	77,1	86,8	118	83,4
81,2	134	77,8	87,5	116	84,1
			88,2	114	84,8

The ideal values of the SNA and SNB angles are determined from the table, in the respective columns, at the same level as the NSBa angle, which was measured. Then, according to the cephalogram, the real values of the SNA and SNB angles are measured and compared with the tabulated data. The permissible range of SNA and SNB angles in the table is equal to their calculated values  $\pm 2.5$  (measurement error). If the real values of the angles of SNA and SNB are located within this range, the position of the maxilla (angle SNA) and (or) mandible (angle SNB) is normal. If these values are less than the lower limit of the allowable range, then the corresponding jaw occupies the retro position (retrognathia). If the value of the measured angles is greater than the upper limit, then the corresponding jaw occupies the forward position (prognathia).

It is impossible to apply this method without taking into account the length of the apical bases, because the magnitude of the angles of SNA and SNB depends on the length of the body of the upper and lower jaws.

The length of the apical base of the upper jaws (A'-PNS) is equal to the length of the lower (B'-J') or the difference between these values does not exceed  $\pm 1.5$  mm (Di Paolo, 1983), when orthognathic occlusion take place. To determine the individual optimum of the length of the apical bases of the upper and lower jaws, the following formula is used:

$$\frac{A'-B'+PNS-J'}{2}$$

If the value (A'-PNS) and (or) (B'-J') prevails over the individual optimum, it is macrognathia of the upper and / or lower jaw, if the value less than the individual optimum, it is micrognathia.

Then sagittal malocclusion take place, there are possible combined forms of disorders in both position of the jaws and the different size of their apical bases.

## REFERENCES

1. An Introduction to Orthodontics Fourth Edition / Laura Mitchell; 2013
2. Contemporary orthodontics / William R. Proffit [et al.] third edition 2010.
3. Diagnosis of the Orthodontic Patient / F. McDonald; J. Ireland 280 p.,1998.
4. Facial Aesthetics: Concepts and Clinical Diagnosis/ Farhad B. Naini 454 p 2011.
5. Comparing and contrasting two orthodontic indices, the Index of Orthodontic Treatment need and the Dental Aesthetic Index / [Jenny J](#), [Cons NC](#). Am J Orthod Dentofacial Orthop 1997 Apr;111 (4):454.
6. Lecture material.

## TASKS FOR INDEPENDENT WORK OF STUDENTS

- 1. Cephalometry is used to analyze:**
  - a) dynamics and direction of the growth of the jaws;
  - b) skeletal and dental changes during orthodontic treatment;
  - c) structure of TMJ;
  - d) the size and position of the jaws according to the cranial base;
  - e) the number and position of teeth.
- 2. The procedure of cephalometric analysis:**
  - a) uses the same device as for panoramic x-ray;
  - b) uses a special x-ray device with a tube moved 1.5 m away from the patient's head;
  - c) uses a special x-ray device with the tube move 6m away from the patient's head;
  - d) uses the same device as for conventional dental x-ray.
- 3. The method of diagnosis to estimate the period of growth of facial bones is:**
  - a) an x -ray of mid-palatal suture;
  - b) an X-ray of a hand;
  - c) a TMJ x-ray;
  - d) a panoramic x-ray.
- 4. Define the indications for hand and wrist radiography in orthodontics:**
  - a) for planning of forced expansion of palatal suture;
  - b) for morphologic diagnosis of malocclusion;
  - c) for evaluation of residual growth;
  - d) for determination of palatal suture ossification stag.
- 5. Pick the parameters that characterize the size of the jaw's apical bases on the lateral cephalogram:**
  - a) PNS-J';

- b) A'-B';
- c) B'-J';
- d) A'-PNS.

**6. The method of diagnosis to estimate the period of growth of facial bones is:**

- a) an x-ray of mid-palatal suture;
- b) a panoramic x-ray;
- c) an X-ray of a hand;
- d) a TMJ x-ray;

**7. Cephalometry is used to analyze:**

- a) structure of TMJ;
- b) the size and position of the jaws according to the cranial base;
- c) dynamics and direction of the growth of the jaws;
- d) skeletal and dental changes during orthodontic treatment;
- e) the number and position of teeth;

## **PRACTICAL SESSION 6**

**TOPIC:** Treatment of dentofacial disorders in different periods of dentition formation. Myotherapy.

**Total time of session:** 6 academic hours.

**Practical questions:**

1. Name the treatment methods of dentofacial disorders in various periods of dentofacial system formation.
2. Aim and objectives of the myotherapy.
3. General rules for myotherapy.
4. Static and dynamic exercises. What influences the amount of physical load on the muscles of dentofacial region?
5. Degree of dentofacial muscles functional state decries.
6. Parts of myotherapy exercises complex.

**Topic description.** Treatment of dentofacial disorders must be started early in childhood while bones growth. Mostly myotherapy is the first ortho-treatment child has to get to prevent more severe malocclusion.

**Purpose and objectives of the lesson. Students should know:**

- to master the main exercises of myotherapy;
- to teach students to determine indications and contraindications for myotherapy.

**Requirements to the initial level of knowledge. Student should repeat from:**

It is necessary to repeat the classification of orthodontic devices, know the order of the statement of the orthodontic diagnosis, the methods of treatment of

dentoalveolar anomalies in different periods of occlusion, the peculiarities of the preparation of teeth for orthodontic crowns and rings.

**Practical questions from related disciplines:**

1. Anatomical structure and functions of incisors, canines, premolars and molars.
2. Definition of occlusion. Physiological and pathological varieties of bite.
3. The concept of "central occlusion".
4. Changes occurring in the tissues of periodontal, with the movement of teeth.

**Educational grants.** Methods of treatment of dentoalveolar anomalies can be divided into 5 main types: myotherapy, instrumental treatment (orthodontic method), complex treatment (combination of several methods of treatment), surgical and orthopedic treatment. Every type of dentoalveolar anomalies treatment can be used as a primary or additional method of treatment, depending on the age, the period of occlusion, the degree of pathology severity.

**Myotherapy** is a method of prevention and treatment of dentoalveolar anomalies, consisting of long and systematic exercises of malfunctioning groups of masticatory, facial muscles, muscles of the tongue and the bottom of the oral cavity. Myotherapy is the main method of treatment in the period of temporary occlusion if there are functional disorders and minor deviations in dental occlusion. It could be perceived as an additional method, in combination with instrumental or complex methods if there are functional disorders in the period of mixed occlusion.

Correction of the prevalent number of dentoalveolar anomalies is carried out by the **instrumental method**, therefore it can be considered the main one during periods of mixed and permanent occlusion.

The **complex method** can be the main one with sharply expressed violations of the dentoalveolar system associated with anomalies in size and eruption of teeth during periods of mixed and permanent occlusion.

The **surgical method (orthognathic surgery)** is applied during formation of permanent occlusion (after 16 years), when other methods can not provide a positive result of treatment. Surgical treatment of dentoalveolar anomalies is a complex reconstructive jaw surgery, which helps change size and position of jaws.

The **orthopedic method** of treatment is the main one in all periods of occlusal formation, if the application of this method allows to eliminate aesthetic, functional and morphological disorders of the dentoalveolar system.

The choice of treatment method is strictly individual and depends on a large number of factors. The overall indications for the method could be determined, depending on the period of occlusion formation and severity of its disorders.

During the **period of temporary occlusion**, the main task of an orthodontist is to create optimal conditions for the growth and development of various parts of the dentoalveolar system. This could be achieved by eliminating the causes of occlusion anomalies with preventive measures, in particular myotherapy. According to the indications, the corresponding orthodontic instruments (**instrumental** method) are applied, which, in the first place, stimulate the growth of the underdeveloped areas of the alveolar processes of the jaws.

During the **period of mixed occlusion**, the treatment is mainly carried out by the instrumental method and, rarely, by the integrated method. Occlusion resolution could be achieved by moving teeth, correcting the shape of the dental arches, stimulating the growth of the underdeveloped and restraining the growth of the overdeveloped parts of jaws. In this period, the orthodontic method of treatment is often combined with myotherapy to speed up treatment, consolidate its results.

During the **period of permanent occlusion**, the possibilities of orthodontic treatment are considerably limited in comparison with the previous periods of its formation. In this period, it is already quite impossible to influence the growth of the dentoalveolar system, since it's basically completed. Therefore, with the help of instruments, the movement of teeth, the correction of shape and correlation of the dentition are carried out. In this period, a complex method of treatment is widely used, for example, combination of instrumental treatment with surgical interventions such as tooth extraction, compact osteotomy, plastic of shortened bridles of the upper and lower lips, and suchlike. At sharply expressed forms of open, distal and mesial occlusion formed due to growth and jaw disorders, after completion of permanent occlusion formation, a surgical method of treatment is used.

**Myotherapy in orthodontics.** Exercises for the muscles surrounding the dentition have been used since the beginning of the nineteenth century, but as a method for orthodontic prophylaxis and treatment of dentoalveolar anomalies was proposed by Rogers (R. Rogers) in 1917. In his opinion, chewing and mimic muscles also known as a regulator are capable to eliminate started incorrect occlusion formation. He paid special attention to the position of lips and tongue, which has a major influence on the correct, harmonious formation of the occlusion. The use of this method of treatment is most appropriate at the age between 4 and 7 years, when a child can understand what he is required to do and is able to perform exercises. The effect of treatment depends on the severity of morphological and functional disorders, as well as patient patience, perseverance, and control over the thoroughness of the exercises. Parents, caregivers or medical personnel are responsible for the control over the performance of exercises.

*The purpose of Myotherapy* is to change the functional state of the muscles of the maxillofacial area with the help of physical exercises.

Tasks of myotherapy:

1. Restoration of the physiological tone of muscle tissue.
2. Normalization of the muscles functions involved in the movements of lower jaw.
3. Normalization of the function of the circular muscle of the mouth and tongue muscles.
4. Adaptation of the tissues of the temporomandibular joints and muscles of the maxillofacial region to the orthodontic treatment instruments.

Depending on the mode of muscular contraction, *static and dynamic exercises* are distinguished.

With static exercises, muscles are in a state of increased tone without alternating periods of contraction and relaxation. Dynamic physical exercises are characterized by an isotonic mode of muscle contraction: the period of muscle contraction alternates with the period of its relaxation.

Due to varying degrees of reduction in endurance (both static and dynamic), a differentiated approach to the intensity of exercise is needed.

There are *general rules for conducting Myotherapy*:

1. Exercises should be done systematically and on a regular basis.
2. The intensity of muscle contraction should be sufficient, but not excessive.
3. Muscles should be strained slowly and smoothly.
4. Every exercise should be done several times until a feeling of easy fatigue.
5. The number of exercises and their duration increase over time.

When exercising with children from 4 to 7 years old, a simulator is used, which spring force should be around 0,7 - 0,8 kgs for chewing muscles, and 0,15 kgs - for mimic muscles.

Dynamic exercises are performed at a pace: 20 movements per minute or on the count of 1-2-3-4.

The measure of physical activity on the maxillofacial area muscles depends on the age of a child and functional state of his muscles. Therefore, it is always individual, and even between children of the same age, the intensity of performing muscle exercises can be different.

To assign a load a doctor needs to determine a degree of decrease in the functional state of the maxillofacial region muscles. For children with bite anomalies, there're *three degrees of muscle endurance in the maxillofacial region*:

I degree - static and dynamic endurance of muscles is reduced by 25% in comparison with the age norm.

II degree - static endurance reduced by 25%, for dynamic the reduction is greater than 25% in comparison with the age norm.

III degree - static and dynamic endurance is reduced by more than 25% in comparison with the age norm (Table 2).

The age norm for the performance of static and dynamic exercises is used by orthodontists to determine the degree of reduction in endurance of muscles in the maxillofacial region. The stopwatch determines the duration of the static and dynamic exercises.

Table 2

Dependence of the load intensity on the degree of reduction in muscle endurance

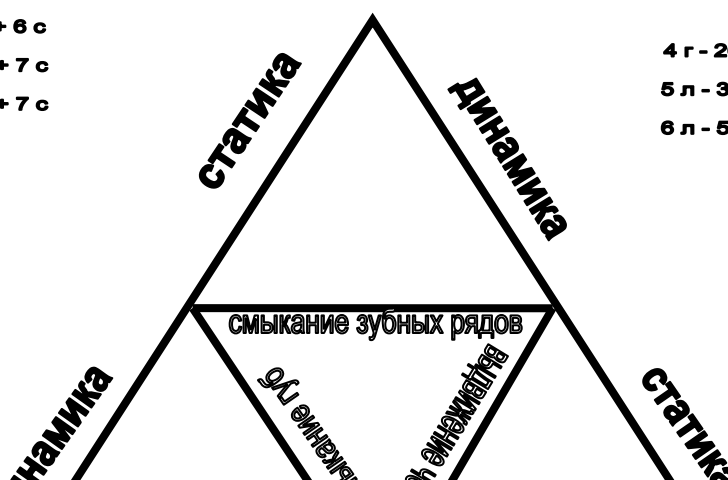
Parameters	I degree	II degree	III degree
Exercise ratio (static to dynamic)	1:1	1:2	1:1 repeat the exercises twice
Intensity of load increase	1/2	1/2 (for static exercises) 1/4 (for dynamic exercises)	1/4

In accordance with the degree of endurance decrease, the intensity of each exercise is selected (Fig. 20):

- I degree of endurance reduction, static and dynamic exercises are performed sequentially at a ratio of 1: 1. Further intensity of exercises increases by half the value of the load.
- II degree, static and dynamic exercises are performed at a ratio of 1: 2. The intensity of static exercises increases by half the value of the load, dynamic increases by.
- III degree of muscle endurance reduction, the ratio of static and dynamic exercises is 1: 1. The intensity of each exercise increases by a quarter of the load. In this case, the complex of exercises is repeated twice.

4 г - 180 + 6 с  
5 л - 210 + 7 с  
6 л - 450 + 7 с

4 г - 265 + 7 с  
5 л - 310 + 7 с  
6 л - 515 + 7 с



**4 г - 155 + 10 с**  
**5 л - 190 + 10 с**  
**6 л - 370 + 14 с**

**4 г - 110 + 10 с**  
**5 л - 155 + 7 с**  
**6 л - 345 + 8 с**

**4 г - 155 + 7 с**  
**5 л - 140 + 7 с**  
**6 л - 335 + 8 с**

**4 г - 185 + 10 с**  
**5 л - 220 + 14 с**  
**6 л - 530 + 27 с**

*Fig. 20.* Duration of static and dynamic loads performed by children with physiological occlusion.

While conducting medical gymnastics you need to comply with basic pedagogical principles: visibility, accessibility, systematic, gradualness. The method of organizing classes is individual. A child performs exercises every day at home under the care of parents and once every two weeks at clinic under the care of a physician.

During classes at the clinic, the child learns the exercises, which are performed partly and completely.

The method of visualization in the practice of therapeutic gymnastics should be present throughout the course of treatment and include the display and explanation of exercises, verbal instruction. The intensity of the exercise is adjusted in accordance to the degree of reduction in muscle endurance. This comply with one of the main principles of therapeutic gymnastics - the gradual increase in the load.

The starting position for performing static and dynamic exercises is sitting on a chair in a state of correct posture, a head and a body are kept straight, a chest is deployed.

The complex of therapeutic exercises consists of three parts: introductory, basic and final.

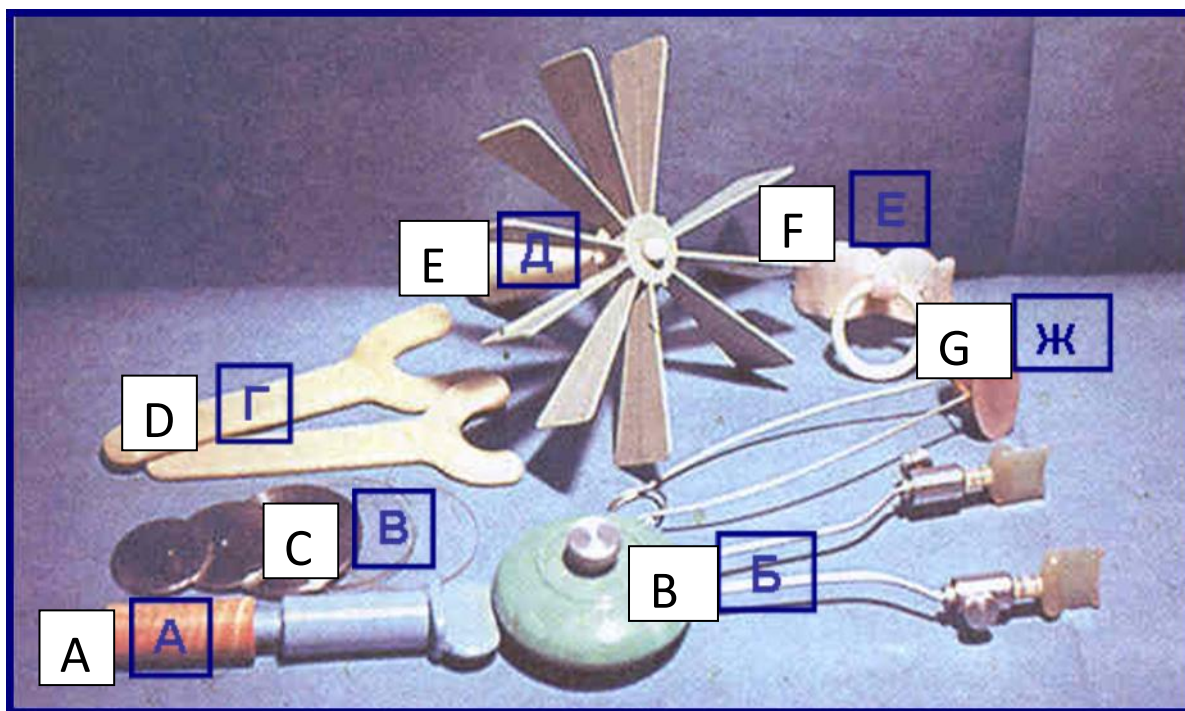
The introductory part includes breathing exercises for 2-3 minutes, which prepare a child for the subsequent performance of therapeutic exercises.

The main part of the complex focuses on training the muscles of the maxillofacial region and is performed in a certain sequence: static exercises precede the dynamic ones, as static efforts have a stimulating effect on dynamic work.


The final part of medical gymnastics gradually reduces the overall and special loads, and this is achieved by combined exercises - various movements of hands and a head. In the course of training, attention is paid to observing nasal breathing and proper posture.

Gymnastic exercises are prescribed without any devices or with special devices. The labial devices include the Dassa activator, the equilibrator, and the Friel disk (Fig. 21).

The vestibular device is Schoncher vestibular plate (fig. 22), the MUPPY plates (fig. 22).



*Fig.21.* The devices for carrying out myotherapy: A - the equilibrator; B - Dass activator; C - Friel's disks; D - devices for training masticatory muscles; E - mill; F - the vestibular plate of Schoncher;G - shock absorber Rogers



*Fig. 22.* Vestibular plates: A and B-plates MUPPY; C - standard Schoncher's vestibular plate

### **Exercises for the circular muscle of the mouth:**

1. Put a piece of paper folded between your lips and squeeze your lips together. Keep paper when doing homework.
2. You can hold the ruler with your lips, gradually loading it.
3. It is recommended to blow on the turntable, easily moving objects (a piece of cotton wool, soap bubbles, etc.).
4. Exercise with buttons. Two buttons with a diameter of 25-30 mm are connected by a cord and placed at a distance of 15-18 mm from each other. A child grabs one button with his lips and squeezes it. He holds the second button with the right hand pulling the cord.
5. The vestibular plate is inserted into the vestibule of the oral cavity. The plate is slightly pulled forward by the ring, while lips tighten and keep holding it.
6. Friel disc is placed between the lips and held by them first for 1 minute, then for 3 - 5 minutes.
7. A Baby keeps Activator Dassa with lips. The force of contraction of the circular muscle must overcome the force of contraction of the wire elements (static exercise). On the count of 1-2, the child compresses his lips, on the count of 3-4 squeezes and again repeats the exercise (dynamic exercise).
8. Maximum closure of the lips (static exercise)
9. The alternating closure of the lips (dynamic exercise).

### **Exercises for the muscles of the anterior third of the tongue:**

1. A rubber ring with a diameter of 5 - 8 mm is placed on the tip of the tongue. A child lifts his tongue up and presses it to the front of the hard palate in the area of the palatine folds, his teeth clench, his lips do not close. It is recommended to swallow saliva without changing the position of the tip of the tongue and the rubber ring. If the tongue is between the dentition, then the exercise is not performed correctly.
2. The patient presses the same rubber ring with the tip of the tongue toward the front of the palate in the area of the palatine folds. Teeth and lips compress, retaining the ring for 5 minutes. In the following days, the exercise time is increased to 10 minutes.
3. Exercise "rider" - imitation of the sound of horse's hooves. Clinking of the tongue is performed 50-60 times.
4. Exercise "watch" - with a half-open mouth, the tongue is held on the upper, and then on the lower lip from the side of the oral cavity (from left to right and vice versa).
5. Stroking the hard and soft palate with the tongue along the middle line, starting from the front teeth.

After mastering these exercises, they begin to train the muscles of the middle section of the tongue.

### **Exercises for the muscles of the middle third of the tongue:**

1. Two rubber rings are placed on the tongue: one on the tip, the other on the middle. The child lifts his tongue up and presses against the roof of the

mouth, clenches his teeth, his lips do not close completely. Do not change the position of the tongue, swallows the saliva three times. The tension of the masticatory muscles can be controlled by palpation, putting the fingers to the cheeks. If you swallow incorrectly, chewing muscles do not strain.

**Exercise for the muscles of the posterior third of the tongue:**

Rinse the throat with water, which helps to relax the muscles and massage them.

**Exercises for chewing muscles training**

1. Maximum closure of dentitions (static exercise). Squeezing the springs of Rogers shock absorber, the doctor sets the nozzles between the dentition rows of the upper and lower jaws and slowly releases the spring. A child should close his mouth, pinch the dentitions as much as possible and keep them in such a position for a set time specified by a doctor.

2. Alternate closure of the dentitions (dynamic exercise). The nozzles of the simulator are located between the dentition rows. On the count of 1-2 a child raises n / h and closes the dentition, on the count of 3-4 he opens them and put down the lower jaw, then again repeats the exercise.

3. Hold the lower jaw in the maximally extended position (static exercise). A child maximally pushes forward (or pushes back) the lower jaw and keeps it in this position.

4. Alternate protrusion of the lower jaw (dynamic exercise). A child pushes the lower jaw forward (back) on the count of 1-2, on the count of 3-4 he moves the lower jaw into the habitual position, then repeats the exercise again.

## REFERENCES

1. Contemporary orthodontics / William R. Proffit [et al.] third edition 2010.
2. Diagnosis of the Orthodontic Patient / F. McDonald; J. Ireland 280 p.,1998.
- 3.Orthodontics. Current principles and techniques /5<sup>th</sup> edition A. Xubair, T.Grabner, R.Vanarsdal , K.Vig .

## TASKS FOR INDEPENDENT WORK OF STUDENTS

**1. Surgical methods are mainly applied in:**

- a) mixed dentition;
- b) deciduous dentition;
- c) permanent dentition.

**2. Application of myotherapy is most effective at age:**

- a) 1–2 years;
- b) 6 months–1 year;
- c) 4–7years;
- d) 10–12 years.

**3. How many degrees of masticatory and mimic musculature endurance decrease are there?**

- a) 3;
- b) 4;
- c) 5;
- d) 7.

**4. Dynamic myotherapy exercises are characterized by:**

- a) period of muscle contraction with period of their relaxation;
- b) period of constantly increased muscular tone without its alteration with the relaxation periods.

**5. Application of orthodontic appliances is the main treatment method during:**

- a) deciduous dentition;
- b) mixed dentition;
- c) permanent dentition.

## **PRACTICAL SESSION 7**

**TOPIC:** Orthodontic appliances as treatment method in orthodontics. Classification of orthodontic appliances. Mechanical appliances.

**Total time of session:** 6 academic hours.

**Topic description.** The high prevalence of dentoalveolar anomalies and their diversity contributed to the emergence of numerous orthodontic appliances. Knowledge of the design of orthodontic appliances, the principles of their action, indications for their application is a great practical importance.

**Purpose and objectives of the lesson. Students should know:**

The characteristics, construction of orthodontics appliances; indications for the use of various orthodontic appliances.

**Requirements to the initial level of knowledge. Student should repeat from:**

Course of Orthodontics the following:

1. Types of orthodontic appliances;
2. Construction of orthodontic appliances;
3. Forces in orthodontics;
4. Anchorage in orthodontics
5. Retention and fixation in orthodontics

**Practical questions from related disciplines:**

1. From anatomy- physiological changes in dentoalveolar system during orthodontic treatment
2. From course of physics- forces during teeth movement

**Practical questions:**

1. Classification of orthodontic appliances

2. Name removable mechanical appliances and determine the type of their anchorage.
3. Name fixed mechanical appliances and their benefits and drawbacks.
4. Differences between fixed and removable orthodontic appliances.

**Educational grants.** Currently, the arsenal of appliances available in the orthodontics to produce the desired results, just big enough, but choose right you need to have information about the indications for use appliances, as well as the advantages and disadvantages of individual designs and techniques.

F.Y. Khoroshilkina and Y.M. Malygin (1977) classified the appliances into account the biophysical principles of their actions and design features. Appliances can be divided into 3 main types:

- A) Preventive - designed to prevent the formation of deformations of dentition, and normalize the functions of dental system.
- B) Therapeutic - to eliminate the formed dentition anomalies.
- C) Retainers - to consolidate the results achieved and prevention of relapse.

The widest is the group of medical devices, which can be divided into the following groups:

According to the principle of action: mechanically acting, functional directing, functional, combined.

According to the method and site of action: single jaw position, single jaw position with intermaxillary action, both jaw appliances, extraoral, combined.

According to the anchorage: interactive (reciprocal), stationary.

By location: intraoral (lingual, vestibular), extraoral –chin cap, combined-head gear, facemask.

By fixing method: non-removable(fixed), removable, combined. (Table 3)

Characteristic of any orthodontic appliance or its modification consists of its characteristics on the above scheme.

*Table 3*

**Difference of removable and fixed orthodontic appliances.**

Removable appliances	Fixed appliances
1. Are produced in a dental laboratory.	1. Standard.
2. Adaptation - 2-3 weeks.	2. Adaptation - high, up to 1 week.
3. Oral hygiene is easy.	3. Oral hygiene - considerable effort.
4. Involving patients in - charge.	4. The participation of the patient in treatment - minimum.

5. The force developed devices: a) small power b) the types of forces: the tipping, a slight rotation	5. The force developed by the unit a) large b) the types of forces: the tipping, bodily movement, rotation, torque.
6. The active treatment period - long.	6. The active treatment period is shorter.
7. Retention period. short	7. Retention long period.
8. The timing of the earlier treatment.	8. The most optimal start of treatment - during the formation of permanent dentition (10-11 years).
9. It may affect the aesthetics of the face.	

Mechanically-acting devices are appliances which affecting the teeth, dental arches and occlusion due to "external" actively operating force (screws, springs, arch wire, rubber traction). Mechanically-acting devices can be removable and fixed.

Mechanically appliances are base plates with screws, springs, various modifications of labial bows.

Fixed mechanically acting devices include Angle appliance, the device Quad Helix, Gashimov-Gerling, Tokarevich-Moskalyova, Derichsweiler, multibonding system.

Characteristics of the fixed mechanical acting appliances.

Angle appliance (Fig. 23) - fixed mechanically acting device conveying pressure on the teeth due to the resilient properties of the vestibular arc, ligatures and elastic thrust.

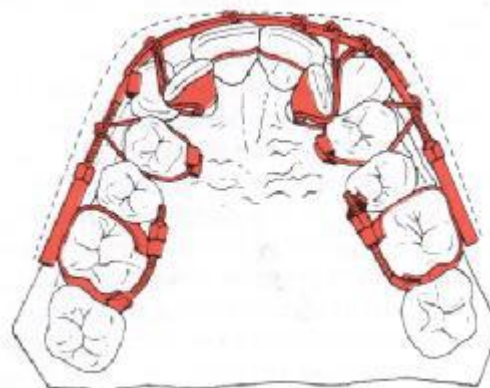
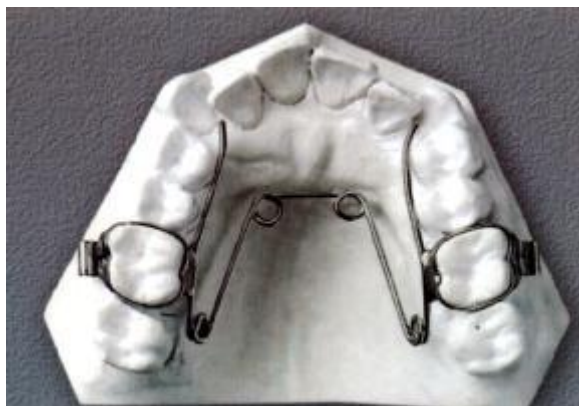

Fig. 23. Angle appliance

With this unit, you can widen or narrow dental arches, correct the ratio of dentition in the sagittal and vertical directions. Appliance consists of bands- on the molars, with soldered horizontal tubes of standard arch.

Angle sliding arch represented by molar bands with tubes and arch hook soldered between the first molars and canines open mesial. Between the hook and tubes pull rubber rings. As a result of reducing is amplified the arch pressure in the incisors, the abutment teeth are displaced mesially. Cutters are tilted in the lingual direction.

Quad Helix (fig. 24) is a fixed appliance which is an elastic version of the W-shaped arch. It is made from stainless steel wire and coils, increasing the amplitude and the elasticity of the device. It consists of the bands fixed on the first or second molars, and soldered a wire to them. To prevent soft tissue irritation palatine arch should be designed not to injure the tissue mucosa of the hard palate and defend 1.5 mm. Activated by an arc extension. The device used to expand the upper dental arch.



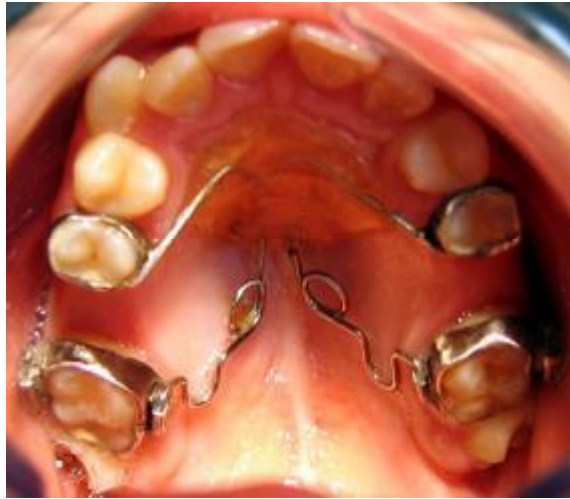*Fig. 24. The device Quad Helix*

Gerling - Gashimov is appliance for distal movement of molars and creating space for second premolars. The device consists of a supporting band for the first premolars soldered to them lingual arch and acting parts - segment of Angle arch with threaded, soldered to the buccal surfaces of the rings on the premolars.

Their free end with a stop nut is introduced into the tube for the rings axially moving molars. Support rings are fixed on visfat-cement on the abutment teeth. Activate the appliance by untwisting of nuts. Under the pressure the molars are moved distally.

Tokarevich-Moskalyova appliance (fig. 25). Appliance for distalization of permanent molars of the upper jaw is a fixed, mechanically-acting, for upper jaw device which is fixed on the premolars and first permanent molars and consists of standard orthodontic bands, acrylic Nancy buttons, two springs that are inserted in the palatal tube on the first permanent molars.

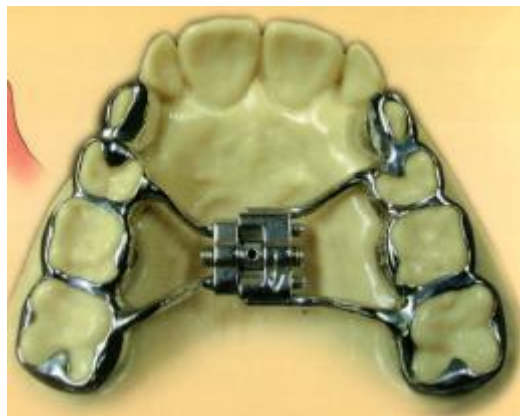Activation of the device is made once a week by activating springs at 60°, allowing you to create a force on the tooth 230 grams on each side.



*Fig. 25. Tokarevich - Moskalyova appliance for distalization of molars*

Derichsweiler appliance (fig. 26). Fixed appliance for rapid opening of the median palatine suture which affects in transversal direction to the teeth in the alveolar bone and palatal suture.

The appliance consists of orthodontic bands, fixed on permanent molars, premolars, canines rigidly connected by wires, with palatal side of the lateral teeth and dispensing them under pressure.

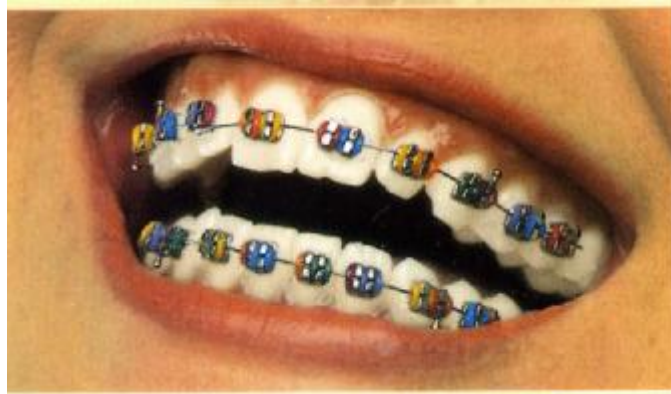


*Fig. 26. Derichsweiler appliance*

The screw is activated every day half a turn. After 4-6 days from the beginning of the activation screw between the central incisors appears diastema.

After completion of the expansion screw close seam maxillary self-hardening plastic.

Multibonding system (fig. 27) consists of a supporting, fixing and active elements. As supporting elements used metal bands, which are reinforced support brackets; retaining elements are brackets which are fixed on the movable teeth; active elements are arch: flex, round stainless steel and nitinol different diameters (from 0.14 to 0.18 mm), rectangular and reversion.



*Fig. 27. Multibonding system*

Braces have a special shape, vertical and horizontal layout, as well as a certain thickness. Each bracket has a purpose and a certain angle of the groove slot. The support bracket is welded to the band; it has a horizontal tube. The support bracket for the upper jaw are provided with three openings, the lower jaw – two for arches with a cross section of different shape.

## REFERENCES

1. Lecture material.
2. Contemporary orthodontics. 5th edition / William R. Proffit [et al.], 2013.

## TASKS FOR INDEPENDENT WORK OF STUDENTS

1. **Non removable mechanical appliances:**
  - a) Angle appliance
  - b) Gashimov-Gerling appliance
  - c) Klammt activator
  - d) plate with Gast screw
  - e) braces
2. **Gerling-Gashimov appliance is used for:**
  - a) mesial movement of frontal teeth
  - b) distal reposition of first upper molars
  - c) vestibular reposition of single teeth
  - d) to gain space for second premolars
3. **The aims of the use of orthodontic appliances are:**
  - a) for retention
  - b) for treatment
  - c) combined
  - d) removable
  - e) for profilaxis

## PRACTICAL SESSION 8

**TOPIC:** The principles of functional treatment of malocclusion. Functional appliances. Properties of action, design and application.

**Total time of session:** 6 academic hours.

**Topic description.** With the development of the functional trend in orthodontics, interest in orthodontic appliances has increased, which has a curative effect on the function of the muscles surrounding the dentition. These are functionally active appliances, the main target of it is treatment of muscle dysfunction. Training them normalizes the function of the dental system, which, in turn, contributes to the success of treatment and the stability of the results achieved. Often dentofacial anomalies combine with each other. Therefore, the combination of mechanical and functional elements in one device is most expedient - these are combined appliances. Knowledge of the design, principles of action, indications for use is necessary for the successful treatment of dentoalveolar anomalies.

**Purpose and objectives of the lesson. Students should know:**

1. Diagnose the malfunctions;
2. Normalize the functions of the dentoalveolar system with the help of functionally active appliances;
3. Apply various designs of functionally-acting and combined appliances.

**Requirements to the initial level of knowledge. Student should repeat from:**

Course of anatomy the following:

Connection between masticatory muscles and facial muscles with skeleton and teeth

Course of physiology the following:

Functions of dentofacial system

Course of Propaedeutic dentistry the following:

Changes in dentofacial system with dysfunctions

**Practical questions from related disciplines:**

1. Name masticatory and facial muscles
2. Name functions of dentofacial system
3. Name types of swallowing and differences between them
4. Mouth breathing. Treatment.
5. Role of chewing and sucking in development of dentofacial system

**Practical questions:**

1. What are the main principles of functional malocclusion treatment?
2. Myofunctional appliances. Features of fabrication. Operating principle. Indication to the application.

**Educational grants.**

Founder of functional orthodontics W. Paux in 1895 wrote that the changes in the structure, shape and size of the bone are the morphological adaptations of organs to dysfunction.

The next important step was the creation of functional appliances. Even Robin in 1902 described a monoblock appliance for treatment of malocclusions reminiscent of the design on modern activators.

At present, the development of functional treatment in orthodontics consider achievements A. Körbitz (1914) and Rogers (1917), who tried to create a functional orthodontics, corresponding to representation of W. Paux (1895). Development of functional orthodontics continued Duyzings (1960) and H. Dass (1961), which recommended to use the speech therapy exercises.

Balters (1954) created a system of functional orthodontic treatment. He proposed orthodontic device for the treatment of dentoalveolar anomalies, named bionator.

Ilina-Markosyan (1970), F.L. Khoroshilkina, Y.M. Malygin (1970) concluded that abnormalities in the dental system cause morphological rearrangement of the alveolar bone.

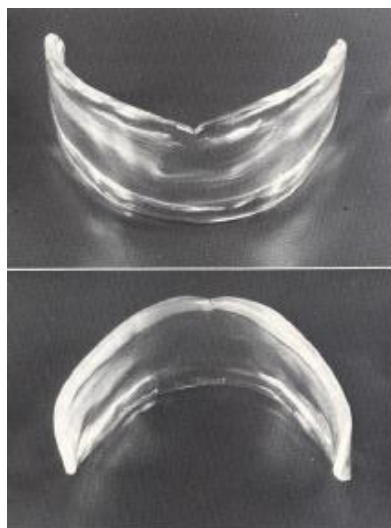
With the development of the functional treatment in orthodontics developed an interest in orthodontic appliances, has a therapeutic effect on the function of the muscles surrounding dentition. Such devices have been combined under the name of the vestibular screens or oral screens.

Screen therapy is based on the use of removable vestibular screens (plates), which are located between the lips and cheeks, on the one side and the alveolar processes - on the other. Introduction of such appliance in the mouth releases the soft tissue surrounding the oral and vestibular surfaces of the teeth.

The vestibular screen (or oral screen) mechanically pushes the soft tissue, which are located in case of malocclusion between the dental arches. It protects the teeth from the pressure in case of bad habit of sucking fingers, lips, and other items. Prevents the passage of air flow through the mouth, closing the lips and normalizes the function of breathing and swallowing, creates favorable conditions for the function of perioral muscles (lips, cheeks, tongue) and can be used for exercise, train orbicularis oris muscle.

For the first time applied Kerbitts vestibular screen (1914), who named it lips formers to reflect the meaning of the name of treatment.

Kerbitts vestibular screen (fig. 28) adjacent to the vestibular surface of the teeth and the alveolar bone to transition folds of the mucosa. Kerbitts expressed the opinion that the development and formation of dentition is very important interaction muscles, lip cheeks and tongue. His vestibular screen is used for normalization of nasal breathing and eliminate the bad habit of sucking fingers or biting the lips. With the accumulation of experience with vestibular plate it began to be used to eliminate the sagittal and vertical malocclusions in the early stages of their development.



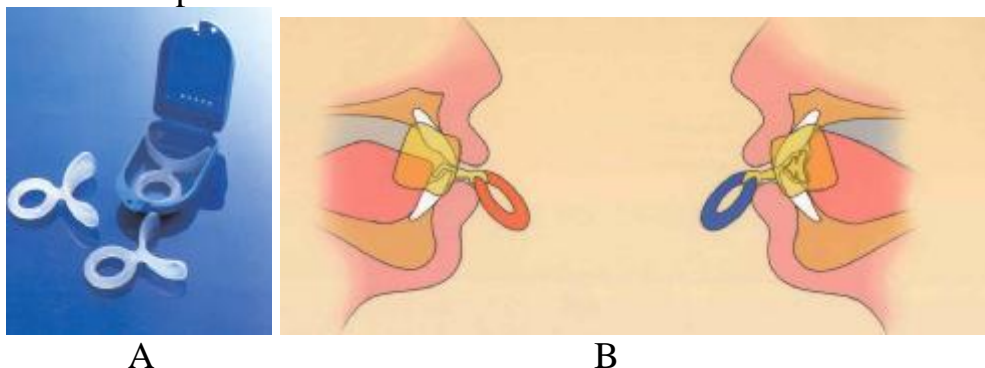
*Fig. 28. Kerbitts vestibular screen*

Kastings and James in 1932 and Gasely in 1947 found it possible to use vestibular screen for active orthodontic treatment, namely for tilting of the upper incisors in palatal direction. For this purpose, the upper and lower borders of the vestibular plate disposed in the highest and lowest transition folds. The distal edges end behind the distal surface of the second permanent or deciduous molars. On the surface of the plate touch the crowns of the upper incisors, must located bite plane for their cutting edges. It provides the stability of the device and prevents it from sliding up to the transitional fold. Plate should touch the vestibular surface and the cutting edges of the crowns of the upper incisors.

Shonher standard vestibular screen (fig. 29) produced by the factory. Issued plate of different size according to the width of the dental arches. Standard vestibular screen contraindicated in the following cases:

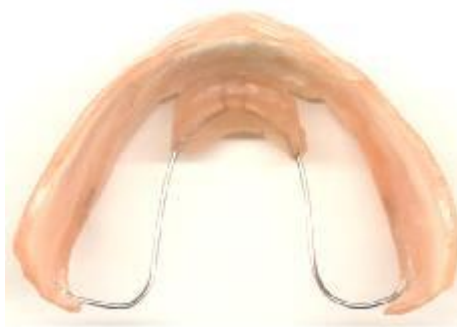- 1) deep overbite;
- 2) true hereditary distal occlusion that developed under the influence of genetic factors;
- 3) open bite resulting from sucking tongue.

With an open bite tongue contact with the screen, and it serves as a barrier to increase overlap.



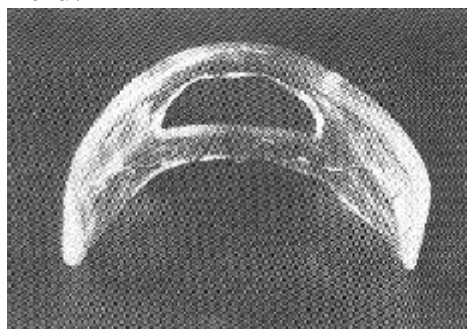
*Fig. 29. Shonher standard vestibular screen: A - appearance of the device;  
B - the location of the appliance in the mouth*

Kraus vestibular plate (fig. 30) consists of vestibular and lingual plates. Both parts of the device are connected by segments of wire diameter of 0.8-1 mm. Their ends are bent in a zigzag manner and fixed in the distal portions of the vestibular shield. Then these segments of wire bend around the distal and the lingual side of the lower last molar, where upon the ends are bent in a zigzag manner and fixed lingual shield. The device is used for the treatment of distal bite, combined with an open, developed as a result of sucking tongue or the wrong swallowing.



*Fig. 30.* Kraus vestibular plate

Vestibular screen with a tongue guard (fig. 31) is intended for the same purpose. Lingual wire frame formed from stainless steel orthodontic wire diameter of 1 mm; her position on plaster models of jaws scheduled by pencil. Then wire segment bent in zigzag, make 4 tabs at the top and 5 - from the bottom. They located on the models in the necks of the upper and lower incisors, the whole guard folded by fingers oval shape of the dental arches. The free ends of the wire is placed between the canines and the first molars, are folded laterally and fixed in the vestibular shield.



*Fig. 31.* Vestibular screen with a tongue guard

Vestibular screen should be used by children mainly during sleeping. Also we must remember that using of oral screens make impossible mouth breathing. To avoid the fear and rejection of use of the oral screen is necessary to make a hole in it for passage of the air stream. They must be at a level gap between the teeth and lips and have a diameter about 7 mm. During using of the oral screen

and of habituation to nasal breathing this hole is reduced, and then close with cold cure acrylic resin.

When the mouth breathing tongue sinks to the bottom of oral cavity, its root is located backward. During the using of the vestibular screen position of the tongue is normalized, it fills the vault of the palate and exerts pressure on the lingual surface of the posterior teeth, which contributes to the expansion of the upper dentition.

Due to the contact between the oral screen and protrusive incisors by the force of contraction of the labial muscles cause their retrusion.

Vestibular screen can correct the deviation of vestibular incisors and stimulate the growth of the lower jaw. At its movements amplified lower lip pressure on the screen, and through it to the upper incisors. Discomfort make a child move the lower jaw which contributes to its growth and to increase the oral cavity. Orthodontic treatment is more effective when it is combined with myotherapy in a daytime.

With the help of vestibular screens malocclusion can be eliminated between the ages from 3 till 8 years old for a period from 4 months till 1 year.

Control of the using of the various vestibular screens must be not less than 1 time in 3 weeks.

In 1915 Andresen and Häupl monoblock has been proposed which is located actually in the mouth (fig. 32).

It represents a simplified form of the upper and lower plates which are connected on the occlusion area by acrylic resin.

Closed activator must be used during night, because it makes difficult to speak.

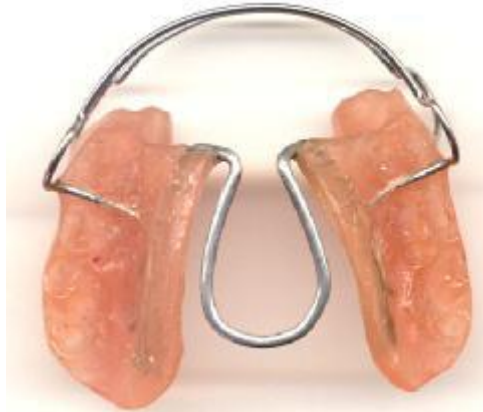

*Fig. 32. Andresen -Häupl closed activator*

Moving mandible forward reduces sagittal gap between the teeth, facilitates closure lip, prevents biting and sucking the lower lip, tongue tip contact with the lips, and improves the function of swallowing and breathing.

The best results of treatment by the activator is achieved with malocclusions in the sagittal and vertical directions, narrowing dentition, the protrusion of the upper anterior teeth.

Klammt improved activator Andresen-Häupl reducing its basis and called open activator (fig. 33).



*Fig. 33. Klammt activator*

Base plate of Klammt activator is located in the upper and lower jaws from canine to the first or second molar teeth, where by there is sufficient space for the tongue in the forward position. Klammt activator used for normalization of occlusion in the sagittal, vertical and horizontal planes. Appliance can be used all day.

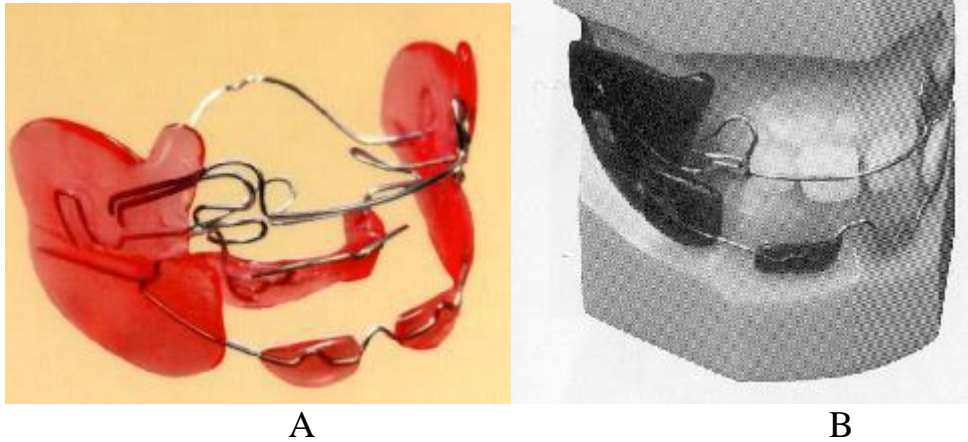
In order to exert the pressure on the anterior segment of dentition was proposed bionator Janson (fig. 34) in which the base plate overlaps 1/3 crowns of lower incisors as in Andrezen- Häupl activator and located on the top as at the Klammt activator.

The device is effective in treatment of combination distal and deep bite.



*Fig. 34. Janson bionator*

Frankel regulator (fig. 35) consists of two acrylic buccal shields and acrylic labial pilots and interconnected by metal frame - clasp palatine, lingual, buccal arch and other items.



*Fig. 35. Frankel regulator: A - appliance; B - the device on the plaster models of jaws*

Essence of treatment by Frankel regulator is to eliminate pressure of the lips and cheeks to the alveolar bone and dentitions in the undevelopment areas, to normalize the closing of the lips, tongue position, their functions and relationships.

L.Frankel proposed 4 regulators types of functions:

I (FR-I) - is used to remove anomalies in the position of the anterior teeth and distal deep bite combining with the narrow dentition and protrusion of upper anterior teeth;

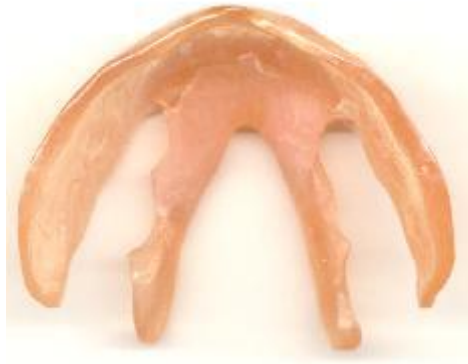II (FR-II) - for the treatment of distal deep bite, coupled with retrusion of the upper anterior teeth;

III (FR-III) - for the treatment of mesial malocclusion;

IV (FR-IV) - for the treatment of open bite.

The treatment by Frankel regulator training muscles which helps to normalize the functions of dental system. As a result, use of the device is achieved closing the lips, nasal breathing, the tongue is in the correct position during functions at rest. Pressure of near- and intraoral muscles is transmitted by Frankel regulator on dentition and alveolar bone of the jaws, and correct an occlusion in the sagittal, transverse and horizontal planes.

Mulleman propulsor (fig. 36) - is representing appliance the vestibular screen to the upper jaw and the base plate at the bottom, connected to each other in the area of the incisors by resin.



*Fig. 36. Mulleman Propulsor*

Device holds the jaw in the extended position and separates the bite in the area of incisors. In an effort to move the lower jaw backwards, i.e. to its original position, the pressure is transmitted through the appliance to the jaw, which promotes its growth, and on the upper front teeth, causing their retrusion. Vestibular part of appliance displaces the cheeks and, therefore, isolates the pressure on the upper jaw. Through contact with the front teeth dentoalveolar elongation occurs in the premolars and molars, which is reduce incisal overlap depth. Propulsor prevents mouth breathing, bad habit of sucking tongue, lower lip, a finger or any object.

The most favorable time for the treatment of distal malocclusion with the help of this device is the initial period of mixed dentition (7-9 years).

In the presence of sagittal gap under 6 mm and a small constriction of dentition treatment lasts about 6 months, more severe abnormalities- under 2 years.

The idea of myofunctional correction using standard devices originated in 1972, when prof. Hinz R. (Germany) proposed to use a series of vestibular screens MUPPY for early correction of dentofacial anomalies in primary dentition (Fig. 37).



*Fig. 37. Vestibular MUPPY screen*

Due to the growing interest for orthodontic care in population, as well as explore the possibility of reducing costs on the orthodontic treatment, R. Hinz in 2006 recommended that clinicians use "preventive ladder":


The first step: using a pacifier «Dentistar» (from birth to two years).

Second stage: use «Stoppi» vestibular screen for breaking the pacifier (2 to 4 years).

Third stage: using standard vestibular screen MUPPY (4 to 8 years).

The fourth stage: prevention through preorthodontic trainers (from 6 years).

Preorthodontic trainer (Fig. 38) - a standard, both jaw, removable functional-acting appliance which is designed to myofunctional training, bite correction and correcting the position of teeth. They are manufactured in factory from silicone, universal size, as designed using computer modeling. C. Farrell was developed in 1994.



*Fig. 38. Preorthodontic trainer*

Trainer program for children from 6 to 12 years are two types of devices include: soft (blue, green or transparent) and hard (pink or red).

Soft model - is the starting appliance which has a higher elasticity, which provides better adaptation to the oral cavity. Soft trainer has two two-millimeter hole in the anterior region, can be used even with difficulty in nasal breathing. The device is used during sleeping and at least 1 hour per day for 6-8 months, then is replaced by hard trainer. During this time, normal breathing and swallowing, eliminating hyperactivity chin muscles, improves position of the tongue. Hard trainer has the same structure as the soft trainer (except holes for respiration) but is made of a resilient material.

In the second stage trainer program produce teeth position correction, forms dentition and occlusion. The duration of treatment it is 6-12 months.

LM-activators (fig. 39) are standard functional, both jaw, removable devices that are designed to provide effective correction of forming bite, normalization of muscle function and elimination of bad habits; creating optimal conditions for the growth and development of the jaws, the normalization of the position of permanent teeth erupting in mixed dentition.

## LMActivator



Silicone activator and aligner

*Fig. 39. LM-activator*

LM-activator is made from a biocompatible silicone.

Structurally, the appliance consists of a high wall with holes for the teeth, the lingual edges, additional three open air tubes to facilitate breathing and making it possible to wear the device in the pathology of ENT - organs.

There are two modifications of trainers - low model for correction of deep bite and high for treatment of open bite. There are 13 sizes of low models and 11 models of high. This allows you to fine-tune the model for each patient. For convenience, asizing special line (LM-OrthoSizer).

"Myobrace" system appliances (fig. 40) - a standard functionally removable both jaw appliance for correcting bite, form of dentitions, and also the position of teeth in patients with abnormalities of dentoalveolar system arising with myofunctional disorders.



*Fig. 40. "Myobrace" appliance*

Myobrace is a two-layer structure combining the functional capabilities of correction by external silicone guides with the active mechanical action of the elastic skeleton forming the inner layer. Elongated distal ends of the device provides good support for the second molars. The effect of alignment of dentition is achieved through the built-in frame, acts as which orthodontic arch, as well as the presence of individual cells of the front group of teeth. In addition,

"Myobrace" system appliances have all the design features typical of myofunctional trainers "tongue" to train the correct position of the tongue, labial bumpers limiter language, special bulges in the molar area, providing decompression TMJ. Myobrace appliance, as well as other devices myofunctional system trainer, has openings for the gradual adjustment of breathing type. Unlike previous models preorthodontic trainers devices "Myobrace" systems are available in six sizes and are designed to correct the period of mixed and permanent dentition. The size of the device is selected individually for each patient by measuring the mesiodistal dimensions of the four upper incisors or disposable paper line.

## REFERENCES

1. Lecture material.
2. Contemporary orthodontics. 5th edition / William R. Proffit [et al.], 2013.

## TASKS FOR INDEPENDENT WORK OF STUDENTS:

### 1. Frankel activator is used for the treatment of:

- a) medial bite
- b) distal deep bite
- c) crossbite without mandible displacement
- d) anomalies of the dentition shape
- e) distal open bite

### 2. Klammt appliance is used to treat:

- a) sagittal anomalies in temporary dentition
- b) vertical anomalies in permanent dentition
- c) transversal anomalies in mixed dentition
- d) sagittal anomalies combined with vertical anomalies in mixed dentition
- e) sagittal anomalies in mixed dentition

### 3. Frankel appliance helps to:

- a) normalize the occlusion in 3 planes
- b) to narrow the dentition
- c) eliminate the pressure of lips and cheeks on the dentition and alveolar processes
- d) align single teeth

- e) normalize the tongue position and lips tonnes closing/seal/incompetence

## PRACTICAL SESSION 9

**TOPIC:** Functional- directing and combined appliances. Properties of action, design and application.

**Total time of session:** 6 academic hours.

**Topic description.** With the development of the functional trend in orthodontics, interest in orthodontic appliances has increased, which has a curative effect on the function of the muscles surrounding the dentition. These are functionally active appliances, the main target of it is treatment of muscle dysfunction. Training them normalizes the function of the dental system, which, in turn, contributes to the success of treatment and the stability of the results achieved. Often dentofacial anomalies combine with each other. Therefore, the combination of mechanical and functional elements in one device is most expedient - these are combined appliances. Knowledge of the design, principles of action, indications for use is necessary for the successful treatment of dentoalveolar anomalies.

**Purpose and objectives of the lesson. Students should know:**

4. Diagnose the malfunctions;
5. Normalize the functions of the dentoalveolar system with the help of functionally active appliances;
6. Apply various designs of functionally-acting and combined appliances.

**Requirements to the initial level of knowledge. Student should repeat from:**

Course of anatomy the following:

Connection between masticatory muscles and facial muscles with skeleton and teeth

Course of physiology the following:

Functions of dentofacial system

Course of Propaedeutics of Dentistry the following:

Changes in dentofacial system with disfunctions

**Practical questions from related disciplines:**

6. Name masticatory and facial muscles
7. Name functions of dentofacial system
8. Name types of swallowing and differences between them
9. Mouth breathing. Treatment.
10. Role of chewing and sucking in development of dentofacial system

**Practical questions**

1. What are the main principles of functional malocclusion treatment?

2. Functional-directing appliances. Features of fabrication. Operating principle. Indication to the application.

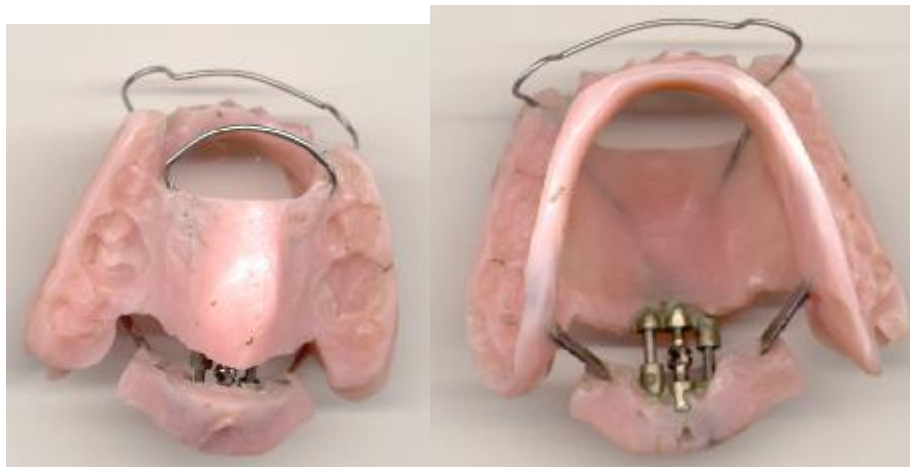
3. Combined orthodontic appliances. Principles of action, indication to the application.

#### **Educational grants.**

In patients who have abnormalities in the development of dental system, is very rarely any one isolated pathology. Most often they are combined with each other. Therefore, in many cases, a combination of mechanical and functional elements in a single appliance is most expedient. Such devices have been named devices of combined action. For example, the activator-Andresen Häupl screw is used, when the displacement of the mandible is combined with oral displacement of the teeth.

Klammt activator may be added by the springs in combination with oral lower incisor inclination.

When a pronounced discrepancy jaw sizes, when the lower prevalent jaw above the upper applies Frankel activator (fig. 41), which is a modified Andresen Häupl activator with a screw.



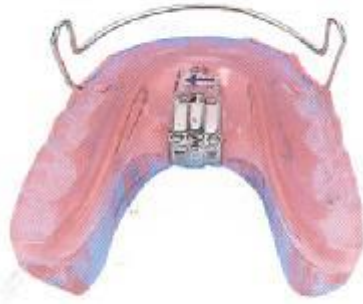*Fig. 41. Frankel activator*

Appliance sawn into 2 sites on the occlusion line. Both parts are connected by distal screw so that untwisting screw cause moving forward of the upper teeth, and the lower part moves backward together with the teeth of the mandible.

During the manufacture of the activator the mandible is displaced in a distal direction.

Appliance can be used not only at night but during the day.

Also for the treatment of mesial bite is used Vunderer activator with Weise screw (fig. 42).



*Fig. 42. Vunderer activator with Weise screw*

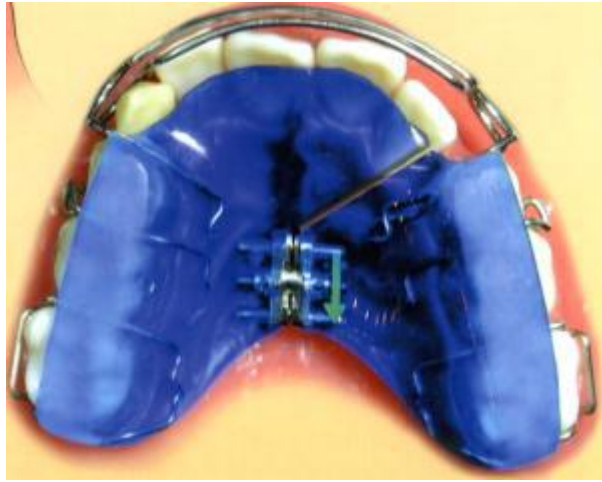
Functionally-directing devices - this appliances, which are based on the transmission power of masticatory muscles through the inclined bite plane, bite pads on individual teeth or groups of teeth, moving them in the right direction. This group includes removable devices: *Bruckl appliance*, the plate with the inclined plane on the upper jaw, the plate on the upper jaw and the lower jaw with bite pads.

Bruckl appliance (fig. 43) is used to treat deep anterior crossbite during mixed dentition.



*Fig. 43. Bruckl appliance*

Plate for upper and lower jaw with posterior bite pads (fig. 44) is intended for the treatment of an anterior open bite. It occurs intrusion of posterior teeth opposite overlays at mastication function, and extrusion of anterior teeth.



*Fig. 44.* The plate on the upper jaw with posterior bite pads and the screw

The plate with an inclined plane on the upper jaw is designed to treat lingual incisor position of the mandible, as well as the distal malocclusion.

The plate on the upper jaw with bite plane is used for the treatment of deep bite without crowding in the anterior group of the lower teeth.

Fixed functional-directing appliances are Schwarts and Bynin guards, Katz crown.

## REFERENCES

1. Lecture material.
2. Contemporary orthodontics. 5th edition / William R. Proffit [et al.], 2013.

## TASKS FOR INDEPENDENT WORK OF STUDENTS

### 1. The so-called functionally-directing orthodontic appliances:

- a) influence the teeth, or a group of teeth with active- force, a rubber elastics tension, screws, springs, arch
- b) combine arches, springs, screws, inclined plane or a bite blocks, bandages, shields
- c) transfer the force of masticatory muscles on the teeth or groups of teeth through the bite block area, occlusal pad or ramp
- d) create optimal conditions for the growth and development of the jaws

### 2. Name so-called functionally-directing appliances:

- a) Katz's crown;
- b) plate with occlusal bite plane;
- c) Angle arch;

**3. Frankel activator is used for the treatment of:**

- a) crossbite without mandible displacement
- b) distal open bite
- c) medial bite
- d) anomalies of the dentition shape
- e) distal deep bite

**PRACTICAL SESSION 10**

**TOPIC:** Complex method of treatment of dentoskeletal anomalies. Indications for applying. Orthodontic indications for permanent teeth extraction.

**Total time of session:** 6 academic hours.

**Topic description.** Not always a patient with an anomaly of the dentoalveolar system can be cured by one method. Severity of orthodontic cases is the indication for complex method using. The use of a complex method allows to minimize the total treatment time through the surgery of the tongue frenulum, speech therapy, myotherapy, the use of compact osteotomy and subsequent instrumental treatment according to indications, in combination with the extraction of individual teeth.

**Purpose and objectives of the lesson. Students should know:**

- 1. the indications for the complex method;
- 2. surgical manipulations as a part of complex method. Indications for using.

**Requirements to the initial level of knowledge. Student should repeat:**

- 1. From course of Normal Anatomy: anatomical features of soft tissues of oral cavity, anatomy of maxilla and mandible.
- 2. From course of Pediatric Dentistry: timing of permanent teeth eruption, timing and stages of periodontal tissue and root formation.

**Practical questions from related disciplines:**

- 1. Timing of eruption, formation and root resorption of primary teeth.
- 2. Timing of eruption and formation of permanent teeth.
- 3. Morphology of frenulum of upper and lower lips, vestibulum of oral cavity.

**Practical questions:**

- 1. The indications for the complex method treatment of dentoalveolar anomalies.
- 2. Compact osteotomy, indications of using, sequence of carrying out.

3. Mucogingival surgery of vestibulum, plastic surgery of frenulums. Indications for using.
4. Surgical exposure of impacted teeth. Treatment strategy.
5. Method of serial tooth extraction by Hotz. Advantages and disadvantages.
6. Orthodontic indications for permanent teeth extraction.

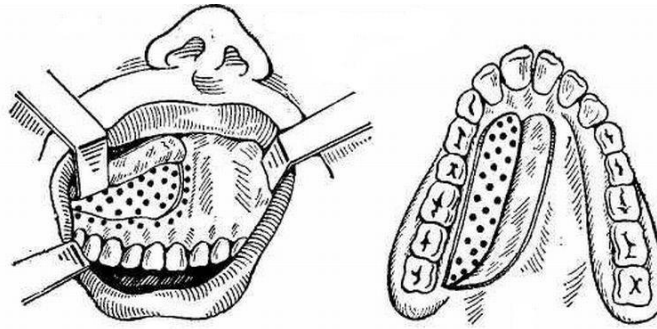
**Educational grants.** Complex treatment of dentoalveolar anomalies are a combination of two or more methods. Myotherapy, prosthetics, surgical intervention, massage may precede apparatus method, combine with it or follow it. Most often the combination of methods used in orthodontic practice is different types of surgical intervention with subsequent instrumental treatment of dentoalveolar anomalies. To surgical interventions as a part of complex method of treatment of abnormalities of the dental system are referred following:

1. compact osteotomy;
2. plastic surgery of upper lip frenulum;
3. plastic surgery of lower lip frenulum and vestibulum of oral cavity;
4. plastic surgery of tongue frenulum;
5. surgical exposure of tooth crown;
6. extraction of single tooth according to indications.

Thus, in cases of severe dentoalveolar anomalies, for reducing the time of treatment and achieving sustainable results compact osteotomy is indicated before using orthodontic appliances.

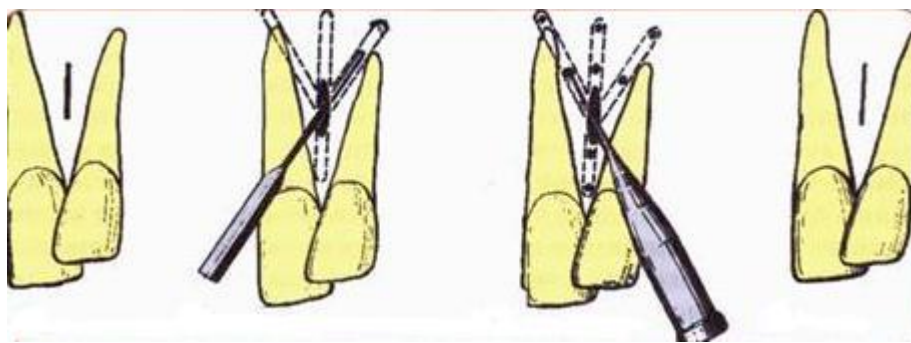
**Compact osteotomy** is well known for a long time (Wassmunol F., 1902; Bruhn Y., 1939). To accelerate orthodontic treatment with severe dentofacial anomalies, and also to obtain more stable results of treatment preliminary surgical intervention - compact osteotomy is indicated. A. A. Limberg pointed out that the main thing in this method is not mechanical weakening of bone tissue, and arising in it in response to trauma biological reaction of inflammation. As a result of the compact osteotomy in bone, aseptic inflammation is observed, which is accompanied by demineralization of bone tissue in the inflammation zone, then reparative processes activate, which facilitates the restructuring of bone tissue under the impact of orthodontic devices.

A.T. Titova (1960-1962) developed method of latticed compact osteotomy (fig. 45).



*Fig. 45. Latticed compact osteotomy by A.T. Titova*

M.S. Shvarzman and F.Ya. Khoroshilkina developed a gentle way of the compact osteotomy by tunneling (fig. 46).



*Fig. 46. Compact osteotomy by Khoroshilkina F.Ya.*

Operation is performed under local anesthesia in a polyclinic and consists of four stages. The first stage - sections of the mucosa and periosteum 4-6 mm in length on the vestibular surface of the alveolar process along or across interdental alveolar septum of displaced teeth at the level of the root's middle, and from the palatine side - retreating 4-5 mm from the gingival margin. Horizontal sections are indicated for the subsequent expansion of dental arch, vertical for dentoalveolar lengthening or shortening. Second stage - tunneling: with the help of narrow smoothing mini spatula a tunnel under the mucous membrane and periosteum up and down is done. The third stage is the introduction of the bur into a tunnel and disruption of the compact layer of bone. The fourth stage is the rapprochement of the edges of mucous membrane and periosteum (without suturing), wound treatment.

For expanding the upper dentition and the body movement of posterior teeth compact osteotomy should be carried out with both from vestibular and the oral sides of the jaw. For teeth movement in vestibular direction or movement in the vertical plane compact osteotomy is done from the vestibular side of the

alveolar process and in the area of the root apex of displaced teeth, for the body movement of the anterior teeth and rotations along the vertical axis - both from the vestibular and the oral sides. For distalization of teeth, compact osteotomy should be done in front of and behind the roots of displaced teeth.

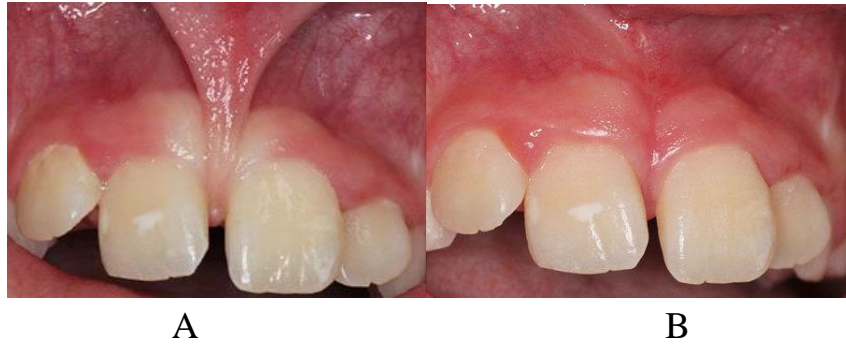Demineralization of bone tissue occurs by 12-14 days after surgery, those in the period of the greatest destruction of bone tissue in the zones of compact osteotomy (the stage of "softening of bone tissue"). Orthodontic treatment should be start on the 12th-30th day after the compact osteotomy.

Combined application of compact osteotomy before instrumental method allows to shorten the treatment period of dentoalveolar anomalies in 1,5 times. Depending on the severity of the dentoalveolar anomalies orthodontic treatment after compact osteotomy lasts from 1 to 4 months.

**Plastic of the shortened frenulum of the upper lip.** Low attachment of the frenulum of upper lip is one of the causes of diastema on the upper jaw (fig. 47). To clarify the indications for plastic of upper lip frenulum X-ray examination of the alveolar process in root area of the central incisors (radiography of the median palatine suture) should be done.

If on the X-rays in the anterior part of the median palatine seam between the roots of the upper central incisors reveal a narrow band, evidence of the absence of bone tissue, this is a sign of interlacing the fibers of the frenulum of the upper lip into the median palatine suture that determines the diastema. In such cases it is necessary to make plastic of upper lip frenulum. In the process of surgical intervention is not enough crosswise cut the frenulum - it is necessary to excise its fibers, weaving in middle palatine seam.

As a rule, the diastema can be completely eliminated before surgery interference. However, if the gap is large, and the frenulum fibers have significant thickness, complete closure of the gap before the surgical interference may not be possible. In this case, the gap is closed at least partially, and the orthodontic movement of the teeth to meet each other should be resumed immediately after frenuloplasty. In this case, healing occurs in the absence of a gap, and the resulting scar tissue stabilizes the teeth in the correct position, and does not create obstacles for the final closure of the diastema.



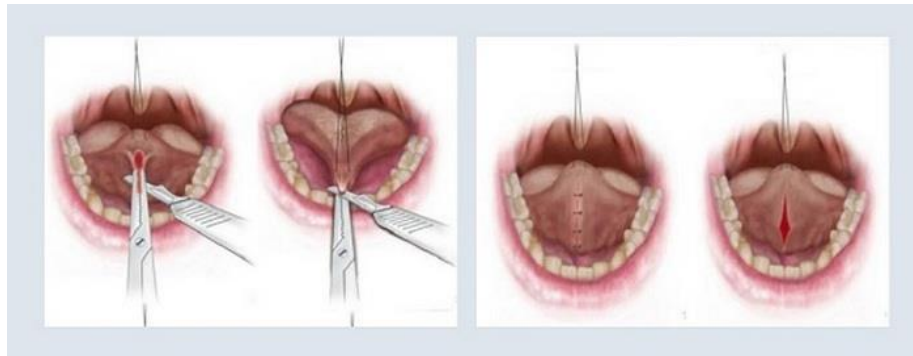
*Fig. 47.* Frenulum of upper lip with its attachment to the top of interincisive papilla  
a-before operation, b-after operation

The plastic of the frenulum of the upper lip can be performed by various methods. Depending on the structure of the frenulum, the following techniques are used: frenotomy (dissection of the frenulum of the upper lip); frenectomy (removal of frenulum of the upper lip); frenuloplasty (movement of the attachment site frenulum of the upper lip). In some cases, to accelerate the orthodontic treatment compact osteotomy in this area is done in addition. It should be noted that in the treatment of diastema it is recommended that plastic of frenulum of the upper lip after the closure of the gap between the central incisors of the upper jaw. Thus, they prevent relapse of pathology, the cause of which is often keloid scars (cicatrix) formed after plastic surgery of the frenulum of the upper lips can be.

**Plastic surgery of the frenulum of the lower lip and the vestibule of the oral cavity.** The main indications for plastic of the lower lip frenulum are chronic localized gingivitis, recession of the gums in the region of the lower incisors and periodontal disease. The reason for the above-mentioned processes is the attachment of the frenulum of the lower lip close to the top of interincisive papilla with the shallow vestibulum of the oral cavity (less than 5 mm). At cases of incorrect attachment of the frenulum when pulling the lower lip, the interdental gingival papilla exfoliates from the necks of the lower central incisors. Correction of the vestibulum of oral cavity and frenulum of the lower lip is often performed in one-stage. The main task to orthodontist is providing the patient with appliance for vestibulum formation.

**Plastics of the frenulum of the tongue.** The shortened frenulum of the tongue slows down the growth of lower jaw and leads to a negative inclination of the anterior lower teeth, can cause periodontal disease, in particular gingivitis and gum recession in the area of the lower incisors. Elimination of the cause in the

form of a shortened frenulum of the tongue greatly contributes to the acceleration of orthodontic treatment and helps to avoid relapse (fig. 48).



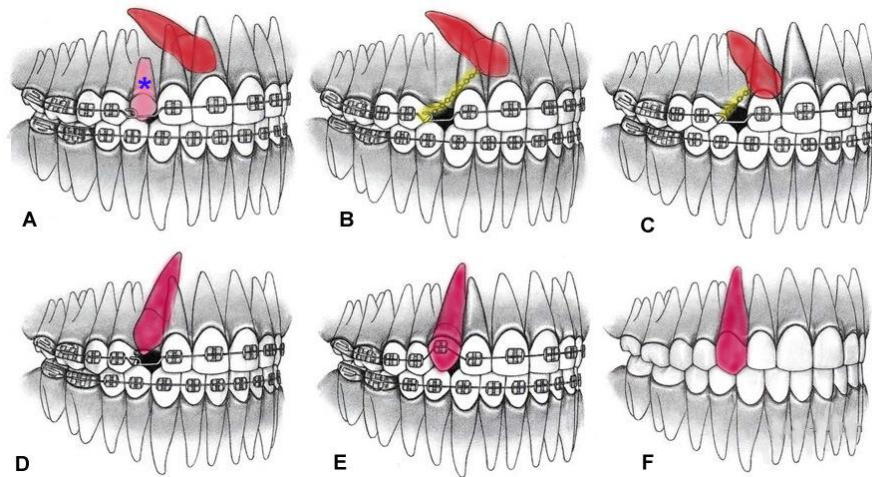
*Fig. 48. Frenuloplasty of tongue frenulum*

Wide frenulum is operated by moving counter triangular flaps (method of Limberg).

After the dissection of the frenulum in young children, the muscles of the tongue restruct; in older age it is more difficult to overcome ingrained habits. After plasty of the frenulum of the tongue, many children cannot lift the tongue tip by themselves, even though the mechanical obstacle is eliminated. Therefore, after performing this operation, children are recommended to carry out myotherapy. Trainings with logopedist contribute to eliminate speech disorders.

#### **Surgical exposure of the crown of tooth delayed in eruption.**

In the thickness of the alveolar process after the expiration of the optimal timing teething remains the teeth that have run out or end formation of roots. Central incisors, canines and second premolars occur unerupted more often than other. Treatment of unerupted permanent teeth is complex and conditionally divided into 2 stages: at the first stage - surgical exposure of tooth crown, excise bone in the direction of tooth traction (fig. 49); on II stage - fixation of bracket or a hook on the tooth for the subsequent extension it with the help of the orthodontic apparatus. Surgical exposure of tooth crown combined with compact osteotomy reduce the total time of orthodontic treatment.



*Fig. 49. Treatment of unerupted upper canine:*

A-gaining of space by extraction of primary canine, B, C - fixing of elastic pull on surgically exposed canine crown, D, E, F – setting the canine in right position

Before the operation, it is necessary to assess the presence of a place in the dentition for moving tooth. If it is not enough, you need to solve the problem and create the necessary space by moving adjacent teeth, expanding the dentition or removing individual teeth. If there is an obstacle on the way of tooth movement, it should be eliminated. So, for example, first remove supernumerary teeth, and after 2-4 months during the repeated operations expose the crown of the tooth, delayed in eruption.

**Hotz method - serial sequential removal of individual teeth or their groups.** R.Hotz named his method "management of teething by extraction".

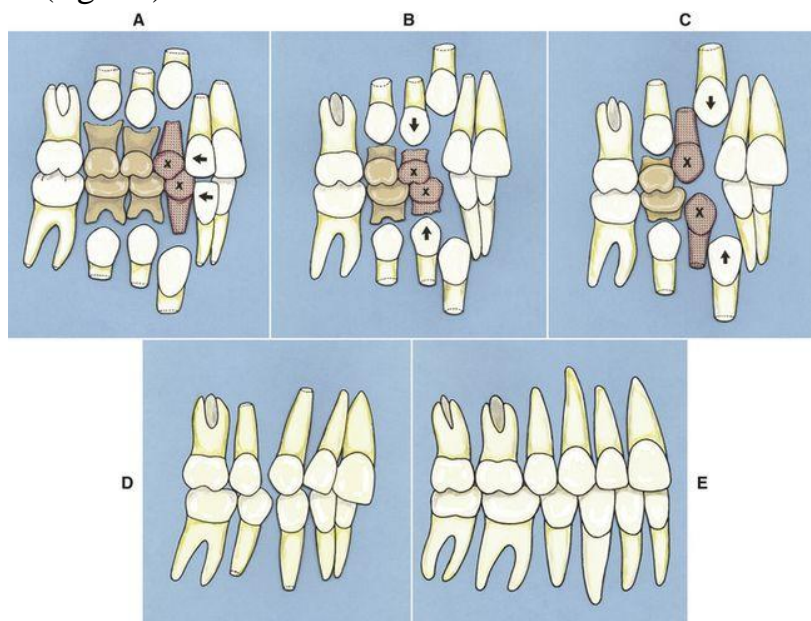
For this method of treatment, the following conditions are needed:

- 1) absence of skeletal forms of dentoalveolar anomalies;
- 2) the neutral ratio of the jaws;
- 3) normal incisive overlap;
- 4) significant lack of space in the dentition (10 mm or more).

This method includes the following activities:

- 1) extraction of primary canines with a lack of space for the lateral incisors (fig. 50);
- 2) extraction of the first primary molars when buds of first permanent premolars are nearby (fig. 50);
- 3) massage of the alveolar process in the area of the first permanent premolar bud to accelerate its eruption;

4) extraction of the first permanent premolars. Permanent canines erupt and set in the dentition (fig. 50).



*Fig. 50. Hotz's method*

If there is significant space deficiency and all stages of sequential removal were carried out in a timely manner, this method can ensure complete closure of gaps and relatively normal placement of teeth without using any orthodontic apparatus. However, such a positive result is rare, and the vast majority of patients require treatment with non-removable equipment to ensure the correct location of the teeth, occlusion and creating a parallelism of the teeth roots.

With a neutral ratio of the dentition, a consistent extraction of teeth on the upper and lower jaws is indicated, with distal occlusion – on upper jaw, with mesial - on the lower jaw.

Treatment using the method of sequential removal teeth starts after eruption of the upper and lower central and lateral incisors, that is in 7,5-9 years.

The disadvantage of Hotz's method is the need for a long (3.5-4 years) supervision of patients.

**Orthodontic indications for the removal of permanent teeth.** The first premolars are more often removed teeth, in some cases - other teeth: central or lateral incisors, canines, second premolars, the first permanent molars. Indications for the removal of teeth with narrowing of the dentition, mesial displacement of the lateral teeth, inconsistency in the size of segments of dentition, as well as dimensions of apical bases of the jaws are determined by clinical examination, measuring of diagnostic dental models and examining the lateral cephalometry of the facial skeleton. Study of diagnostic models of the

jaws reveal a discrepancy in the width of the tooth crowns and their apical basis (the method of N.G. Snagina), disorder of the ratio of segments of dental arches (Gerlach method), mesial displacement of the upper lateral teeth (the Schmudt method). Analysis of survey data allows you to justify a decision about teeth removal and determine the teeth that are to be extracted. Orthodontic indications for the removal of teeth are divided into absolute and relative.

**Absolute orthodontic indications for the removal of teeth:**

1. Absolute macrodontia - the sum of the crown widths of the four upper incisors equal to 35 mm and more, and lower ones - 28 mm and more.
2. Relative (individual) macrodontia with a narrow face - the sum of mesiodistal dimensions of the upper incisors is 32 - 34 mm, the lower incisors - 25 - 27 mm.
3. A significant discrepancy between the sizes of primary molars and premolars on one or both jaws and disocclusion of posterior teeth (Angle's II and III class), requiring grinding of approximal the surfaces of the crowns of temporary canines and molars to provide mesial shift of the first permanent molars.
4. The mesial inclination of the buds of the canines and premolars from 35 degrees and more with respect to the median plane.
5. Open bite combined with crowding anterior teeth and a lack of space for them.

**Relative orthodontic indications for the removal of teeth:**

1. Early loss of primary teeth and subsequent shortening of dental arch due to the mesial displacement of the lateral teeth by 4 mm or more.
2. Open bite combined with vertical type of jaws growth.
3. Deep bite in combination with a horizontal type of jaws growth.
4. Underdevelopment of the lower jaw, excessive development of the upper jaw with distal ratio of dentition - removal of separate teeth on the upper jaw is indicated.
5. Underdevelopment of the upper jaw, excessive development of the lower jaw with mesial bite - sequential removal of separate teeth on the upper jaw is indicated.

Treatment by removing individual teeth has drawbacks that manifest themselves in the event of incorrect planning. These include tipping of the teeth located along the edges of the dentition defect, gaps in the dentition, deepening the incisive overlap. To minimize these disadvantages, it is important to remove teeth timely.

## REFERENCES

1. Lecture material.
2. Contemporary orthodontics. 5th edition / William R. Proffit [et al.], 2013.
3. Ortodontics. Current Principles and Techniques. 6th edition / Lee W. Graber, Robert L. Vanarsdall, Katherine W. L. Vig, Greg J. Huang, 2016.

## TASKS FOR INDEPENDENT WORK OF STUDENTS

### 1. The term "absolute macrodentia" means:

a) the sum of the mesiodistal sizes of the crowns of the four incisors of the upper the jaw is 45 mm;

b) the sum of the mesiodistal sizes of the crowns of the four upper incisors is equal to 35 mm or more;

c) the sum of the mesiodistal sizes of the crowns of the four lower incisors is 27 mm or more;

d) the sum of the mesiodistal sizes of the crowns of the four upper incisors is equal to 30 mm.

### 2. The most often teeth that are removed on orthodontic indications are:

a) premolars;

b) permanent fangs;

c) permanent incisors;

d) permanent molars.

### 3. Indications for the removal of permanent canines:

a) fracture of the roots;

b) retention and mesial inclination of the tooth buds by 35 or more degrees;

c) distal bite (canines of upper jaw);

d) mesial bite (canines of lower jaw).

### 4. The complexity of Hotz's method consists in the combination of:

a) surgical and therapeutic methods of treatment;

b) surgical method of treatment and massage of the alveolar process in the region of the rudiment of the first premolar;

c) apparatus method of treatment and myotherapy;

d) surgical and instrumental methods of treatment.

### 5. Compact osteotomy is carried out with the aim:

a) improving the fixation of the orthodontic apparatus;

b) acceleration of orthodontic treatment;

c) continuation of orthodontic treatment;

d) completion of orthodontic treatment.

## PRACTICAL SESSION 11

**TOPIC:** Orthognathic surgery. Indications for using.

**Total time of session:** 6 academic hours.

**Topic description.** There are many causative factors that affect development of dentoskeletal system. Therefore, disorders can occur in different levels – skeletal or dentoalveolar. Severe cases of skeletal forms of malocclusion not always can be corrected by only orthodontic appliances, and camouflage of significant discrepancy in the jaws sizes by teeth tipping is not a perfect way to solve the problem. The orthognathic surgery is alternative and radical way for skeletal disorders correction.

**Purpose and objectives of the lesson. Students should know:**

1. The indications for the orthognathic surgery;
2. Advantages and disadvantages of orthognathic surgery.

**Requirements to the initial level of knowledge. Student should repeat:** from course of Normal Anatomy: anatomy of maxilla and mandible.

**Practical questions from related disciplines:**

1. Growth of facial skeleton. Time of its completion.
2. Anatomy of maxilla and mandible.

**Practical questions:**

1. The indications for the orthognathic surgery for treatment dentofacial anomalies.
2. Age of patient for treatment with orthognathic surgery.
3. Contemporary surgical techniques on mandible.
4. Contemporary surgical techniques on maxilla.

**Educational grants.** For patients whose orthodontic problems are so severe that neither growth modification nor camouflage offers a solution, surgery to realign the jaws or reposition dentoalveolar segments is the only possible treatment. Surgery is not a substitute for orthodontics in these patients. Instead, it must be properly coordinated with orthodontics and other dental treatment to achieve good overall results. Dramatic progress in recent years has made it possible for combined treatment to correct many severe problems that simply were untreatable only a few years ago. This method of treatment as the main one is used to correct a pronounced mesial, open and cross bite, with a significant underdevelopment of the upper or lower jaw, bone diseases of the temporomandibular joint, postoperative defects of the jaws and others.

Surgery for mandibular prognathism began early in the twentieth century with occasional treatment that consisted of a body osteotomy, removing a molar or premolar tooth and an accompanying block of bone. Edward Angle, commenting on a patient who had treatment of this type over 100 years ago, described how the result could have been improved if orthodontic appliances and occlusal splints had been used. Although there was gradual progress in techniques for setting back a prominent mandible throughout the first half of this century, the introduction of the sagittal split ramus osteotomy in 1957 marked the beginning of the modern era in orthognathic surgery. This technique used an

intraoral approach, which avoided the necessity of a potentially disfiguring skin incision. The sagittal split design also offered a biologically sound method for lengthening or shortening the lower jaw with the same bone cuts, thus allowing treatment of mandibular deficiency or excess. During the 1960s, American surgeons began to use and modify techniques for maxillary surgery that had been developed in Europe, and a decade of rapid progress in maxillary surgery culminated in the development of the LeFort I downfracture technique that allowed repositioning of the maxilla in all three planes of space. By the 1980s, it was possible to reposition either or both jaws, move the chin in all three planes of space, and reposition dentoalveolar segments surgically as desired. In the 1990s, rigid internal fixation greatly improved patient comfort by making immobilization of the jaws unnecessary, and a better understanding of typical patterns of postsurgical changes made surgical outcomes more stable and predictable. With the introduction of facial distraction osteogenesis around the turn of the century and its rapid development since then, larger jaw movements and treatment at an earlier age became possible for patients with the most severe problems (usually related to syndromes).

It should be emphasized that reconstructive surgery on the bones of the facial skeleton is carried out when it slows down (12-14 years) or stops (17-18 years) the growth of the bones of the facial skeleton. Most maxillofacial surgeons still operate such patients after 17-18 years, with the exception of those with bone disease of the TMJ, when the operation on the bones is performed according to functional indications at any age, immediately after diagnosis.

**Treatment indications.** One indication for surgery obviously is a malocclusion too severe for orthodontics alone. It is possible now to be at least semiquantitative about the limits of orthodontic treatment in the context of producing normal occlusion. The limits vary both by the tooth movement that would be needed (teeth can be moved further in some directions than others) and by the patient's age (the limits for tooth movement change little if any with age, but growth modification is possible only while active growth is occurring). Because growth modification in children enables greater changes than are possible by tooth movement alone in adults, some conditions that could have been treated with orthodontics alone in children (e.g., a 10 mm of overjet) become surgical problems in adults. On the other hand, some conditions that initially might look less severe (e.g., 5 mm of reverse overjet) can be seen even at an early age to require surgery if they are ever to be corrected. Keep in mind that the envelope of discrepancy outlines the limits of hard tissue change toward ideal

occlusion, if other limits due to the major goals of treatment do not apply. In fact, soft tissue limitations not reflected in the envelope of discrepancy often are a major factor in the decision for orthodontic or surgical–orthodontic treatment. Measuring millimeter distances to the ideal condylar position for normal function is problematic, and measuring distances from ideal esthetics is impossible.

### **Pre- and Post Orthodontic treatment considerations**

1. *Pre-Orthodontic treatment* considerations. The objectives for pre-surgical orthodontic treatment are to coordinate upper and lower dental arches, align teeth in their own supporting bone, decompensate upper and lower incisors, in addition to maintaining inter-molar and canine widths for a stable occlusion after surgery. Pre-surgical orthodontic treatment should be accomplished according to the surgical plan, and confirmed by the collaborating surgeon, before starting treatment. Leveling should be accomplished together with alignment. At the end of pre-surgical orthodontic treatment, it is helpful to take impressions and examine the occlusal compatibility. A full dimension stainless steel rectangular wire should be placed at least 1 month before the surgery. A patients' appearance may worsen during pre-surgical treatment.

2. *Surgery*. When the preparation for surgery has been completed. cephalometric prediction should be done. From the repositioned dental casts, simulating the actual surgery, wafer splints are fabricated. In –jaw surgery cases, dental casts can be mounted on a semi-adjustable articulator, after a face bow transfer.

3. *Post-Surgical orthodontic treatment*. Post-surgical orthodontic treatment is generally started 3-4 weeks after the surgery, once the surgeon confirms initial bone healing and appropriate jaw movement. Any failed brackets should be rebounded before resuming the post-surgical treatment. Rigid surgical wires and the wafer splint are the removed, and replaced by round wires. light box elastics can be used for occlusal seating.

4. *Debonding and retention*. Usually 3-6 months after surgery, post-orthodontic treatment can be completed once the teeth settle into full occlusion. Since the full dimensional surgical wire was inserted, at the end of the pre-surgical treatment, brackets may be removed after occlusal seating with the round working wire. In open bite patients, ire components in the retainer should not pass through the occlusal area or the extraction site. Considering that the orthognathic surgery patients are generally adults, retainers should be worn longer periods of time.

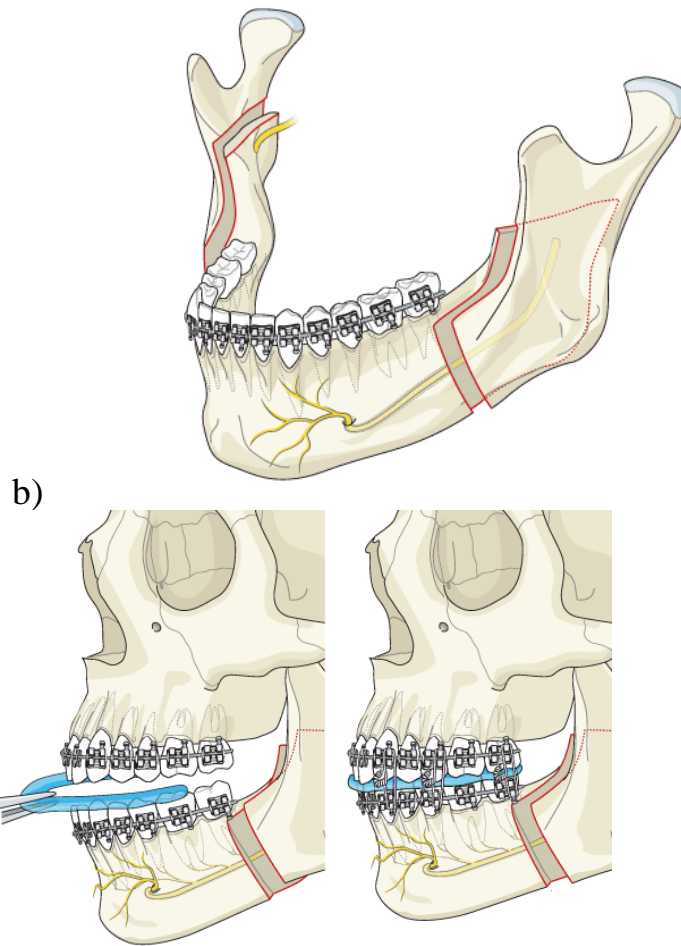
**Contemporary Surgical Techniques.** Both jaws can be repositioned three dimensionally, but not all directions of movement are feasible. The mandible can be moved forward or back, rotated, and moved down anteriorly to increase the mandibular plane and anterior face height—but rotating it up to decrease the

mandibular plane angle and decrease anterior face height is unstable unless the maxilla is moved up posteriorly at the same time, so that this rotation does not lengthen the ramus and stretch the elevator muscles. It can be narrowed anteriorly but widened only with distraction osteogenesis. The maxilla can be moved up and forward with excellent stability, moved down with difficulty because of instability, and moved back only with great difficulty because of all the structures behind it that are in the way. Fortunately, protruding anterior teeth can be moved back via segmental osteotomy, so there is no reason to move the posterior maxilla back. Segmental osteotomy also allows the maxilla to be widened or narrowed, but widening it also tends to be unstable because of the pull of stretched palatal tissues. For surgical correction of the mandible in the sagittal direction, as a rule, a bilateral sagittal split osteotomy of the mandibular ramus (fig. 51). This technique can be used to move the lower jaw both forward and backward. Transoral vertical oblique osteotomy of the ramus is used only for displacement of the mandible posteriorly (fig. 52). For the reposition of the maxilla at the present time, practically in all cases osteotomy by LeFort I is used (fig. 53).

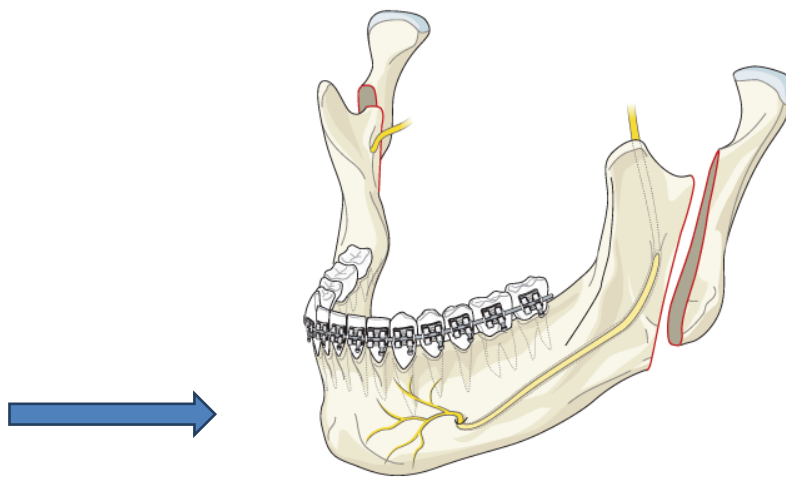
### ***Mandibular Surgery.***

*The sagittal split osteotomy* (fig. 51) now is used for almost all mandibular surgery because of several advantages over mandibular body procedures and alternative techniques for ramus surgery:

1. The mandible can be moved forward or back as desired, and the tooth-bearing segment can be rotated down anteriorly (increasing the mandibular plane angle) when additional anterior face height is desired.
2. It is quite compatible with the use of rigid intraoral fixation (RIF), so immobilization of the jaws during healing is not required.
3. Excellent bone-to-bone contact after the osteotomy means that problems with healing are minimized, and postsurgical stability is good.

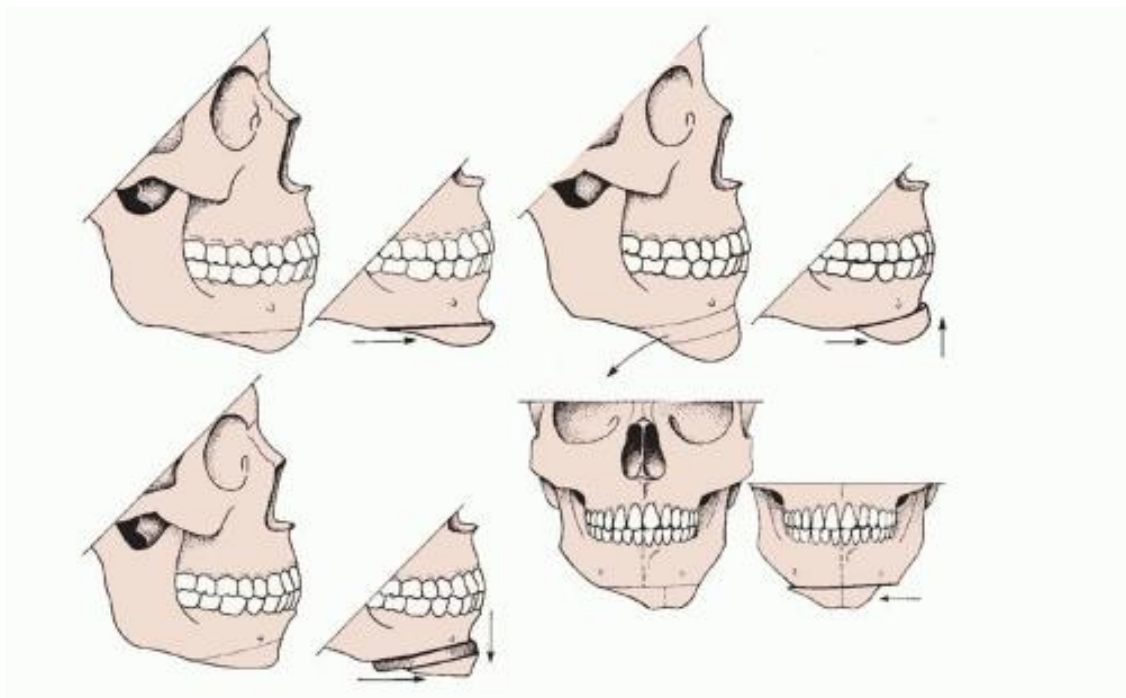


*Fig. 51. The sagittal split osteotomy.*



*Fig. 52. Transoral vertical oblique osteotomy of the ramus.  
Only for displacement of the mandible posteriorly.*

In contemporary treatment, a lower border osteotomy of the mandible (fig. 53) to reposition the chin relative to the mandibular body is a major adjunct to ramus procedures, especially when the mandible is advanced. It is used in about 30% of the patients who receive a ramus osteotomy and in about the same number of patients with maxillary surgery. The lower border procedure allows the chin to be moved transversely, forward or back, and up or down. Other mandibular procedures are used primarily for major advancements or surgery involving the condyles. An extraoral approach often is required, and a bone graft is likely to be needed. Rarely, a midline osteotomy of the mandible with removal of an incisor is used to narrow it anteriorly.



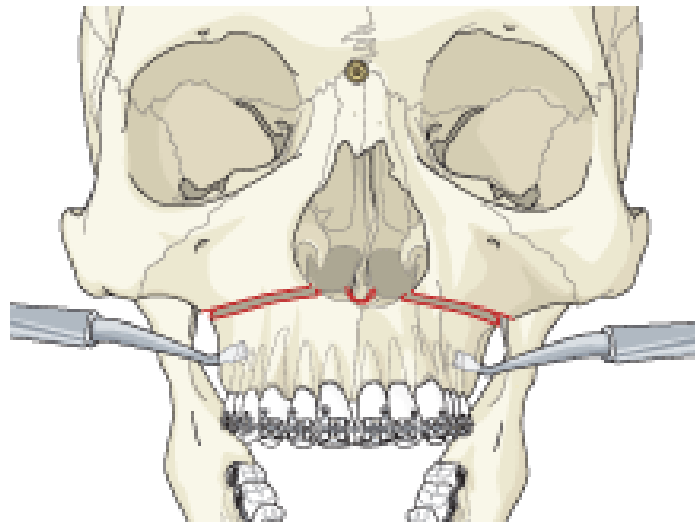
*Fig. 53.* Lower border osteotomy of the mandible.

### ***Maxillary Surgery***

The LeFort I osteotomy with downfracture of the maxilla (fig. 54) dominates contemporary maxillary surgery just as the sagittal split dominates mandibular surgery. It allows the maxilla to be moved up and/or forward with excellent stability. Moving the entire maxilla back is quite difficult because of the structures behind it, but this is not necessary when the upper teeth are protrusive.

A segmental osteotomy, closing the space where a premolar was extracted, allows the anterior teeth to be retracted and posterior teeth to be moved superiorly so that anterior open bite is closed as the mandible rotates upward and forward. Segmental osteotomies also allow the posterior maxilla to be widened or (less frequently) narrowed. Expansion is done with parasagittal osteotomies in the

lateral floor of the nose or medial floor of the sinus that are connected by a transverse cut anteriorly. In a two-piece osteotomy, a midline extension runs forward between the roots of the central incisors; this may or may not be included in a three-piece osteotomy. If constriction is desired, bone is removed at the parasagittal osteotomy sites. In expansion, either bone harvested in the downfracture or bank bone is used to fill the void created by lateral movement of the posterior segments. Orthopedic palatal expansion of the type used in adolescents is not feasible in adults because of the increasing resistance from interdigitated midpalatal and lateral maxillary sutures. Surgically assisted rapid palatal expansion (SARPE), using bone cuts to reduce the resistance followed by expansion of the jackscrew to separate the halves of the maxilla, is another possible treatment approach for adult patients with a narrow maxilla. The original idea of surgically assisted expansion was that cuts in the lateral buttress of the maxilla would decrease resistance to the point that the midpalatal suture could be forced open (i.e., microfractured) in older patients. Although this usually works in patients in their late teens or early twenties, the chance of inadvertent fractures in other areas is a concern, especially for patients in their thirties or older. For SARPE now, surgeons usually make all the cuts needed for a LeFort I osteotomy, omitting only the final step of downfracture. This allows widening of the maxilla against only soft tissue resistance, manipulating the osteotomy sites with what amounts to distraction osteogenesis. If only expansion is desired, this provides a somewhat less invasive approach than segmental osteotomy.



*Fig. 54.* The LeFort I osteotomy with downfracture of the maxilla.

**Dentoalveolar Surgery.** Segments of the dentoalveolar process can be repositioned surgically in all three planes of space, but in this surgery as in other types, there are important limitations:

1. the distance of movement that is possible: in most instances, only a few millimeters.
2. the size of the segment: a three-tooth or larger segment is preferred, a two-tooth segment is acceptable but less predictable, and a one-tooth segment is a problem waiting to occur.

The reason for both limitations is the same. After an osteotomy beneath the bone segment and teeth, the blood supply is the surprisingly good collateral circulation via the facial and lingual mucosa. This has to be preserved to maintain the vitality of the teeth and the integrity of the bone. The further a segment is moved and the smaller it is, the greater the chance of interrupting not only the usual blood supply but also the collateral supply.

## **REFERENCES**

1. Lecture material.
2. Contemporary orthodontics. 5th edition / William R. Proffit [et al.], 2013.
3. Orthodontics. Current Principles and Techniques. 6th edition / Lee W. Graber, Robert L. Vanarsdall, Katherine W. L. Vig, Greg J. Huang, 2016.
4. Orthodontic Treatment of Class III Malocclusion /Peter W. Ngan, Toshio Deguchi, Eugene W. Roberts, 2014 Bentham Science Publishers Ltd.

## **TASKS FOR INDEPENDENT WORK OF STUDENTS:**

### **1. Types of surgical intervention on maxilla:**

- a) Le Fort I;
- b) Le Fort II;
- c) Le Fort III.

### **2. Types of surgical intervention on mandible**

- a) Transoral vertical oblique osteotomy;
- b) Sagittal split osteotomy;
- c) Osteotomy by Le Fort I.

### **3. Indications for orthognathic surgery:**

- a) Severe skeletal forms of malocclusion;
- b) Open bite in primary dentition;
- c) Deep bite in mixed dentition.

### **4. Sequence of orthognathic surgery:**

- a) Pre-Orthodontic treatment – Post-Surgical orthodontic treatment - Surgery - Debonding and retention;

- b) Pre-Orthodontic treatment – Surgery - Post-Surgical orthodontic treatment - Debonding and retention;
- c) Pre-Orthodontic treatment – Surgery - Debonding and retention - Post-Surgical orthodontic treatment.

## **PRACTICAL SESSION 12**

**TOPIC:** Prosthetic treatment method of malocclusion.

**Total time of session:** 6 academic hours.

**Practical questions:**

1. Indications for prosthetics in the temporary occlusion.
2. Indications for prosthetics in mixed dentition.
3. Indications for prosthetics in permanent dentition.
4. Types of prostheses used in pediatric practice.
5. Features of the production of partial dentures in pediatric practice.

**Topic description.** Destruction and premature removal of teeth during the formation of a temporary, mixed and permanent bite is accompanied by morphological and functional disorders of the dentoalveolar system. The aesthetics of the face and the process of digestion suffer. To eliminate these violations, timely and high-quality prosthetics of these defects are necessary.

**Purpose and objectives of the lesson. Students should know:**

- to study the indications for the use of various removable and non-removable orthopedic structures in children with dentition defects;
- to teach students to plan orthopedic care with defects in the dentition and individual teeth in children. Apply different designs of removable and non-removable prosthesis, depending on the age and type of defect

**Requirements to the initial level of knowledge. Student should repeat:**

From course of orthopedic dentistry, it is necessary to know

- stages of making crowns and removable prostheses;
- choice of the method of setting teeth;
- laboratory technique for making pins of pins.

From the course of general orthodontics:

- indications for prosthetics in a temporary, mixed and constant bite.

**Educational grants.** When the crowns of individual teeth are destroyed or when they are lost early in childhood, there are irregularities in the shape of the dentition, bite anomalies and functional disorders. The purpose of the therapeutic method of treatment is to restore the functions of the dentoalveolar system and prevent the occurrence of dentoalveolar anomalies.

Prosthetics are indicated at any age, when tooth crowns are decayed with caries, after they have been damaged as a result of trauma, after an early loss of temporary or permanent teeth, in adentia or anerubic conditions.

Structures prostheses for children should be simple, materials for their manufacture are harmless, hygienic, light, not deficient. Dentures should not impede the growth and formation of dentition and jaw bones. To replace the defects of the teeth, non-removable prostheses are used, to replace the defects of the dentition, removable and non-removable.

Morphological and functional disorders in premature tooth loss.

For the purpose of rational planning of orthopedic care for children, the choice of the prosthesis design in each specific case, and the effectiveness of orthopedic measures, one can apply the scheme of the stages of tooth and dental arches in children. This scheme takes into account the nature of the lesion, the etiological factors that cause the formation of defects in the teeth and dental arches, as well as the design of prostheses recommended for the replacement of defects in different periods of formation of the masticatory apparatus in children. With the destruction and loss of teeth in children there are both morphological and functional disorders.

Morphological disorders:

- 1) uneven growth of jaws,
- 2) dysplasia and formation of the rudiments of permanent teeth,
- 3) intraosseous movement of the rudiments of permanent teeth,
- 4) violation of the timing of eruption of permanent teeth,
- 5) dental alveolar elongation,
- 6) shortening of the dental arches,
- 7) impacted teeth,
- 8) anomalies of the shape of the tooth crowns,
- 9) anomalies of the position of individual teeth,
- 10) formation of a pathological occlusion, a decrease in its height.

Functional disorders:

- 1) the uneven distribution of the chewing pressure,
- 2) lack of physiological stimulation on the toothless sections of the jaws,
- 3) dysfunction of chewing muscles and temporomandibular joint,
- 4) blocking lateral movements of the lower jaw,
- 5) bad habits.

*Table 4*

**Characteristics of the destruction of teeth and dentition and the choice of appropriate orthopedic treatment**

Stages of destruction	Nature of damage	Etiological factors	Recommended construction in the period		
			<i>temporary bite</i>	<i>mixed bite</i>	<i>permanent bite</i>

<b>I</b>	Partial tooth crown defect without damage to the pulp	Uncomplicated caries, enamel hypoplasia, trauma, combined effects of several factors	Seal, thin-walled crown	Tabs, thin-walled and cap-facet crowns	Tabs, thin-walled, plastic crown-facet crowns, ordinary metallic Crowns
<b>II</b>	Significant or complete defect of the tooth crown with damage pulp	Complicated caries, trauma, combined effects of several factors	Thin-walled crown	Tabs, thin-walled crowns, cap-faceted, cap-occlusal Crowns and pin teeth	Tabs, all kinds of crowns, pin teeth
<b>III</b>	Defects of the dentition line extended 1-2 teeth	Complicated caries, trauma, periodontitis, adentia, anerrubia	Fixed spacer, partial removable plate the prosthesis	Bridge One-sided prosthesis a fixation, a sliding bridge, a fixed spacer, a partial removable prosthesis	Bridges with single and bilateral fixation, partial removable dentures, adhesive prostheses
<b>IV</b>	Defects in the dentition of a large extent, complete absence of teeth	Complicated caries, trauma, periodontitis, adentia, anerubia, systemic diseases	Partial and complete removable dentures	Partial and complete removable dentures	Partial and complete removable dentures

### Preparing the oral cavity for prosthetics

Measures to prepare the oral cavity for prosthetics in each period of formation of the dentoalveolar system are different. During the period of temporary bite:

- 1) treatment of teeth affected by caries;
- 2) removal of roots, elimination of pathological foci on the mucosa;
- 3) elimination of extrusion.

When the rudiments of the permanent teeth are deeply buried, basic plates or partial removable prostheses with an overestimation of 1-2 mm in the bite, which during the first 10-12 days provide enhanced physiological irritation, improve metabolic processes and blood supply, are used to eliminate extrusion. There is a trabecular reconstruction of bone tissue. The time of carrying the plate is round the clock.

To eliminate extrusion with superficial deposition of the rudiments of permanent teeth, the prosthesis device should not increase the height of the occlusion in the area of the alveolar processes with extrusion of the teeth and alveolar elongation. Occlusal contacts are established between all pairs of antagonist teeth, the time of using the device is reduced to 6-8 hours per day, the advanced temporary teeth are ground.

With insufficient mineralization of the primordia of the permanent teeth and their superficial location, a prosthetic appliance is used without overstating the occlusion. The time of using the prosthesis is no more than 2-3 hours a day, the extruded teeth are ground.

In the period of mixed bite, in addition to the above measures, it is necessary:

- 1) remove dental deposits from permanent teeth on the non-functioning side, as they can move deeper into the dentogingival groove and cause inflammation of the marginal periodontal;

- 2) eliminate inflammatory processes in the marginal periodontium and proliferation of the mucous membrane, resulting from trauma to the acute edges of absorbable roots;

- 3) eliminate pathological foci in the periodontitis of permanent teeth;

- 4) carry out, if necessary, plastic surgery to deepen the vestibule of the mouth and lengthen the bridle lips.

In the period of constant bite when preparing the oral cavity for prosthetics additionally:

- 1) remove supercomplete teeth;

- 2) perform a resection of the apex of the root;

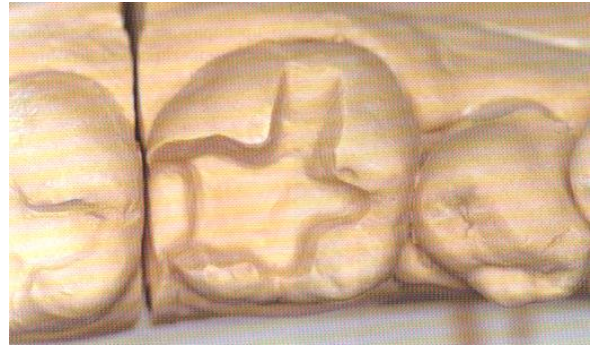
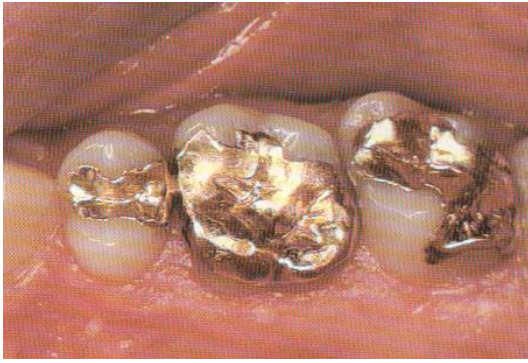
- 3) to carry out, if necessary, alveolotomy or compactosteotomy.

### **Orthopedic care for the stage I of the dentoalveolar system destruction**

(Table 4). For the first stage of damage to the dentoalveolar system, a partial defect in the crowns is present without opening the cavity of the tooth. Defect can be formed as a consequence of caries, enamel hypoplasia, trauma or combined effects of several factors. Replacement of a partial defect of the crown of the tooth with the purpose of restoring its anatomical shape and function at various periods of occlusion formation can be made using a thin-walled metal crown during the period of temporary bite. Prophylactic thin-walled metal crowns made of steel or titanium sleeve cases are widely used in pediatric dentistry.

Such crowns cover teeth to restore anatomical shape in large or multiple cavities, poor fixation of seals in temporary or permanent teeth, traumatized teeth in children, with an unformed root system. Thin-walled metal billets are used to make root protection in the teeth of the teeth, in the cap-faceted design of the crowns, in fixed orthodontic braces. Thin-walled metal crowns have a number of advantages over conventional artificial crowns. First, for the use of thin-walled crowns, mechanical treatment of hard tooth tissues is not required. Secondly, due to the springing properties of steel, a thin-walled crown 8-10 times densely covers the neck of the tooth, which prevents its cementing and the occurrence of cervical caries. Metal thin-walled crowns are made without tooth preparation, so the relief of their chewing surface does not change. As a result, the fissure-tubercular contact with the teeth of the antagonists is preserved.

During the period of mixed bite, temporary and permanent teeth are simultaneously located in the oral cavity. Replacement of partial defects of crowns of temporary teeth is carried out by a seal or thin-walled crown, and defects of permanent teeth are replaced by tabs. The tab (Fig. 55 a, b) allows to completely restore the anatomical shape of the tooth, create contact points with adjacent teeth and antagonists, restore chewing function, achieve a good aesthetic effect. It can be used for a longer period, a seal. For the manufacture of inlays use steel, titanium, plastic, porcelain. The best material for replacing defects in the crowns of the front teeth is porcelain.

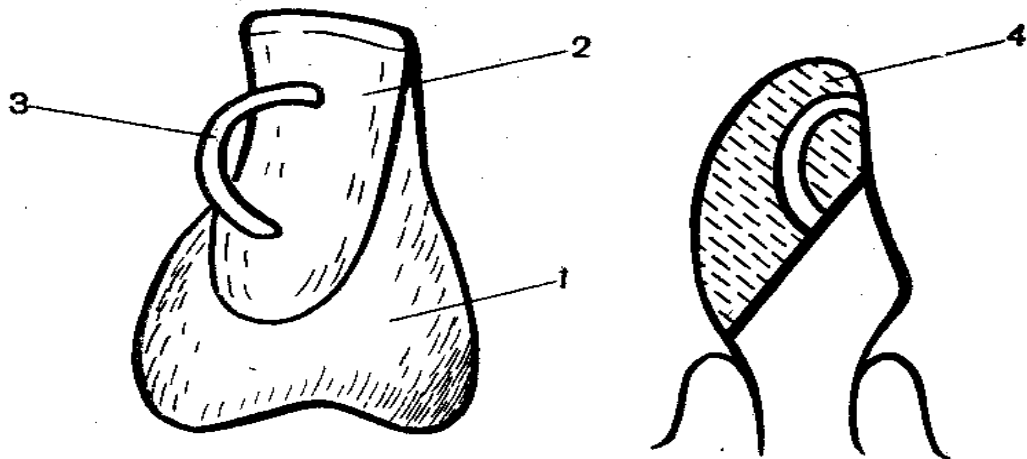


*Fig. 55.* Tabs: a - tabs on the molar and premolars, b - treatment of the tooth cavity

Contraindications to the use of tabs:

- a) biological inferiority of hard tooth tissues
- b) the presence of several cavities in the crown of the tooth.

With the tooth pulp stored, both with the unformed and the formed root, the anatomical shape of the tooth can be restored using a combination cap-facet crown. The use of such a crown is indicated in the fracture of the crown of the tooth or the entire cutting edge, as well as in the absence of half of the crown or its vestibular part. The cap-facet crown consists of three parts: a fixing (in the form of a stamped thin-walled cap); replacement (in the form of cast metal protection with a loop); facing (fig. 56).

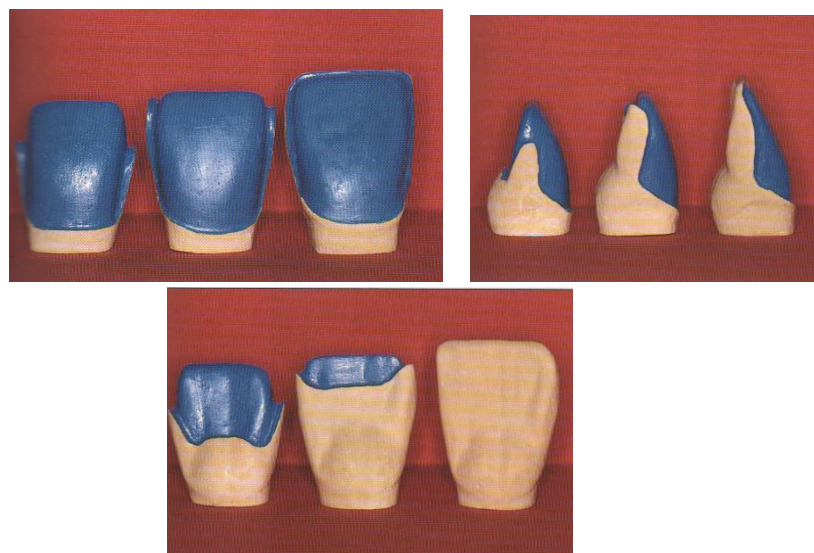


*Fig. 56.* Cap-facet crown: full face and profile

- 1 - a metal cap; 2 - molded protection;
- 3 - fixing loop; 4 - the lining part of the crown

Advantages of a thin-walled cap-facet crown:

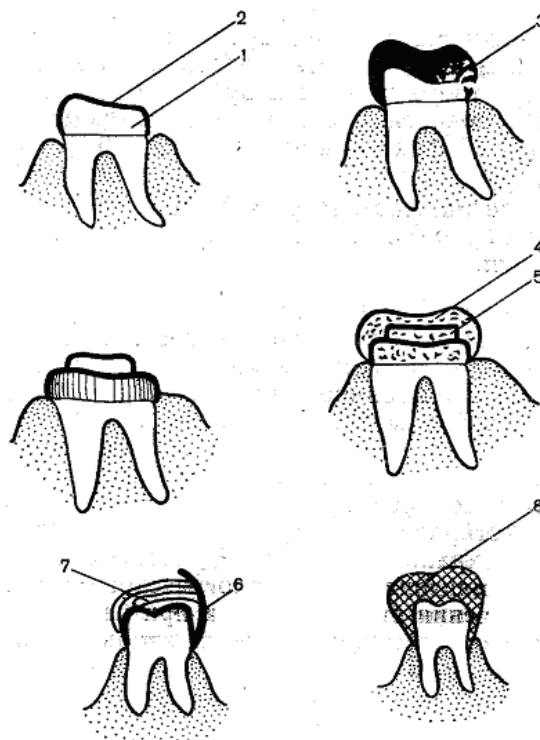
- a) does not require depulcation of the restored tooth,
- b) with the help of the cap, they achieve long and lasting hermeticism, thus ensuring a reliable isolation of the tooth pulp from the harmful effects of external factors,
- c) the cap is easy to attach, its edge ends at the level of the gum,
- d) the height of the missing part of the crown is restored with a fixing loop or cast protection, which ensures the rigidity of the structure,
- e) the mechanical load during the functioning of the masticatory device is transferred to the massive cast part of the crown, which does not spring, so the lining material does not separate from the cap,
- f) the combined cap-faceted crown is strong, completely restores the anatomical shape of the tooth for a long period. It can be used to restore the anatomical shape of the tooth in children, with both closed and uncovered cavities of the tooth, as well as with the unformed root of the tooth. However, currently, plastic or ceramic veneers are preferred (fig. 57).



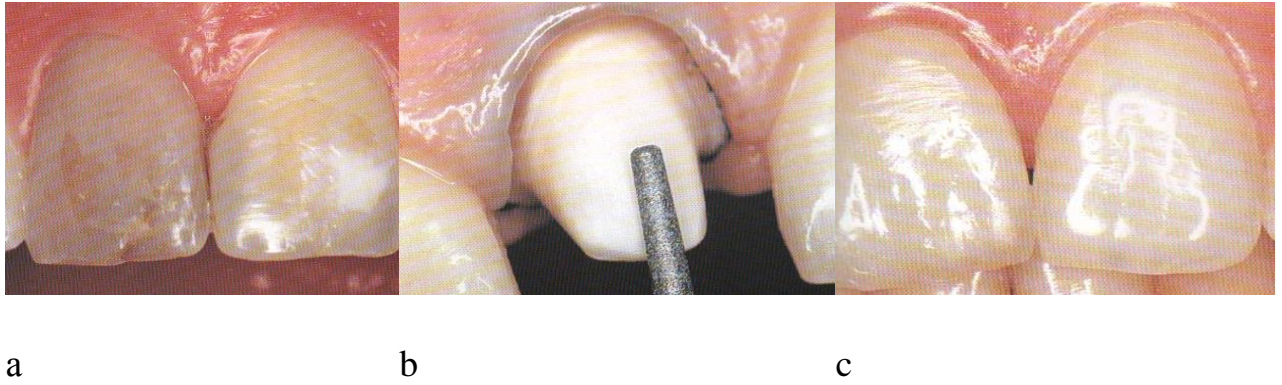
*Fig. 57. Options for restoration of crowns ceramic veneers (wax modeling)*

**Orthopedic care at the stage II of the dentoalveolar system destruction.** The destruction of the tooth-jaw system of the 2nd stage in children is characterized by significant partial or complete defects of the tooth crowns without damage or with damage to the pulp. Defects of the teeth can form as a result of complicated caries, trauma or with the combined effect of various factors (hypoplasia of the enamel, caries, trauma). The tactic of substitution of partial and complete defects of crowns of temporary teeth depends on the condition of the root and the time of their physiological change. With a stable

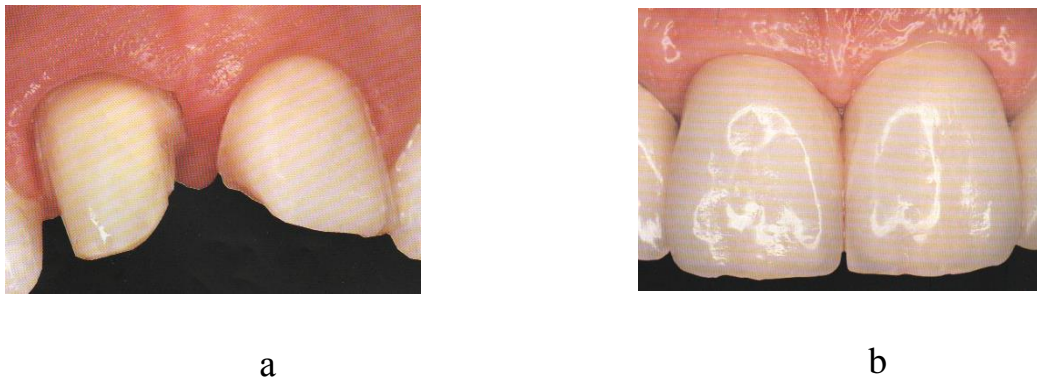
root system (incomplete root formation, fully formed root, insignificant resorption of the apical part of the root), metal crowns can be used to replace partial defects in the tooth crowns with the tooth cavity open. During the period of mixed bite, the full defects of the crowns of permanent teeth can be restored with cultured cap-faceted crowns and pin teeth, with the roots formed, a thin-walled cap is used as a root protection. To replace the full defects of the crowns of permanent lateral teeth, cap-and-pin designs can be used (fig.58). Replacement of the crowns of defects of teeth in a permanent bite at the 2 stage of destruction, use inserts, all kinds of crowns, pin teeth and adhesive structures (fig. 59, 60).



*Fig. 58. Manufacturing options cap-occlusive design of crowns: 1 - tooth stump; 2 - metallic thin-walled cap; 3 - molded restored part of the crown; 4 - the restored plastic part of the crown; 5 - fixing loop; 6 - molded protection; 7 - fixing metal hinges; 8 - facing part of crown*



*Fig. 59. Aesthetic crown: a - tooth color change 11, b - tooth treatment and bleaching of pulp, c - tooth 11 is covered with an aesthetic crown*



*Fig. 60. Aesthetic crown: a - fracture of the corners of the crowns of 11, 21 teeth; b - 11, 21 restored with aesthetic crowns*

To effectively produce pin teeth in childhood, the following conditions are necessary:

- 1) the length of the unsealed part of the root must be at least  $\frac{2}{3}$  of its length;
- 2) the walls of the crown and root should be of sufficient thickness, the cervical part of the tooth crown should protrude 1-2 mm above the level of the gingival margin and be at a sufficient interalveolar distance from the antagonist teeth;
- 3) in periapical tissues there should be no pathological processes.

Indications for the use of pins are complete destruction of the crown of the tooth, as well as poor fixation of large seals.

Absolute contraindications to the manufacture of pins are temporary teeth and teeth with incomplete root formation.

In children's practice, the Ilyina-Markosian pin tooth is most often used, which has a more perfect design, since one of its components is the shock absorber, which improves the sealing of the stump and the fixation of the tooth, especially with horizontal loads. However, this design also does not provide long and complete hermetic activity between the root stump and the crown of the tooth, which has an adverse effect on the stump of the tooth.

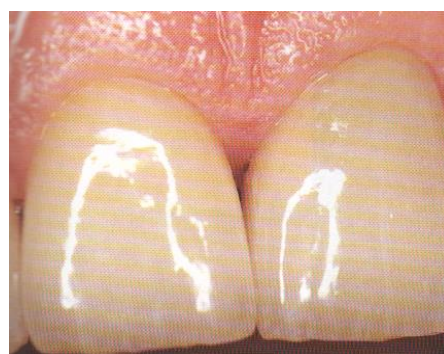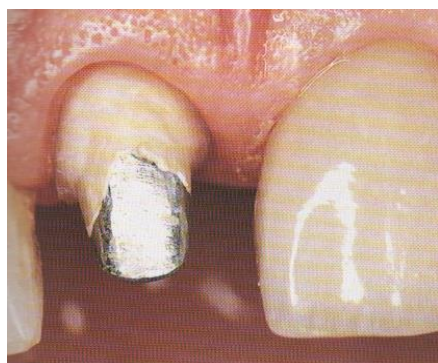The Richmond pin tooth meets all the requirements for pin teeth. However, for the highly effective production of such a pin tooth, a precious metal is needed, which does not allow it to be widely used in children's practice.

In children's practice, a lightweight construction of a pin-tooth is more often used on the basis of a steel thin-walled cap, which acts as a root protection.

The composition includes a thin-walled stamped cap, a pin and a plastic crown part. This design can be made in any dental laboratory.

From the stump of the tooth, an impression is made for making a cap, the pin is made of steel wire with a diameter of 1.2-1.5 mm. On the part of the stem protruding from the root, a loop is bent using the crimp tongs. The root of the pin is conically shaped. A hole is created in the cap and a pin is inserted into the channel. The crown part of the pin is located above the cap. Then the cap is soldered to the pin and a plastic tooth is formed. After processing, the pin plain tooth is fixed in the channel.

If the laboratory is equipped with a casting machine, a cast pin tooth with a cultured metal insert is produced (fig.61). To do this, the tooth canal is filled with softened wax under low pressure and forms a stump of the tooth. Then, the metal pin is inserted into the channel, the wax composition is removed from the stump and cast into the casting. Get a metal cast pin from the metal stump of the tooth. Adjust and fix with cement, and then make an aesthetic crown made of plastic or ceramics. Pin constructions are applicable to the restoration of multi-root crowns, in particular the first permanent molars, which are most often affected by caries.



a

b

*Fig. 61.* Pin constructions: a - intra-root insert (cast pin), b - 11 tooth covered with aesthetic crown

### **Orthopedic care for the stage III of the dentoalveolar system destruction.**

The destruction of the tooth-jaw system of stage III in children is characterized by the presence of a defect in the tooth row of 1-2 teeth, complicated by secondary deformities, such as extrusion and intrusion of teeth.

The basic design in the temporary bite is a removable plate prosthesis. With the help of a prosthesis, the deficit of physiological irritation necessary for the development of the masticatory apparatus, the growth of the jaw bones and the normalization of the process of formation of the bite height is eliminated.

Requirements for removable child prostheses:

1) artificial teeth in the front area are set "on the inflow", because the artificial gum can delay the apposition growth of bone tissue;

2) the upper artificial teeth should overlap the lower front incisors or be located in the edge closure;

3) artificial teeth in the side area set on the artificial gum;

4) the posterior border of the prosthesis passes behind the last molars;

5) fixing of prostheses is carried out with the help of clasps (use of prostheses without clasps leads to their displacement, occurrence of a bad habit to keep them with language and fixation of its wrong position);

6) removable dentures are to be replaced in the period of temporary bite in 0,5 years, in the period of mixed bite - 1 year, in constant bite in patients with incomplete growth - 1,5 years.

In the period of mixed bite, along with a partial removable prosthesis, a bridge with one-sided fixation, a sliding bridge and a non-removable spacer are also used.

In the period of permanent bite in non-growing patients, bridges with bilateral fixation and adhesive prostheses can be used. Often, children already in the period of temporary bite, there are combined lesions of the dentoalveolar system of the 1-st, 2-nd and 3-rd stages, in connection with which there is a need for complex orthopedic therapy.

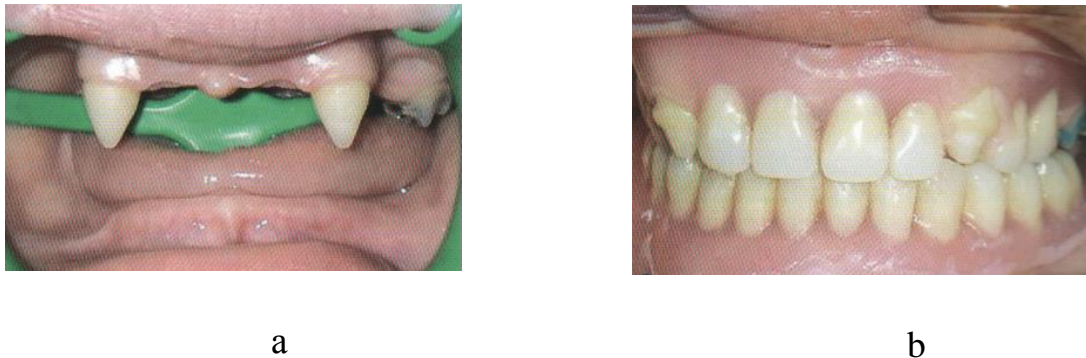### **Orthopedic care in the fourth stage of the dentoalveolar system destruction.**

Particular difficulty is the provision of orthopedic care for children with multiple or complete lack of teeth. Such children often have genetically caused systemic diseases: Krista-Siemens, Papion-Lefevra, reticulohistocytosis, dysfunction of the whole chewing apparatus, aesthetic appearance is violated due to a significant decrease in the occlusion and lower third of the face (fig. 62). In such cases, the range of structures used to replace defects in the dentition of a

large extent is greatly expanded, and an individual approach to the design of the prosthesis or prosthesis apparatus is necessary.

In children with the Stanton-Capdepon syndrome, a severe form of a deep, declining bite appears on the background of abnormal abrasion of the teeth. Therefore, such children need to restructure myostatic reflexes using a plastic removable cap. The term of using the removable tray is 2-3 months.

On the worn teeth, thin-walled crowns are made and. The caps are fixed to the cement and partial or complete removable dentures are installed. To obtain impressions, use individual trays.



*Fig. 62. Criste-Siemens, Touraine syndrome: a - before prosthetics,  
b - after prosthetics*

### **REFERENCES**

1. Contemporary orthodontics / William R. Proffit [et al.] third edition 2010.
2. Diagnosis of the Orthodontic Patient / F. McDonald; J. Ireland 280 p.,1998.
3. Orthodontics. Current principles and techniques /5<sup>th</sup> edition A. Xubair, T.Grabner, R.Vanarsdal , K.Vig .

### **TASKS FOR INDEPENDENT WORK OF STUDENTS (TESTS):**

#### **1. Methods of setting the teeth in the anterior part of partial denture:**

- a) on the artificial gum;
- b) without artificial gum.

#### **2. Kid's dentures have to be replaced:**

- a) every 6 months;
- b) every year;

c) after two or three years.

**3. Spacer interdental intended:**

a) to restore dentition defect;

b) place control for dentition eruption of permanent teeth in the future.

Учебное издание

**Токаревич** Игорь Владиславович  
**Сакадынец** Александр Олегович  
**Коваленко** Ольга Леонидовна и др.

# **ОБЩАЯ ОРТОДОНТИЯ** **GENERAL ORTHODONTICS**

Учебно-методическое пособие  
На английском языке

Ответственный за выпуск И.В. Токаревич  
Переводчики А.О. Сакадынец, О.Л. Коваленко, А.П. Полещук,  
С.А. Ушакова, А.С. Хомич

Подписано в печать 30.12.19 Формат 60×84/16. Бумага писчая «Хероx office».  
Ризография. Гарнитура «Times».  
Усл. печ. л. 4,88. Уч.-изд. л. 4,46 Тираж 150 экз. Заказ 642  
Издатель и полиграфическое исполнение: учреждение образования  
«Белорусский государственный медицинский университет».  
Свидетельство о государственной регистрации издателя, изготовителя,  
распространителя печатных изданий № 1/178 по 18.02.2014  
ул. Ленинградская, 6, 220006, Минск