



**Belarusian State Medical University,
Pediatric surgical centre,
Republican scientific and practical centre
"Mother and Child"**

Our experience in thoracoscopic treatment of congenital diaphragmatic hernia in newborns

**Aliaksandr Svirsky, Vasily Averin, Aliaksandr Mahlin, Aksana Svirskaya, Egor Alesin
Gdansk 18-20.2014**

Background and aims.

The treatment of newborns with congenital diaphragmatic hernia (CDH) is still actual problem. Changing management tactics had led to an improvement in results last decade. The mini-invasive surgical procedure was developed and introduced in clinic adding new abilities.

The goal is to determine the effectiveness of thoracoscopy in treatment of CDH in newborns.

Methods and Materials.

The retrospective analysis of treatment of 127 infants with CDH during the period from 1993 to 2013 in Pediatric Surgery Center of Minsk, Belarus was conducted. From 1993 to 2006, the newborns were operated on 1-2 admission day. Traditional methods - laparotomy and thoracotomy applied in 59 of 65 children in this group, 16 patients died. Two patients were operated after 1 month age and excluded from investigation. Postoperative lethality was 27.1%, the overall mortality rate - 30.7%. Postoperative complications have demanded 18 (30.5%) reoperations in 13 patients, including 4 hernias relapse.

From January 2007 operation are produced only in children with stable condition on the 6-8 day of life. The use of HFOV by VIASYS is method of stabilization of the newborn, in addition to other therapeutic activities.

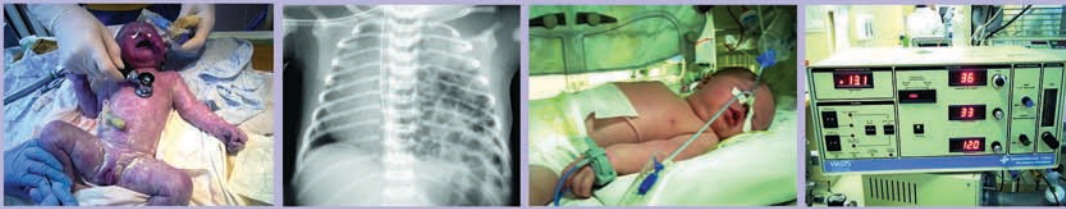

Fig.1-4 Assessment and stabilization the clinical condition of newborn with CDH

The main hernia repair operative method from December 2009 is thoracoscopic plastic of diaphragm.

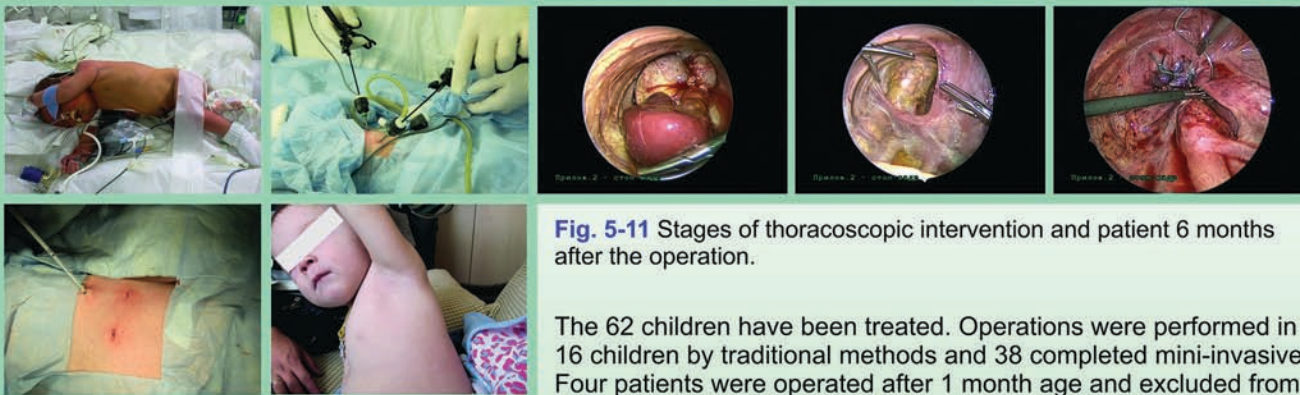

Fig. 5-11 Stages of thoracoscopic intervention and patient 6 months after the operation.

The 62 children have been treated. Operations were performed in 54 children: 16 children by traditional methods and 38 completed mini-invasive intervention. Four patients were operated after 1 month age and excluded from investigation.

Results.

Four patients (7.4%) died postoperatively and overall mortality amounted to 12.9%. Reoperations took place in 10 patients (18.6%), 5 children have recurrent hernia after thoracoscopic plastic. Four of them returned to clinic in a few months after discharge. One child relapse marked twice in 6 months. All children repeatedly operated with thoracoscopy, in four cases patches were applied.

No complications were revealed in early postoperative period in patients with hernia relapse repair.

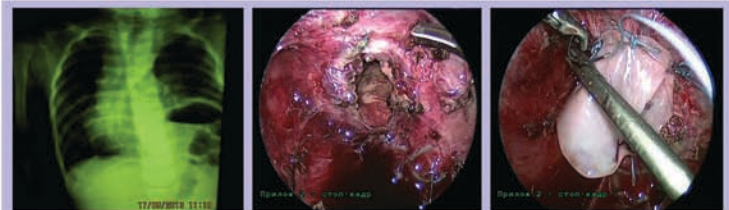


Fig 12-14 The hernia relapse and thoracoscopic plastic of diaphragm with patch

Tab.1 The results of treatment in different groups

Sign	Comparison group (n=65)	The core group (n=62)
	n (%)	n (%)
Excluded patients	2 (3.07%)	4 (6.4%)
Operation treatment	59	54(16/38*)
Preoperative lethality	4 (6.1%)	4 (6.4%)
Postoperative lethality	12 (27.1%)	4 (7.4%)
Overall mortality rate	16 (30.7%)	8 (12.9%)
Postoperative complications	18 (30.5%)	10 (18.6%)
(including hernia relapse)	4 (6.7%)	5 (9.2%)

* traditional operations

** thoracoscopic plastic of diaphragm

Conclusion:

Thoracoscopic repair for CDH is feasible and safe. Minimal trauma, good cosmetic results, and rapid recovery are all important advantages of this method. However, the further long term results investigation are necessary for an objective assessment of the application of thoracoscopy in treatment of congenital diaphragmatic hernia in newborns.

References:

1. Bagolan P, Casaccia G, Crescenzi F, et al. Impact of a current treatment protocol on outcome of high-risk congenital diaphragmatic hernia. J Pediatr Surg 2004;39:313-8.
2. Bysiek A, Zejac A, Budzyska J, et al. Evolution of diaphragmatic hernia management in the years 1991-2002. Eur J Pediatr Surg 2005;15:17-21.
3. Taskin M, Zengin K, Unal E, et al. Laparoscopic repair of congenital diaphragmatic hernias. Surg Endosc 2002;16(5):869.
4. Shah AV, Shah AA. Laparoscopic approach to surgical management of congenital diaphragmatic hernia in the newborn. J Pediatr Surg 2002;37:548-50.
5. Becmeur F, Jamali RR, Moog R, et al. Thoracoscopic treatment for delayed presentation of congenital diaphragmatic hernia in the infant. Surg Endosc 2001;15:1163-6.
6. Arca MJ, Barnhart DC, Lelli JL, et al. Early experience with minimally invasive repair of congenital diaphragmatic hernia: results and lessons learned. J Pediatr Surg 2003;38:1563-8.



Organ-preserving spleen surgery in children.

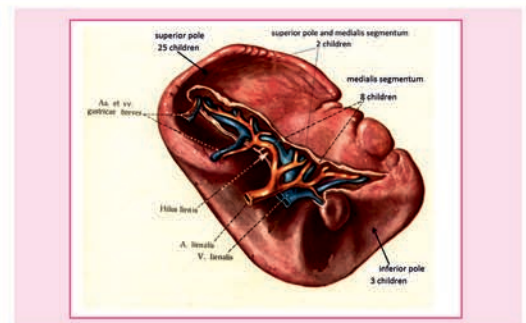
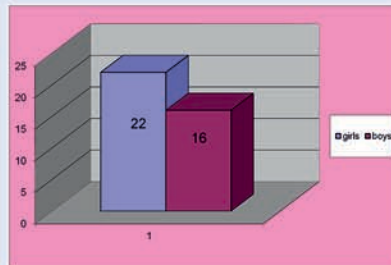
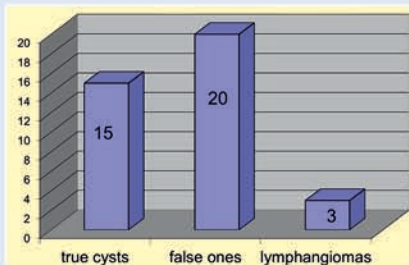
Vasily Averin, Aliaksandr Svirsky, Aliaksandr Mahlin, Nikolai Averin
Belarusian State Medical University,
the Pediatric surgical Centre, Minsk, Republic of Belarus.

Gdansk 18-20.2014

Non-parasitic cysts and benign tumors in spleen were disposed

35 children with non-parasitic cysts and 3 patients with lymphangiomas of spleen have been treated in the Center of Pediatric Surgery from 2001 till 2013

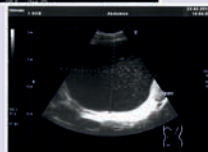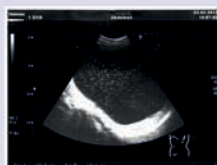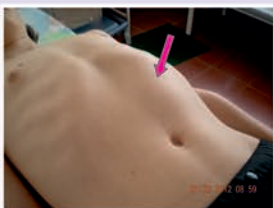- The age of 22 girls and 16 boys was from 7 till 17 years (average 11,8).
- True cysts were revealed in 15 cases, false cysts - in 20, and 3 patient had a lymphangioma.



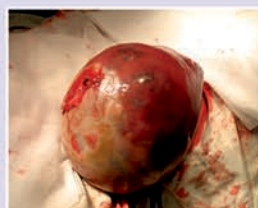All children had been operated

- **29 laparoscopies:**
 - cyst enucleation – 1
 - resection of the cysts walls till the spleen tissue bodes – 16
 - spleen pole resection with the cyst – 12
- **9 laparotomies:**
 - cyst enucleation - 2
 - spleen pole resection with the cyst – 5
 - upper and middle segments resection with cyst - 2

Abdominal asymmetry



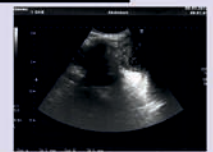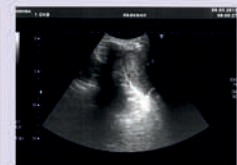Diagnostic US lien's cysts



non-parasitic cyst during oblique laparotomy approach



spleen pole resection with cyst



Diagnostic US lien 3 weeks later after operation



Conclusion :

- Spleen cysts are usually asymptomatic and represents themselves sporadic US-study (81,5% - in our clinic)
- Now making the diagnosis of spleen cysts is quite simple
- Organ – preserving operations in patients with in spleen cyst treatment are operations of choice
- Laparoscopy surgery in such cases is preferable